



# Presentation is key to diagnosing salivary gland disorders

Initial signs and symptoms offer the best guide to next steps in assessment, testing, and treatment, plus any needed referral or multidisciplinary care.

**Shankar Haran, MBBS;**  
**Saniya Kazi, MBBS, FRACP;**  
**Saliya Caldera, MBBS, BSc,**  
**FRCS (ORL-HNS)**

Departments of Otolaryngology  
and Paediatrics, Townsville  
Hospital, Queensland, Australia

[Shankar.haran01@gmail.com](mailto:Shankar.haran01@gmail.com)

*The authors reported no potential conflict of interest relevant to this article.*

## **PRACTICE RECOMMENDATIONS**

› Use ultrasonography for initial imaging of a salivary gland. **(A)**

› Refer patients with the following findings for further specialty evaluation: abscess, inflammation unresponsive to medical care, recurrent or chronic symptoms, suspected neoplasm (for excision), and suspected sialolithiasis. **(A)**

### Strength of recommendation (SOR)

- (A)** Good-quality patient-oriented evidence
- (B)** Inconsistent or limited-quality patient-oriented evidence
- (C)** Consensus, usual practice, opinion, disease-oriented evidence, case series

**M**aking a diagnosis of a salivary gland disorder can be difficult. Common presentations, such as a painful or swollen gland, can be caused by numerous disorders of strikingly variable severity and consequences, including inflammatory, infectious, and neoplastic conditions, for which treatment can differ significantly, and referral for specialty care is sometimes necessary.

Yet it is the patient's presentation that can aid you in making the diagnosis that will guide management. Consider that acute symptoms often result from infection, for example, and chronic or recurrent symptoms are caused more often by obstructive or nonobstructive inflammatory conditions and neoplasms. Diagnosis of an apparent neoplasm, prompted by clinical findings, is made using imaging and fine-needle aspiration (FNA) biopsy. Acute infection usually resolves with antibiotics and supportive management; calculi that cause persistent symptoms warrant referral for consideration of stone or gland removal; and malignant neoplasms usually require excision as well as neck dissection and chemotherapy or radiotherapy, or both—calling for multidisciplinary care.

In this article, we clarify what can be an imprecise and perplexing path from the presentation to diagnosis to treatment of disorders of the salivary glands. To begin, see “Geography of the salivary glands,” on page E3, for an overview of the location, structure, and corresponding ducts of the component salivary glands (parotid, submandibular, sublingual, and minor glands).

## **Presentation helps establish the differential Dx**

### **Ask: Are the glands swollen?**

Painless salivary gland swelling has a variety of causes, including neoplasm, sialadenosis, and the eating disorders bulimia and anorexia nervosa. There is significant overlap of presentations among those causes (**FIGURE**). Pain accompanying swelling is uncommon but not unheard of.

CONTINUED

**➤**  
**Ultrasonography is an excellent initial imaging choice for investigating a possible salivary gland tumor.**

■ **Neoplasms.** Tumors of the salivary gland are relatively uncommon, constituting approximately 2% of head and neck neoplasms; most (80%) occur in the parotid gland, and most of those are benign.<sup>1</sup> Although benign and malignant salivary gland neoplasms do not usually present with pain, pain can be associated with a neoplasm secondary to suppuration, hemorrhage into a mass, or infiltration of a malignancy into adjacent tissue.

*Benign tumors.* The majority of benign tumors are pleomorphic adenomas of the parotid, accounting for approximately 60% of salivary gland neoplasms.<sup>1,2</sup> Tumors localized to the submandibular gland are often (in 50% of cases) malignant, however.<sup>3</sup>

Benign tumors are typically slow-growing and, generally, painless. On examination, they are well-circumscribed, mobile, and nontender. Patients presenting late with a large tumor might, however, experience pain secondary to stretching of the parotid capsule or compression of local structures.

Ultrasonography (US) is an excellent initial imaging choice for investigating a possible salivary gland tumor; US is combined with FNA, which is safe and highly reliable for differentiating neoplastic and non-neoplastic disorders.<sup>4</sup> (Avoid open biopsy of a neoplasm because of the risk of tumor spillage.) In patients with suspected neoplasm, contrast-enhanced computed tomography (CT) or magnetic resonance imaging (MRI) should also be performed, because both modalities allow delineation of the tumor mass and demonstration of any infiltration of surrounding structures.

Treatment of benign neoplasms involves complete excision because, with some tumors, particularly pleomorphic adenomas, there is risk of malignant transformation over time. Superficial parotidectomy is the most common procedure, because most benign tumors occur in the superficial lobe of the parotid gland. Delicate dissection of the facial nerve is integral to the operation, although temporary facial nerve palsy will still occur in 5% to 10% of patients undergoing superficial parotidectomy for a benign tumor, with permanent injury occurring in fewer than 1%.<sup>5</sup>

*Malignancy.* Features of a tumor that raise concern of malignancy include<sup>6</sup>:

- rapid growth
- pain
- tethering to underlying structures or overlying skin
- firm mass
- associated cervical lymphadenopathy
- facial-nerve palsy.

The workup of a malignant tumor is the same as it is for a benign neoplasm: US-guided FNA, essential for diagnosis, and contrast-enhanced CT or MRI to delineate the tumor.

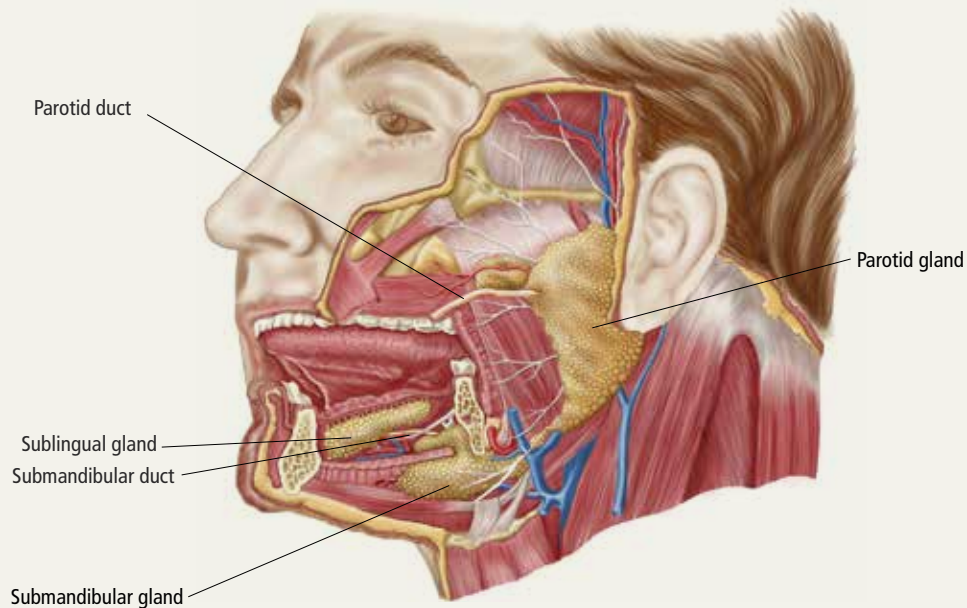
Malignant salivary gland neoplasms usually require excision as well as neck dissection and chemotherapy or radiotherapy, or both, necessitating a multidisciplinary approach. Also, there is potential for squamous-cell carcinoma and melanoma of the head to metastasize to salivary gland lymph nodes; it is important, therefore, to examine for, and elicit any history of, cutaneous malignancy of the scalp or face.

■ **Sialadenosis** presents with asymptomatic bilateral hypertrophy of the salivary glands—more commonly the parotids and rarely the submandibular glands. Swelling is persistent, symmetrical, painless, and of normal tone on palpation.

Causes of sialadenosis include alcoholism and, less commonly, diabetes mellitus and malnutrition; some cases are idiopathic. An autonomic neuropathy, causing excessive salivary acinar protein synthesis or failure of adequate secretion, or both, is common to alcoholism, diabetes, and malnutrition.<sup>7</sup> Subsequent engorgement of acinar cells leads to clinical parotid hypertrophy.

Diagnosis is based on history and examination, as well as on the findings of US or CT, which will reveal bilateral gland enlargement and increased density. The glands appear dense because adipose cells are displaced by acinar cell hypertrophy; however, end-stage changes can result in the opposite appearance: a lucent enlargement caused by fatty infiltration.<sup>2</sup> FNA is unnecessary, unless there is suspicion of neoplasm, as there would be in patients with asymmetrical parotid enlargement, pain, lymph node enlargement, or facial-nerve in-

## Geography of the salivary glands



The salivary glands comprise the major paired parotid, submandibular, and sublingual glands, as well as minor salivary glands that line the oropharyngeal mucosa. Secretion of saliva is modulated by both autonomic and humoral factors.

- **The parotid gland** sits between the mastoid process, the ramus of the mandible, and the styloid process, extending from the external auditory meatus superiorly to below the angle of the mandible and into the neck inferiorly. The gland is surrounded by a tough capsule. Embedded within the gland is the facial nerve, which divides into its 5 branches within the substance of the gland. The parotid (Stensen's) duct passes anteriorly before turning medially to pierce the buccinator muscle, opening onto the mucous membrane of the cheek opposite the second upper molar.
- **The submandibular gland** comprises (1) a large superficial part that fills the space between the mandible and the floor of the mouth and (2) a small deep part that wraps around the posterior border of the mylohyoid muscle. The submandibular (Wharton's) duct runs anteriorly to open onto the floor of the mouth, alongside the frenulum.
- **The sublingual gland**, the smallest of the major salivary glands, lies anteriorly in the floor of the mouth, with many small ducts opening either into the submandibular duct or directly into the mouth.
- **Basic secretory units of salivary glands** are clusters of cells, each called an acinus. These cells secrete a fluid that contains water, electrolytes, mucous, and enzymes, all of which flow out of the acini into collecting ducts. The saliva produced by the parotid is mainly serous; by the submandibular gland, mixed; and by the sublingual and minor salivary glands, mucoid.

IMAGE: ©STOCKTREKIMAGES/SCIENCESOURCE

volvement. In patients with sialadenosis, in contrast, acinar cell hypertrophy alone will be present.

Treatment of sialadenosis is best aimed at rectifying the underlying medical condition, which might, over time, lead to some reduction in the size of the gland. There is no specific effective therapy for elimination of glandular swelling.

■ **Bulimia and anorexia nervosa.** Bulimia nervosa, the induction of vomiting after binge eating, can be associated with bilateral or occasionally unilateral parotid swelling. Anorexia, a form of self-starvation, can occur in association with bulimia, with patients also presenting with parotid swelling. Associated parotid swelling is similar to what is seen in sialadenosis: painless, persistent, and of nonpathologic consistency.

CONTINUED

➤  
**For a submandibular duct stone, bimanual palpation might reveal its position if it's located distally in the floor of the mouth; a proximal stone might not be palpable.**

The pathophysiology of bulimia- and anorexia-associated parotid-gland swelling is identical to what is seen in sialadenitis: dysregulation of acinar cell sympathetic nerve supply that leads to enlargement of individual parenchymal cells.<sup>8</sup> Contrast-enhanced CT can reveal increased vascularity associated with active bulimia. FNA and CT, however, are required only in patients in whom the diagnosis is not clear and when neoplasm is suspected.

Treatment includes correcting electrolyte abnormalities and, more importantly, addressing underlying emotional issues to stop purging episodes. Psychiatric input and social support are invaluable. Parotid gland swelling generally improves with cessation of vomiting episodes.

**Ask: Is the patient in pain?**

Causes of salivary gland pain include sialolithiasis, sialadenitis, and recurrent parotitis of childhood. Pain occurs secondary to stretching of the fibrous capsule in which the parotid or submandibular gland is surrounded, compression of pain fibers by an expanding mass, or infiltration of nerves by neoplasia.

■ **Sialolithiasis.** Sialolithiasis, or salivary stones, are primarily calcium carbonate concentrations within the salivary ductal system. More than 80% occur in the submandibular gland or duct<sup>9</sup> as a result of production of mixed mucoid and serous saliva and a tortuous duct path.

Patients usually present with a history of intermittent swelling and pain of the involved gland associated with eating. Increased production of saliva during meals, which then passes through a partially obstructed salivary duct, leads to salivary retention and glandular swelling. Thus, a recurring pattern can develop, with varying periods of remission,<sup>7</sup> eventually leading to an acute suppurative process or sialadenitis (described below). Chronic salivary disease can also be caused by stricture of a duct or, rarely, external compression by a tumor mass.

Examination often reveals an enlarged and often tender gland; conversely, chronic disease can lead to gland atrophy. Usually, only minimal saliva is able to be expressed from an obstructed duct. For a submandibu-

lar duct stone, bimanual palpation might reveal its position if it is located distally in the floor of the mouth; a proximal stone might not be palpable.

Although US is operator-dependent, it is the imaging modality of choice for identifying sialolithiasis<sup>10</sup> because it can identify gland architecture, duct dilation, and both radiolucent and radiopaque stones. For patients in whom US findings are normal despite a convincing clinical presentation of sialolithiasis, CT should be performed because small stones can be missed on US.<sup>11</sup>

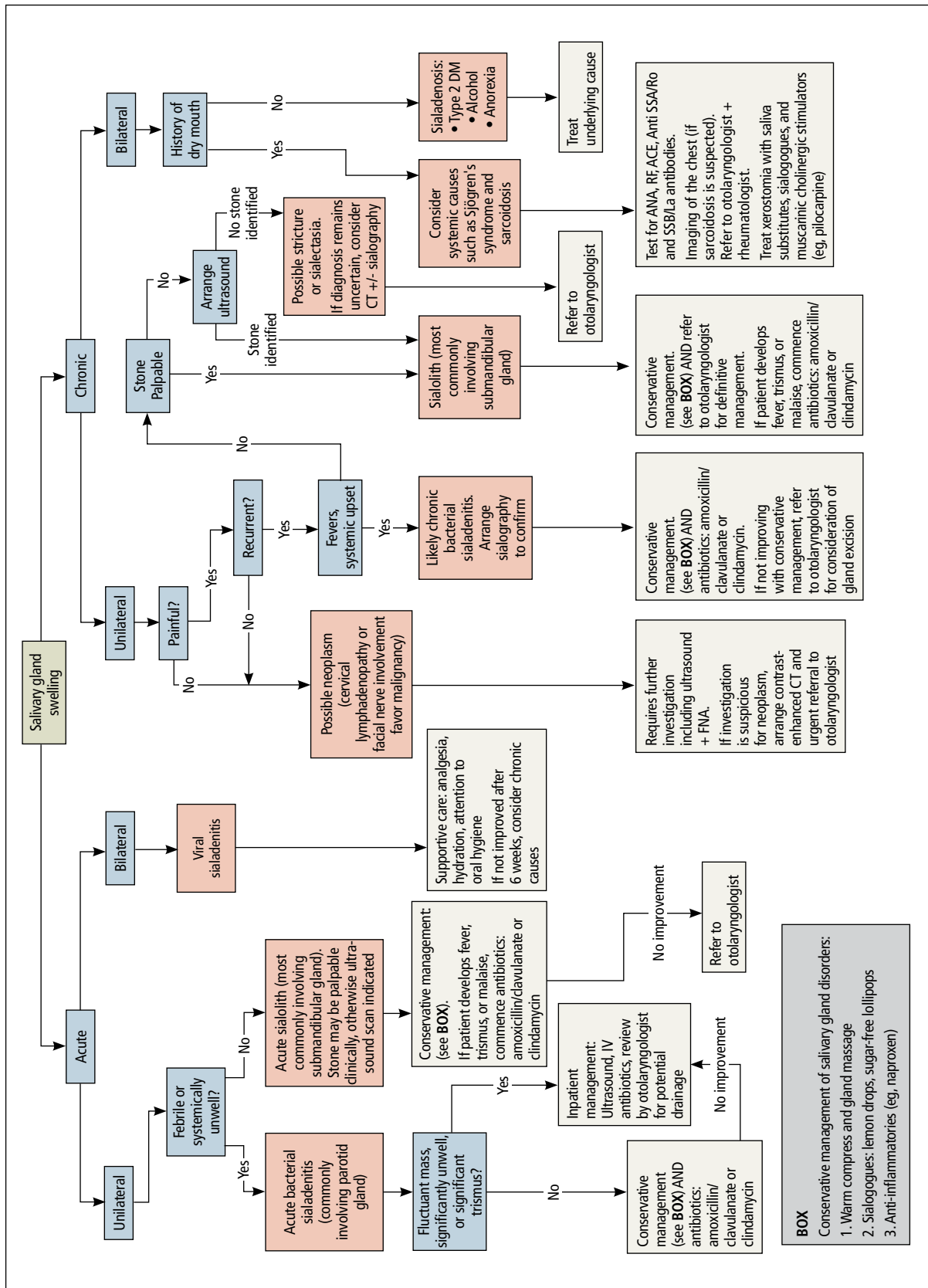
Supportive measures for sialolithiasis are listed in the **TABLE**. Reserve antibiotics for patients who have signs or symptoms of infection, including pyrexia, trismus, and malaise. A beta-lactam antibiotic, such as amoxicillin-clavulanate, 875 mg orally bid, or a cephalosporin, such as cephalexin, 500 mg orally qid, are appropriate first-line options. Clindamycin, 300 mg orally tid, or metronidazole, 500 mg orally tid, are acceptable alternatives. When signs or symptoms are persistent or recurrent, refer the patient for a surgical opinion.

Stones located in the floor of the mouth are usually excised through an intraoral approach. In the past, gland excision was advocated when a sialolith was found more proximally within the gland parenchyma. More recently, however, sialendoscopy, involving insertion of a small, semirigid endoscope into the salivary duct, has been shown safe and effective for removing a stone; successful removal, in as many as 80% of cases, increases to 90% when performed using a minimally invasive surgical technique.<sup>12</sup> Although sialendoscopy is effective, the technique cannot always treat the underlying abnormality of the salivary gland; gland excision is therefore warranted in some cases.

Last, extracorporeal shock wave therapy is aimed at fragmenting salivary stones before retrieval. Results are variable, however, and treatment should be guided by an otolaryngologist.<sup>13,14</sup>

■ **Sialadenitis (bacterial and viral infection).** Acute suppurative sialadenitis occurs secondary to retrograde ductal bacterial infection. The parotid gland is most frequently involved,<sup>15</sup> although submandibular sialadeni-

**FIGURE**  
A swollen salivary gland: Where will the workup take you?



ACE, angiotensin-converting enzyme; ANA, antinuclear antibody; CT, computed tomography; DM, diabetes mellitus; FNA, fine-needle aspiration; RF, rheumatoid factor; SSA/Ro, Sjögren's-syndrome related antigen A; SSB/La, Sjögren's-syndrome type B antigen/Lupus La protein.

**TABLE**  
**Checklist of supportive measures  
 for sialolithiasis**

• Hydration
• Gland massage ("milk" the gland toward the duct papillae)
• Warm compresses (heat a damp towel, squeeze out excess water, and place it over the gland)
• Sialagogues (eg, chewing gum, lemon drops, sugar-free lollipops)
• Nonsteroidal anti-inflammatory drugs (eg, ibuprofen, diclofenac, naproxen)
• Good oral hygiene (brush and floss teeth, use a chlorhexidine 0.2% mouthwash at least twice a day).

**>**  
**In sialolithiasis, reserve antibiotics for patients who have signs or symptoms of infection, including pyrexia, trismus, and malaise.**

tis is not uncommon. Patients usually present with sudden-onset unilateral, painful swelling.

Pathophysiology involves dehydration or decreased oral intake leading to salivary stasis and subsequent bacterial migration into the gland. Medically debilitated and postoperative patients are therefore at greater risk; so are patients with diabetes mellitus, poor oral hygiene, Sjögren's syndrome, hypothyroidism, or renal failure.<sup>16</sup> Certain medications, including anticholinergics, can also predispose to hyposalivation.<sup>17</sup>

(As discussed, sialolithiasis and stricture of salivary ducts can also cause acute bacterial infection; in such cases, however, the typical presentation is one of chronic or recurrent infection.)

Examination might reveal an exquisitely tender, indurated, and inflamed gland; pus can often be expressed from the respective intraoral orifice. Any expressed pus should be sent for culture to guide antibiotic therapy.

Treatment should focus on hydration, oral hygiene, and antibiotics, while reversing or minimizing any underlying contributing medical condition. Warm compresses applied to the involved gland, massage, and sialagogues, such as lemon drops or sugar-free lollipops, can stimulate salivary flow and prevent stasis.

More than 80% of infections are caused by *Staphylococcus aureus*<sup>17</sup>; anaerobic and mixed infections have also been recognized. A beta-lactam penicillin, such as amoxicillin-clavulanate, is the antibiotic of choice. A patient who is systemically unwell should be treated as an inpatient with nafcillin and metronidazole. Methicillin-resistant *S aureus* must also be considered in patients with comorbid disease, such

as diabetes mellitus or intravenous drug use, or in patients residing in an area of substantial incidence of methicillin-resistant *S aureus*. In those cases, substitute vancomycin or linezolid for nafcillin.<sup>18</sup>

Less commonly, abscess can form, with the patient presenting as systemically unwell with a fluctuant mass. If the diagnosis is unclear or the patient does not improve, abscess can be confirmed by US. Expedient surgical review and inpatient admission can then be arranged.

Unlike bacterial sialadenitis, causes of viral sialadenitis are often bilateral. Mumps (a paramyxovirus) is the most common viral cause, affecting primarily children < 15 years.<sup>19</sup> The parotid glands are most often involved, with inflammation and edema causing significant pain because of increasing intraparotid pressure as expansion of the gland is limited by its tense fibrous capsule. Complications of mumps include orchitis, meningitis, pancreatitis, and oophoritis.

Mumps is highly contagious; it is spread through contact with airborne saliva droplets, with viral entry through the nose or mouth, followed by proliferation in the salivary glands or on surface epithelium of the respiratory tract.<sup>7</sup> Diagnosis is confirmed by viral serology. A positive test of serum immunoglobulin M confirms the diagnosis, but this test should not be performed until 3 days after onset of symptoms because a false-negative result is otherwise possible.<sup>20</sup> Immunoglobulin G serologic testing can further aid diagnosis; the titer is measured approximately 4 days after onset of symptoms and again 2 to 3 weeks later. A 4-fold rise in titer confirms mumps.

Other viral infections that can cause sialadenitis include Epstein-Barr virus, cytomegalovirus, human immunodeficiency virus, coxsackievirus, and influenza. Treatment is supportive: analgesia, hydration, oral hygiene, and rest. Inflammation might take weeks to resolve, but expect complete resolution. For a patient who has significant trismus, poor oral intake, or a potentially threatened airway, inpatient care should be provided.

■ **Recurrent parotitis of childhood** is an inflammatory condition that usually affects one, but at times both, parotid glands. It is characterized by episodes of painful swell-

ing. Incidence peaks at 3 to 6 years of age.<sup>7</sup> Episodes can be frequent, occurring 1 to 5 times a year and lasting 3 to 7 days—sometimes longer—and usually resolving without treatment.

The precise etiology of recurrent parotitis of childhood is unclear; possibly, saliva aggregates to form obstructive mucous plugs, thus causing stasis and swelling of the gland. As pressure builds, spontaneous plug extrusion occurs and symptoms resolve, provided infection is not a factor. US demonstrates multiple round, hypochoic areas consistent with duct dilation, and surrounding infiltration by lymphocytes.<sup>1</sup>

Supportive care—adequate hydration, gland massage, warm compresses, and sialogogues—are mainstays of treatment. Fever and malaise warrant treatment with oral antibiotics. Sialadenoscopy, which can be considered in children with frequent episodes, can decrease the frequency and severity of episodes.<sup>21</sup> The condition usually resolves spontaneously at puberty.

#### Ask: Does the patient have dry mouth?

In-depth review of xerostomia is beyond the scope of this article. Causes include Sjögren's syndrome, immunoglobulin G4-related sialadenitis, sarcoidosis, radiation therapy, diabetes, chronic infection, and medications—in particular those with anticholinergic effects.

Treatment of xerostomia includes saliva substitutes, sialagogues, and, for oral candidiasis, antifungals. Muscarinic cholinergic stimulators, such as pilocarpine, 5 mg qid have been used with some success<sup>22</sup>; patients should be advised of potential adverse effects with these agents, including sweating, urinary frequency, flushing, and chills. **JFP**

#### CORRESPONDENCE

Shankar Haran, MBBS, ENT Department, Townsville Hospital, 100 Angus Smith Dr, Douglas, Queensland, Australia 4814; Shankar.haran01@gmail.com.

#### References

- de Oliveira FA, Duarte EC, Taveira CT, et al. Salivary gland tumor: a review of 599 cases in a Brazilian population. *Head Neck Pathol.* 2009;3:271-275.
- Spiro RH. Salivary neoplasms: overview of a 35-year experience with 2,807 patients. *Head Neck Surg.* 1986;8:177-184.
- Bova R. A guide to salivary gland disorders. *Medicine Today.* 2006;7:44-48.
- Zhang S, Bao R, Bagby J, et al. Fine needle aspiration of salivary glands: 5-year experience from a single academic center. *Acta Cytol.* 2009;53:375-382.
- Bova R, Saylor A, Coman WB. Parotidectomy: review of treatment and outcomes. *ANZ J Surg.* 2004;74:563-568.
- Sood S, McGurk M, Vaz F. Management of salivary gland tumours: United Kingdom National Multidisciplinary Guidelines. *J Laryngol Otol.* 2016;130:S142-S149.
- Mandel L. Salivary gland disorders. *Med Clin North Am.* 2014; 98:1407-1449.
- Mandel L, Abai S. Diagnosing bulimia nervosa with parotid gland swelling. *J Am Dent Assoc.* 2004;135:613-616.
- Lustmann J, Regev E, Melamed Y. Sialolithiasis. A survey on 245 patients and a review of literature. *Int J Oral Maxillofac Surg.* 1990;19:135-138.
- Vogl TJ, Al-Nawas B, Beutner D, et al. Updated S2K AWMF guideline for the diagnosis and follow-up of obstructive sialadenitis—relevance for radiologic imaging. *Rofo.* 2014;186: 843-846.
- Schwarz D, Kabbasch C, Scheer M, et al. Comparative analysis of sialendoscopy, sonography, and CBCT in the detection of sialolithiasis. *Laryngoscope.* 2015;125:1098-1101.
- Atienza G, López-Cedrún JL. Management of obstructive salivary disorders by sialendoscopy: a systematic review. *Br J Oral Maxillofac Surg.* 2015;53:507-519.
- Escudier MP, Brown JE, Putcha V, et al. Factors influencing the outcome of extracorporeal shock wave lithotripsy in the management of salivary calculi. *Laryngoscope.* 2010;120: 1545-1549.
- Koch M, Schapher M, Mantsopoulos K, et al. Multimodal treatment in difficult sialolithiasis: Role of extracorporeal shock-wave lithotripsy and intraductal pneumatic lithotripsy. *Laryngoscope.* 2018;128:E332-E338.
- McQuone SJ. Acute viral and bacterial infections of the salivary glands. *Otolaryngol Clin North Am.* 1999;32:793-811.
- O'Neil C, Sidhu S. Salivary gland disorders. *Australian Doctor.* 2011;28:19-25.
- Mandel L. Differentiating acute suppurative parotitis from acute exacerbation of a chronic parotitis: case reports. *J Oral Maxillofac Surg.* 2008;66:1964-1968.
- Chow AW. Suppurative parotitis in adults. UpToDate.com. www.uptodate.com/contents/suppurative-parotitis-in-adults. Accessed September 25, 2019.
- Katz SL, Gershon AA, Hotez PJ. *Infectious Diseases of Children.* New York, NY: Mosby Year Book; 1998:280-289.
- Krause CH, Molyneux PJ, Ho-Yen DO, et al. Comparison of mumps-IgM ELISAs in acute infection. *J Clin Virol.* 2007;38: 153-156.
- Quenin S, Plouin-Gaudon I, Marchal F, et al. Juvenile recurrent parotitis: sialendoscopic approach. *Arch Otolaryngol Head Neck Surg.* 2008;134:715-719.
- Papas AS, Sherrer YS, Charney M, et al. Successful treatment of dry mouth and dry eye symptoms in Sjögren's syndrome patients with oral pilocarpine: a randomized, placebo-controlled, dose-adjustment study. *J Clin Rheumatol.* 2004;10: 169-177.



**Pus can often be expressed from the respective intraoral orifice in sialadenitis. Send expressed pus for culture to guide antibiotic therapy.**