



Right hip and pelvic pain

Follow-up imaging confirmed a clinical suspicion.

A **65-YEAR-OLD MAN** with a history of remote colon cancer, peptic ulcer disease, gastroesophageal reflux disease (GERD), and bilateral knee replacements presented with right groin and hip pain of more than a year's duration. The patient described his hip pain as aching and said that it had worsened over the previous 6 months, interfering with his sleep. He said the pain worsened following activity, and it briefly felt better following an intra-articular corticosteroid injection into his right hip. The patient denied recent trauma or

fracture and said he had no scalp pain, hearing loss, or spinal tenderness. Physical examination showed limited range of motion of the right hip and mild tenderness to palpation. Laboratory values were within normal limits. X-rays of the pelvis (**FIGURE 1A**) and right hip (**FIGURE 1B**) were ordered.

- WHAT IS YOUR DIAGNOSIS?
- HOW WOULD YOU TREAT THIS PATIENT?

Don Nguyen, MD, MHA; Peter O'Connor, DO; Cassie Tran, MD; Jawad Qureshi, MD
Brigham and Women's Hospital, Boston, MA (Dr. Nguyen); Medical University of South Carolina, Charleston (Dr. O'Connor); Allegheny Health Network, PA (Dr. Tran); Beth Israel Deaconess Medical Center, Boston (Dr. Qureshi)

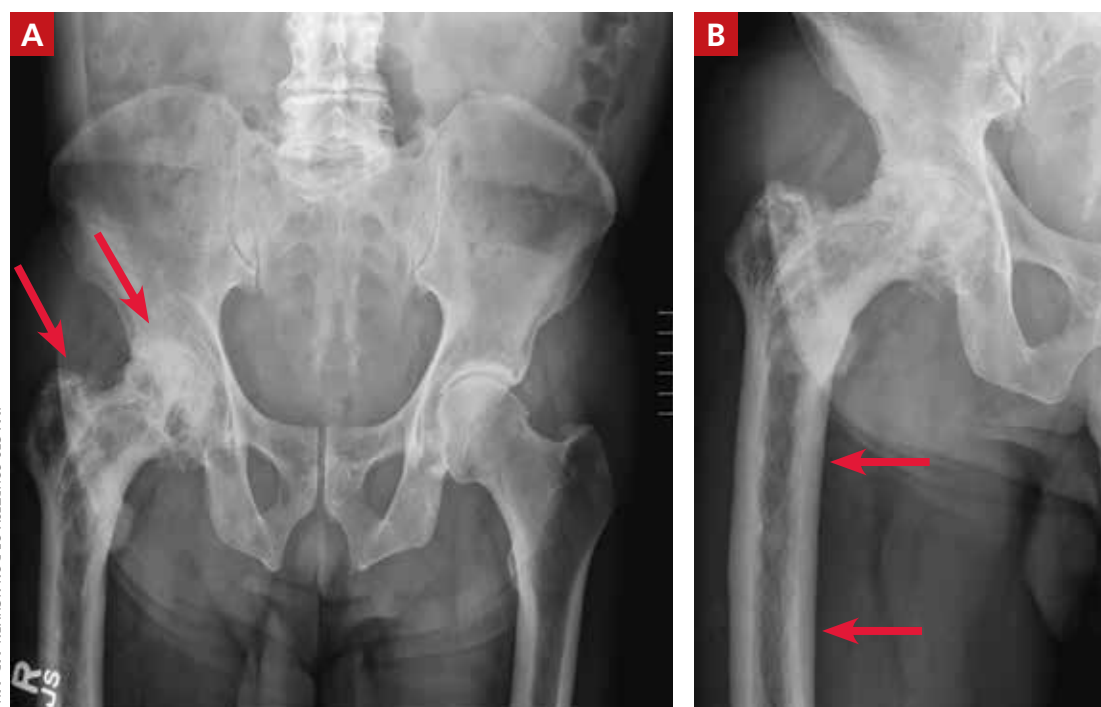
dnguyen42@bwh.harvard.edu

DEPARTMENT EDITOR
Richard P. Usatine, MD
University of Texas Health at San Antonio

The authors reported no potential conflict of interest relevant to this article.

FIGURE 1

X-rays reveal a coarsened trabecular pattern and mild bony enlargement of the right femoral head, neck, and diaphysis



IMAGES COURTESY OF DON NGUYEN, MD, MHA

Dx: Paget disease of bone

Based on the patient's clinical history and initial imaging studies, which showed characteristic trabecular thickening with bony enlargement of the right femur, we suspected that he had Paget disease of bone. This was confirmed on subsequent whole-body ^{99m}Tc -MDP bone scan (FIGURE 2), which revealed corresponding diffuse increased radiotracer uptake of the right femur. There was no scintigraphic evidence of osseous involvement of the skull, spine, or pelvis.

■ **Epidemiology/incidence.** Paget disease, also known as *osteitis deformans*, is fairly common in the aging population, with a prevalence ranging from 2% to almost 10%.^{1,2} Although onset before age 40 is rare, the diagnosis should be considered in younger patients, given the high prevalence. There is a slight male predominance, and the disease is more common in the United Kingdom and Western Europe, as well as in countries settled by European immigrants.³

■ **Both genetic and environmental causes** are believed to contribute to the pathogenesis of Paget disease. Mutations in the gene

encoding sequestosome 1 (SQSTM1) can be seen in the autosomal dominant familial type (25%-50% of these cases), as well as in sporadic cases.⁴ Environmental influence has also been postulated as a possible cause, with a viral etiology (eg, chronic measles infection) being the most cited.⁵

Most patients will be asymptomatic

Paget disease can affect any bone in the body, although the skull, spine, pelvis, and long bones of the lower extremity are the most commonly affected sites.² Most patients with Paget disease are asymptomatic. When symptoms are present, they either result from direct involvement of the bone or are secondary to bone overgrowth and deformity.

Direct involvement manifests as deep, constant bone pain that is worse at night. Symptoms related to bone overgrowth and deformity include spinal stenosis and related neurologic abnormalities, increased skull size, hearing loss (impingement of cranial nerve VIII), pathologic fracture (most commonly of the femur), and deformity such as protrusio acetabuli or femoral or tibial bowing.⁶ High-output heart failure and abnormalities in calcium and phosphate balance are uncommon but do occur.

■ **Degeneration into osteosarcoma** is a rare but almost invariably fatal complication of Paget disease, with an incidence of 0.2% to 1%.⁷ It clinically manifests as increased bone pain that is poorly responsive to medical therapy, local swelling, and pathologic fracture.⁸

Radiography is key to the work-up

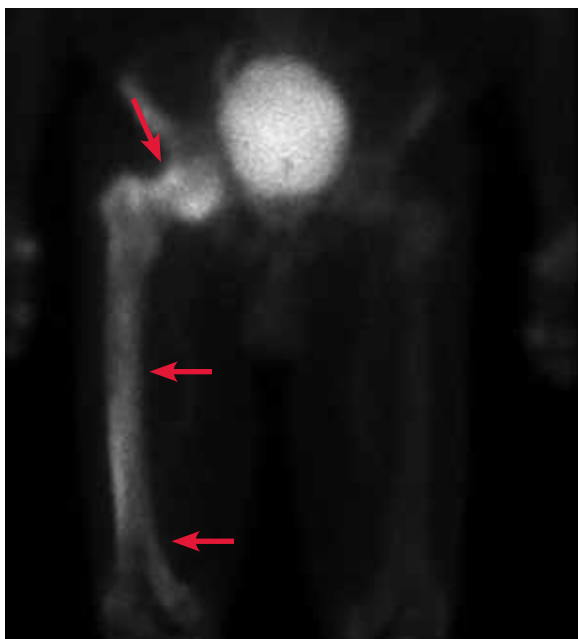The diagnosis of Paget disease is primarily radiographic. Early in the disease process, lytic lesions with thinning of the cortex will be noted. Later in the disease, there will be a mixed lytic/sclerotic phase, in which enlargement of the bone, a thickened cortex, and coarsened trabeculae are observed.

■ Characteristic radiographic findings.

Focal lytic lesions in the skull are known as *osteoporosis circumscripta*. In the sclerotic phase, there is a thickening of the calvaria (termed "cotton wool"). Lesions involving the long bones will begin at the proximal or distal subchondral region and progress toward the diaphysis, with a sharp oblique delineation

FIGURE 2

Bone scan confirms suspected Dx



A ^{99m}Tc -MDP bone scan shows abnormal increased radiotracer uptake with near whole bone involvement of the asymmetrically enlarged right femur.

between involved bone and normal bone; this is described as “blade of grass” or “flame-shaped.”⁹

Within the pelvis, there will be cortical thickening and sclerosis with enlargement of the iliac wing. Within the spine, there will be enlarged vertebrae with a thickened sclerotic border, resulting in a “picture frame” appearance. Later in the disease, the sclerosis will involve the entire vertebrae (termed “ivory vertebra”).¹⁰

Additional testing options include magnetic resonance imaging (MRI), bone scintigraphy, laboratory testing, and biopsy.

■ **MRI** is recommended when degeneration into osteosarcoma is present—indicated by permeative lesions with cortical breakthrough and a soft-tissue mass. MRI is helpful to further characterize the lesion. Absence of the normal fatty marrow on T1-weighted images would be concerning for tumor involvement.

■ **Bone scintigraphy** is used to determine the extent of disease. It will show increased uptake when the lesions are active.

■ **Laboratory testing.** Serum alkaline phosphatase (sAP) is frequently elevated in patients with Paget disease (normal range, 20-140 IU/L) and reflects the extent and activity of disease. However, this correlation is not always reliable; it depends on monostotic vs polyostotic involvement, as well as which bones are involved. For example, sAP levels may be markedly elevated when the skull is involved but normal when other bones are involved.¹¹ In patients with elevated sAP, serum calcium and 25-hydroxyvitamin D measurements should be obtained in anticipation of bisphosphonate treatment.

■ **Biopsy.** If the radiographic findings are typical for Paget disease, bone biopsy is not indicated. However, the main competing diagnosis to consider is malignancy; in atypical cases when imaging is unable to elucidate an underlying tumor, biopsy would be warranted.

■ **Differentiating Paget disease from sclerotic metastasis** is important. In metastasis, there will be no trabecular coarsening or enlargement of the bone.

Bisphosphonates are a Tx mainstay

Indications for treatment include symptomatic or asymptomatic disease with any of the following: elevated sAP with pagetic changes

at sites where complications could occur; sAP more than 2 to 4 times the upper limit of normal; normal sAP with abnormal bone scintigraphy at a site where complications could occur; planned surgery at an active pagetic site; and hypercalcemia in association with immobilization in patients with polyostotic disease.

■ **Newer generation nitrogen-containing bisphosphonates** are the mainstay of treatment; they ease pain, slow bone turnover, and promote deposition of normal lamellar bone, which over time will normalize sAP levels.¹² The most frequently used and studied bisphosphonates include oral alendronate, oral risedronate, and intravenous zoledronic acid.¹³

Prior to treatment initiation, the patient should have documented normal serum levels of calcium, phosphorus, and 25-hydroxyvitamin D, and these levels should be monitored throughout the first year of treatment. All patients should receive supplemental vitamin D and calcium to avoid hypocalcemia. sAP should be measured at 3 to 6 months to assess the initial response to therapy. Once the levels equilibrate, sAP can be measured once or twice a year to assess bone activity.¹⁴

■ **Our patient was referred** to Endocrinology for management of Paget disease of his right hip and femur. Lab values, including sAP and liver function test results, were normal. The patient was prescribed a zoledronic acid infusion (Reclast). At 4-week follow-up, the patient reported moderate relief of bone pain and improved sleep. **JFP**

CORRESPONDENCE

Don Nguyen, MD, MHA, Brigham and Women's Hospital, Department of Radiology, 75 Francis Street, Boston, MA 02115; dnguyen42@bwh.harvard.edu

REFERENCES

1. Altman RD, Bloch DA, Hochberg MC, et al. Prevalence of pelvic Paget's disease of bone in the United States. *J Bone Miner Res.* 2000;15:461-465.
2. Singer F. Paget's disease of bone. In: Feingold KR, Anawalt B, Boyce A, et al, eds. *Endotext.* South Dartmouth, MA: MDText.com, Inc.; 2000.
3. Merashli M, Jawad A. Paget's disease of bone among various ethnic groups. *Sultan Qaboos Univ Med J.* 2015;15:E22-E26.
4. Hocking LJ, Lucas GJ, Daroszewska A, et al. Domain-specific mutations in sequestosome 1 (SQSTM1) cause familial and sporadic Paget's disease. *Hum Mol Genet.* 2002;11:2735-2739.
5. Reddy SV, Kurihara N, Mena C, et al. Osteoclasts formed by measles virus-infected osteoclast precursors from hCD46 transgenic mice express characteristics of pagetic osteoclasts. *Endocrinology.* 2001;142:2898-2905.
6. Moore TE, King AR, Kathol MH, et al. Sarcoma in Paget disease of bone: clinical, radiologic, and pathologic features in 22 cases. *AJR Am J Roentgenol.* 1991;156:1199-1203.
7. van Staa TP, Selby P, Leufkens HG, et al. Incidence and natural



If the radiographic findings are typical for Paget disease, bone biopsy is not indicated.

history of Paget's disease of bone in England and Wales. *J Bone Miner Res.* 2002;17:465-471.

8. Hansen MF, Seton M, Merchant A. Osteosarcoma in Paget's disease of bone. *J Bone Miner Res.* 2006;21(suppl 2):P58-P63.

9. Wittenberg K. The blade of grass sign. *Radiology.* 2001;221:199-200.

10. Dennis JM. The solitary dense vertebral body. *Radiology.* 1961;77:618-621.

11. Seton M. Paget's disease of bone. In: Hochberg MC, Silman AJ, Smolen JS, et al, eds. *Rheumatology.* 4th ed. Philadelphia, PA: Mosby (Elsevier); 2008:2003.

12. Reid IR, Nicholson GC, Weinstein RS, et al. Biochemical and radiologic improvement in Paget's disease of bone treated with alendronate: a randomized, placebo-controlled trial. *Am J Med.* 1996;101:341-348.

13. Siris ES, Lyles KW, Singer FR, et al. Medical management of Paget's disease of bone: indications for treatment and review of current therapies. *J Bone Miner Res.* 2006;21(suppl 2):P94-P98.

14. Alvarez L, Peris P, Guañabens N, et al. Long-term biochemical response after bisphosphonate therapy in Paget's disease of bone: proposed intervals for monitoring treatment. *Rheumatology (Oxford).* 2004;43:869-874.

PSA CANCER SCREENING

CONTINUED FROM PAGE 32

death. The decision to undergo PSA screening should be made by both the provider and the patient, after a discussion of the limited benefits and associated harms. The interval of follow-up screening may vary from 2 to 4 years depending on patient age, level of PSA, and whether a patient is taking medications such as 5-alpha-reductase inhibitors. **JFP**

CORRESPONDENCE

Jaividhya Dasarathy, MD, FAAFP, 2500 Metro Health Medical Drive, Cleveland, Ohio 44109; jxd114@case.edu.

References

1. Siegel RL, Miller KD, Jemal A. Cancer statistics, 2016. *CA Cancer J Clin.* 2016;66:7-30.

2. National Cancer Institute Surveillance, Epidemiology, and End Results Program. Cancer Stat Facts: Prostate Cancer. <https://seer.cancer.gov/statfacts/html/prost.html>. Accessed January 16, 2020.

3. American Cancer Society. Key statistics for prostate cancer. Last revised August 1, 2019. www.cancer.org/cancer/prostate-cancer/about/key-statistics.html. Accessed January 16, 2020.

4. Brawley OW. Trends in prostate cancer in the United States. *J Natl Cancer Inst Monogr.* 2012;2012:152-156.

5. Powell IJ. Epidemiology and pathophysiology of prostate cancer in African-American men. *J Urol.* 2007;177:444-449.

6. Catalona WJ, Smith DS, Ratliff TL, et al. Measurement of prostate-specific antigen in serum as a screening test for prostate cancer. *N Engl J Med.* 1991;324:1156-1161.

7. Jacobsen SJ, Katusic SK, Bergstrahl EJ. Incidence of prostate cancer diagnosis in the eras before and after serum prostate-specific antigen testing. *JAMA.* 1995;274:1445-1449.

8. Mistry K, Cable G. Meta-analysis of prostate-specific antigen and digital rectal examination as screening tests for prostate carcinoma. *J Am Board Fam Pract.* 2003;16:95-101.

9. Qaseem A, Barry MJ, Denberg TD, et al. Screening for prostate cancer: a guidance statement from the Clinical Guidelines Committee of the American College of Physicians. *Ann Int Med.* 2013;158:761-769.

10. Andriole GL, Crawford ED, Grubb RL 3rd, et al. Prostate cancer screening in the randomized Prostate, Lung, Colorectal, and Ovarian Cancer Screening Trial: mortality results after 13 years of follow-up. *J Natl Cancer Inst.* 2012;104:125-132.

11. Schröder FH, Hugosson J, Roobol MJ, et al. Screening and prostate-cancer mortality in a randomized European study. *N Engl J Med.* 2009;360:1320-1328.

12. American Cancer Society. American Cancer Society recommendations for prostate cancer early detection. Last revised August 1, 2019. www.cancer.org/cancer/prostate-cancer/detection-diagnosis-staging/acs-recommendations.html. Accessed January 16, 2020.

13. American Urologic Association. Early detection of prostate cancer (2018). Reviewed 2018. <https://www.auanet.org/guidelines/prostate-cancer-early-detection-guideline>. Accessed January 16, 2020.

14. US Preventive Services Task Force. Screening for Prostate Cancer: US Preventive Services Task Force Recommendation Statement. *JAMA.* 2018;319:1901-1913.

15. Moyer VA. Screening for prostate cancer: US Preventive Services Task Force recommendation statement. *Ann Int Med.* 2012;157:120-134.

16. Labrie F, Candas B, Dupont A, et al. Screening decreases prostate cancer death: first analysis of the 1988 Quebec prospective randomized controlled trial. *Prostate.* 1999;38:83-91.

17. Sandblom G, Varenhorst E, Rosell J, et al. Randomised prostate cancer screening trial: 20-year follow-up. *BMJ.* 2011;342:d1539.

18. Schröder FH, Hugosson J, Roobol MJ, et al. Screening and prostate cancer mortality: results of the European Randomized Study of Screening for Prostate Cancer (ERSPC) at 13 years of follow-up. *Lancet.* 2014;384:2027-2035.

19. McNaughton-Collins M, Fowler FJ Jr, Caubet JF, et al. Psychological effects of a suspicious prostate cancer screening test followed by a benign biopsy result. *Am J Med.* 2004;117:719-725.

20. Raaijmakers R, Kirkels WJ, Roobol MJ, et al. Complication rates and risk factors of 5802 transrectal ultrasound-guided sextant biopsies of the prostate within a population-based screening program. *Urology.* 2002;60:826-830.

21. Loeb S, Carter HB, Berndt SI, et al. Complications after prostate biopsy: data from SEER-Medicare. *J Urol.* 2011;186:1830-1834.

22. Donovan J, Hamdy F, Lane J, et al. Patient-reported outcomes after monitoring, surgery, or radiotherapy for prostate cancer. *N Engl J Med.* 2016;375:1425-1437.

23. Hamdy FC, Donovan JL, Lane JA, et al. 10-year outcomes after monitoring, surgery, or radiotherapy for localized prostate cancer. *N Engl J Med.* 2016;375:1415-1424.

24. Wilt TJ, Jones KM, Barry MJ, et al. Follow-up of prostatectomy versus observation for early prostate cancer. *N Engl J Med.* 2017;377:132-142.

25. Bill-Axelson A, Holmberg L, Garmo H, et al. Radical prostatectomy or watchful waiting in early prostate cancer. *N Engl J Med.* 2018;379:2319-2329.

26. Hersch JK, Nickel BL, Ghanouni A, et al. Improving communication about cancer screening: moving towards informed decision making. *Public Health Res Pract.* 2017;27(2).

27. Cuzick J, Thorat MA, Andriole G, et al. Prevention and early detection of prostate cancer. *Lancet Oncol.* 2014;15:e484-e492.

28. Pinto PA, Chung PH, Rastinehad AR, et al. Magnetic resonance imaging/ultrasound fusion guided prostate biopsy improves cancer detection following transrectal ultrasound biopsy and correlates with multiparametric magnetic resonance imaging. *J Urol.* 2011;186:1281-1285.

29. Kuru TH, Roethke MC, Seidenader J, et al. Critical evaluation of magnetic resonance imaging targeted, transrectal ultrasound guided transperineal fusion biopsy for detection of prostate cancer. *J Urol.* 2013;190:1380-1386.

30. Crawford ED, Rove KO, Barqawi AB, et al. Clinical-pathologic correlation between transperineal mapping biopsies of the prostate and three-dimensional reconstruction of prostatectomy specimens. *Prostate.* 2013;73:778-787.

31. Elwyn G, Frosch D, Thomson R, et al. Shared decision making: a model for clinical practice. *J Gen Intern Med.* 2012;27:1361-1367.

32. Stacey D, Légaré F, Lewis K, et al. Decision aids for people facing health treatment or screening decisions. *Cochrane Database Syst Rev.* 2017;4:CD001431.

33. ASCO. Decision aid tool: prostate cancer screening with PSA testing. <https://www.asco.org/sites/new-www.asco.org/files/content-files/practice-and-guidelines/documents/2012-psa-pco-decision-aid.pdf>. Accessed January 16, 2020.

34. Daum LM, Reamer EN, Ruterbusch JJ, et al. Patient knowledge and qualities of treatment decisions for localized prostate cancer. *J Am Board Fam Med.* 2017;30:288-297.

35. Radhakrishnan A, Grande D, Ross M, et al. When primary care providers (PCPs) help patients choose prostate cancer treatment. *J Am Board Fam Med.* 2017;30:298-307.