



## Pruritic, lightly-scaled patches on wrists

A rash first appeared on this patient's left wrist and then spread to his right. Was his chrome-colored watch to blame?

A 19-YEAR-OLD MAN presented to our clinic with erythematous, pruritic, lightly-scaled, and annular patches on his dorsal wrists. The rash had first appeared 3 weeks earlier on the patient's left wrist, which is where he'd been wearing a chrome-colored watch for a couple of years. After the rash appeared on his left wrist, the patient began wearing the watch on his right wrist. Soon after the switch, the rash appeared on his right wrist. The patient was otherwise healthy and denied any previous rashes, had no body piercings or allergies of any kind, and was not on any medications.

On physical exam, we noted 2 erythematous, scaly, annular, and slightly raised plaques on the distal dorsal aspects of both forearms/wrists with a few erythematous papular lesions (FIGURE). There was also scaling on the soles of the patient's feet and white, moist scaling in the web space between his 4th and 5th toes bilaterally.

- WHAT IS YOUR DIAGNOSIS?
- HOW WOULD YOU TREAT THIS PATIENT?

### FIGURE

**Bilateral, erythematous plaques on both wrists**

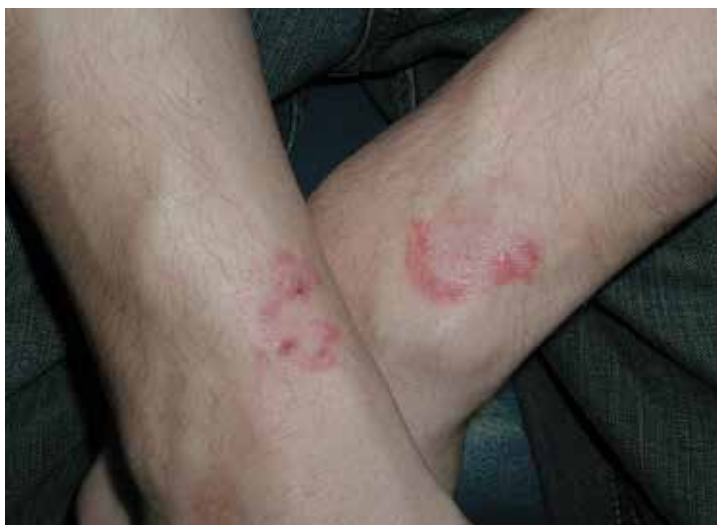

IMAGE COURTESY OF: STEPHEN E. HELMS, MD, FAAD

**Andrew Patrick Brodell, EMT;**  
**Stephen E. Helms, MD, FAAD**  
Colgate University, Hamilton,  
NY (Mr. Brodell); University of  
Mississippi Medical Center,  
Jackson (Dr. Helms)

[shelms@umc.edu](mailto:shelms@umc.edu)

### DEPARTMENT EDITOR

**Richard P. Usatine, MD**  
University of Texas Health  
Science Center at San Antonio

*The authors reported no potential  
conflict of interest relevant to this  
article.*

➤ The wrists are not a common place for tinea corporis, but the condition can occur anywhere on the body.

### Diagnosis: Tinea corporis (ringworm)

The patient and physician initially considered the possibility of allergic contact dermatitis due to nickel because of the history of redness, scaling, and itching underneath the watch when it was worn on the left wrist, and then when it was worn on the right wrist. Nickel dermatitis is common and it is easy to attribute the cause of a condition like this to the most obvious diagnosis without considering a more complete differential diagnosis.<sup>1</sup>

However, there were clues that prompted us to suspect tinea corporis (ringworm). The red, scaly rash spread centrifugally over several weeks, and fomites, such as a watch, can spread infectious diseases. Also, our patient had a few erythematous papular lesions, and the presence of papules in addition to scaling rings is typical of fungal infections involving hair follicles (Majocchi's granuloma).

A positive potassium hydroxide (KOH) preparation confirmed the diagnosis and eliminated the need for nickel patch testing.<sup>2</sup>

### Warmth and moisture could explain tinea on the wrists

Dermatophytes are fungi that can cause infections in the skin, hair, and nails. They are classified by where they are found—anthropophilic (humans), geophilic (soil), or zoophilic (animals). Anthropophilic and zoophilic dermatophytes from the genera *Trichophyton*, *Microsporum*, and *Epidermophyton* are primarily responsible for human fungal infections.<sup>3</sup> It is estimated that superficial fungal infections affect up to a quarter of the world's population.<sup>3</sup>

Tinea corporis mainly occurs in prepubertal children, presenting as a red, annular, scaly, pruritic patch with central clearing and an active border.<sup>4</sup> Tinea corporis includes all superficial dermatophyte infections of the glabrous skin and is particularly common in areas of excessive heat and moisture.<sup>5</sup> Patients can pick up tinea corporis via fomites at the gym, through soil in the garden, or by touching a pet's fur or a child's scalp when either has the fungal infection.

The wrists are not a common place for tinea corporis, but the condition can occur anywhere on the body. This patient may well

have contracted tinea from his own interdigital tinea pedis. Warmth and moisture under the watch could also explain the predilection for fungus to grow on the wrists.

### Distinguish between contact dermatitis and tinea corporis

The differential diagnosis for tinea corporis includes allergic contact dermatitis, granuloma annulare, annular elastolytic granuloma, and erythema chronicum migrans.

■ **Allergic contact dermatitis** is caused by an allergy to a substance, such as the metal nickel. A preliminary diagnosis of contact dermatitis could easily be made in error if one were to assume that a patient was having a type IV hypersensitivity response to nickel from a watch.<sup>6</sup>

■ **Granuloma annulare** produces slowly expanding annular plaques that are not itchy and do not scale. This commonly occurs over the joints and is of unknown etiology.<sup>7</sup>

■ **Annular elastolytic granuloma** is a variant of granuloma annulare that occurs on skin that has been exposed to the sun. It presents with a red, ring-like pattern and is associated with little scaling or pruritus.<sup>8</sup>

■ **Erythema chronicum migrans** produces annular lesions at the site of a tick bite and is the primary sign of Lyme disease. The tick must be in place for 24 hours for infection to occur.<sup>9</sup> (Our patient did not notice a tick attached at either site.)

In this case, a KOH preparation of skin scrapings identified septate hyphae, which supported our diagnosis of tinea corporis.<sup>2</sup> A history of red, scaly, itchy, and expanding round/oval patches or plaques and evidence of "athlete's foot" can also help one to make the diagnosis.

### Antifungal agents will clear the rash

Proper treatment of tinea corporis consists of antifungal creams containing ketoconazole, econazole, or naftifine on non-hair-bearing areas. The creams should be applied twice daily and rarely cause adverse effects. Bandages are not usually necessary, but may be used if contact with others is anticipated. For the scalp and other hair-bearing areas, systemic treatment with terbinafine 250 mg daily

for one month in an adult is necessary. Oral agents will usually clear the rash within 4 to 6 weeks.<sup>10,11</sup>

**Because our patient had bilateral involvement and some papule formation indicating Majocchi's granuloma, we prescribed oral terbinafine 250 mg daily for 2 weeks in**

addition to econazole cream. The patient was to apply the cream for a total of 4 weeks to ensure the rash did not recur.

**JFP**

**CORRESPONDENCE**

Stephen E. Helms, MD, Department of Dermatology, University of Mississippi Medical Center, 2500 North State Street, Jackson, MS 39216; shelms@umc.edu.

**References**

1. Groopman J. *How Doctors Think*. Houghton Mifflin Co: Boston, Massachusetts; 2007.
2. Panasiti V, Borroni RG, Devirgiliis V, et al. Comparison of diagnostic methods in the diagnosis of dermatomycoses and onychomycoses. *Mycoses*. 2006;49:26-29.
3. Havlickova B, Czaika VA, Friedrich M. Epidemiological trends in skin mycoses worldwide. *Mycoses*. 2008;51:2-15.
4. Ely JW, Rosenfeld S, Seabury Stone M. Diagnosis and management of tinea infections. *Am Fam Physician*. 2014;90:702-710.
5. Gupta AK, Chaudhry M, Elewski B. Tinea corporis, tinea cruris, tinea nigra, and piedra. *Dermatol Clin*. 2003;21:395-400.
6. Lidén C, Menné T, Burrows D. Nickel-containing alloys and platings and their ability to cause dermatitis. *Br J Dermatol*. 1996;134:193-198.
7. Barron DF, Cootauco MH, Cohen BA. Granuloma annulare. A clinical review. *Lippincott's Prim Care Pract*. 1997;1:33-39.
8. Ventura F, Vilarinho C, da Luz Duarte M, et al. Two cases of annular elastolytic giant cell granuloma: Different response to the treatment. *Dermatol Online J*. 2010;16:11.
9. Feder HM Jr, Abeles M, Bernstein M, et al. Diagnosis, treatment, and prognosis of erythema migrans and Lyme arthritis. *Clin Dermatol*. 2006;24:509-520.
10. Kelly BP. Superficial fungal infections. *Pediatr Rev*. 2012;33:e22-e37.
11. Rotta I, Sanchez A, Gonçalves PR, et al. Efficacy and safety of topical antifungals in the treatment of dermatomycosis: a systematic review. *Br J Dermatol*. 2012;166:927-933.

NOW ONLINE AT [WWW.JFPONLINE.COM](http://WWW.JFPONLINE.COM)

A supplement to The Journal of Family Practice


# Advances in Colorectal Cancer Screening

## Author

**Anas Daghestani, MD**  
Director of Population Health  
and Clinical Quality  
Austin Regional Clinic  
Austin, Texas

## Discussion includes:

- Colonoscopy
- Computed tomography colonography
- Fecal occult blood test and fecal immunochemical test
- Multitarget stool DNA testing



This supplement is supported by funding from Exact Sciences.