

The Diagnosis and Initial Treatment of Patellofemoral Disorders

Alan C. Merchant, MD, MS, John P. Fulkerson, MD, and Wayne Leadbetter, MD

Abstract

Our purpose is to provide simple guidelines for the diagnosis and early care of patellofemoral disorders. Any clinician who treats knee problems, including family practitioners, rheumatologists, orthopedic surgeons, or physical therapists, must know how to make the correct diagnosis, or at least a presumptive diagnosis, at the initial visit. This can avoid unneeded and costly tests, ineffective treatment, and even damaging exercises and unnecessary surgery. The diagnosis of patellofemoral disorders is confusing because they can have many causes. That is, the etiology of patellofemoral disorders is multifactorial.

To dispel this confusion and simplify the process, we use a clinical classification based on etiology. Within that framework are 7 key abnormalities or factors that can cause both patellofemoral pain and instability: vastus medialis obliquus deficiency, medial patellofemoral ligament laxity, lateral retinaculum tightness, increased quadriceps angle, hip abductor weakness, patella alta, and trochlear dysplasia.

At the initial evaluation, the clinician can assess for these abnormalities through history-taking, physical examination, and standard radiography. Any abnormalities identified, along with their severity, can be used to arrive at a diagnosis, or a presumptive diagnosis, and begin early nonoperative treatment. The clinician does not need magnetic resonance imaging at this point, unless a presumptive diagnosis cannot be made or a more complex problem is suggested.

Take-Home Points

- Patellofemoral disorders should be classified and diagnosed according to specific diagnostic categories (eg, lateral patellar compression syndrome) based on etiology rather than nondescriptive terminology (eg, internal derangement, patellofemoral pain syndrome).
- Patellofemoral dysplasia defines a spectrum of abnormalities ranging from the mild lateral patellar compression syndrome to the severe recurrent patellar dislocation.
- There is an inverse relationship between patient activity level and underlying patellofemoral dysplasia. This relationship determines threshold levels for each patient becoming symptomatic.
- Patients should be examined for 7 physical abnormalities, and if present, in what severity. These 7 are: vastus medialis obliquus deficiency, medial patellofemoral ligament laxity, lateral retinaculum tightness, increased quadriceps angle, hip abductor weakness, patella alta, and trochlear dysplasia.
- Advanced imaging is rarely, if ever, needed to make a diagnosis or to formulate an initial treatment plan for these common patellofemoral disorders.

To diagnose any disease or disorder implies an understanding of the condition's cause(s), which should then lead to a logical treatment plan. For all too long, however, the diagnosis and treatment of patellofemoral disorders have been hampered by diagnoses that lack specific definitions based on etiology. A few of these are: internal derangement, chondromalacia patellae, patellar maltracking, and patellofemoral pain syndrome.

To simplify the diagnosis of patellofemoral

disorders, we use a clinical classification based on etiology. This system's defined diagnostic categories are useful in identifying probable cause(s), which can be appropriately evaluated and treated (Table).¹ In simple terms, the philosophy of this approach is to *try to find out what's wrong, and try to fix it!*

This clinical classification provides a framework for common patellofemoral conditions that are more easily diagnosed, yet is intentionally

Authors' Disclosure Statement: The authors report no actual or potential conflict of interest in relation to this article.

incomplete omitting rare conditions (eg, tumors, metabolic bone disease, neurologic conditions). This allows the focus to fall on the common and frequently misunderstood causes for patellofemoral pain and instability. In this article, we address patellofemoral dysplasia (section II of the Table) and its classification relating to initial evaluation and early treatment. This entity defines a spectrum of abnormalities, ranging from the mild lateral patellar compression syndrome (LPCS) to the moderate chronic subluxation of the patella (CSP) and severe recurrent dislocation of the patella (RDP). Each presumptive diagnosis is suggested by the patient's history and confirmed by physical examination and radiography. Computed tomography (CT), magnetic resonance imaging (MRI), and other advanced imaging modalities are seldom needed to establish a working diagnosis and an initial treatment plan, though they can be important in operative planning for complex cases.

Patellofemoral Dysplasia

Patellofemoral dysplasia (or extensor mechanism malfunction) is a cluster of physical abnormalities relating to the patellofemoral joint that vary from mild to severe and affect the normal function of that joint. As such, patellofemoral dysplasia itself should be considered on a continuum of mild to severe. To simplify the diagnosis, the clinician should systematically identify these factors and their severity. Armed with this information, the clinician can make the diagnosis and formulate a logical treatment plan for each individual patient.

This article focuses on 7 physical abnormalities that are most likely developmental and that can be identified through physical and radiologic examination. When and how each patient with patellofemoral dysplasia becomes symptomatic are determined by 2 key factors: patellofemoral dysplasia severity and activity level (sedentary to strenuous), in an inverse relationship (Figure 1).² Their complex interplay determines when a patient exceeds the "envelope of function"³ and passes from asymptomatic to symptomatic.

Seven Key Patellofemoral Physical Abnormalities

Of the 7 commonly identified physical abnormalities that affect the normal functioning of the patellofemoral joint, 5 are discovered by physical examination and 2 by radiography; CT and MRI are seldom needed in the initial evaluation. The most accurate and objective method should be used to assess the presence and severity of each abnormality.

Table. **Clinical Classification of Patellofemoral Disorders^a**

I. Trauma (conditions caused by trauma in otherwise normal knee)	
A. Acute trauma	<ol style="list-style-type: none"> 1. Contusion 2. Fracture <ol style="list-style-type: none"> a. Patella b. Femoral trochlea c. Proximal tibial epiphyses (tubercle) 3. Patellar dislocation (uncommon in normal knee) 4. Rupture <ol style="list-style-type: none"> a. Quadriceps tendon b. Patellar tendon
B. Repetitive trauma (overuse syndromes)	<ol style="list-style-type: none"> 1. Patellar tendinitis ("jumper's knee") 2. Quadriceps tendinitis 3. Peripatellar tendinitis (eg, anterior knee pain in adolescents, caused by hamstring contracture) 4. Prepatellar bursitis ("housemaid's knee") 5. Apophysitis <ol style="list-style-type: none"> a. Osgood-Schlatter disease b. Sinding-Larsen-Johansson disease
C. Late effects of trauma	<ol style="list-style-type: none"> 1. Posttraumatic patellar chondrosis 2. Posttraumatic patellofemoral arthrosis 3. Anterior fat pad syndrome, Hoffa syndrome (posttraumatic fibrosis) 4. Reflex sympathetic dystrophy of patella 5. Patellar osseous dystrophy 6. Acquired patella infera 7. Acquired quadriceps fibrosis
II. Patellofemoral dysplasia (or extensor mechanism malfunction)	
A. Lateral patellar compression syndrome	<ol style="list-style-type: none"> 1. Secondary patellar chondrosis 2. Secondary patellofemoral arthrosis
B. Chronic subluxation of patella	<ol style="list-style-type: none"> 1. Secondary patellar chondrosis 2. Secondary patellofemoral arthrosis
C. Recurrent dislocation of patella	<ol style="list-style-type: none"> 1. Associated fractures <ol style="list-style-type: none"> a. Osteochondral (intra-articular) b. Avulsion (extra-articular) 2. Secondary patellar chondrosis 3. Secondary patellofemoral arthrosis
D. Chronic dislocation of patella	<ol style="list-style-type: none"> 1. Developmental 2. Acquired
III. Idiopathic patellar chondrosis	
IV. Osteochondritis dissecans	
A. Patella	
B. Femoral trochlea	
V. Synovial plicae (anatomical variants made symptomatic by acute or repetitive trauma)	
A. Pathologic medial patellar plica ("shelf")	
B. Pathologic suprapatellar plica	
C. Pathologic lateral patellar plica	
VI. Iatrogenic disorders	
A. Iatrogenic medial patellar compression syndrome	
B. Iatrogenic recurrent medial subluxation of patella	
C. Iatrogenic patella infera	

^aModified from *Arthroscopy*.¹

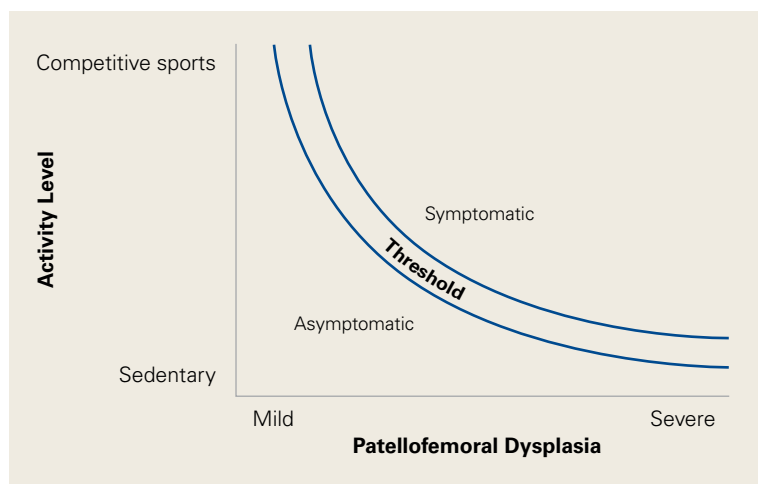


Figure 1. Diagram shows inverse relationship between severity of patellofemoral dysplasia and patient activity level. Relationship determines when any given patient will cross symptomatic threshold.

Reprinted with permission from *Operative Arthroscopy*.²

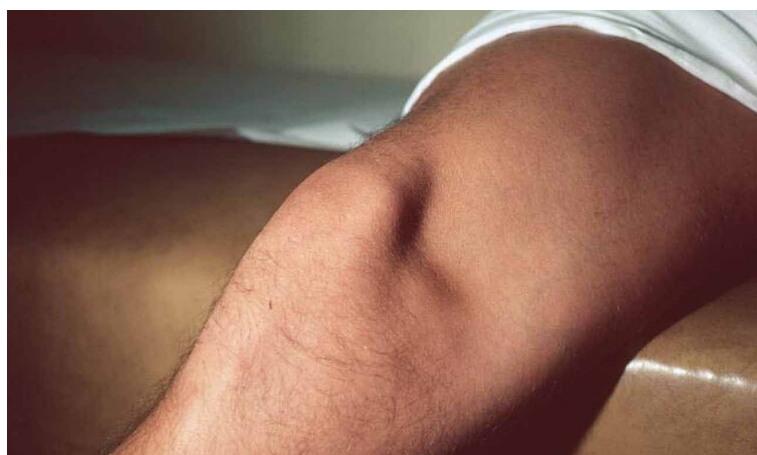

Figure 2. With quadriceps contracted holding knee at 30° flexion and with foot unsupported, deficient vastus medialis obliquus leaves characteristic hollow on medial aspect of knee.

Reprinted with permission from *Anterior Knee Pain and Patellar Instability*.⁴

The 7 abnormalities are vastus medialis obliquus (VMO) deficiency, medial patellofemoral ligament (MPFL) laxity, lateral retinaculum (LR) tightness, increased quadriceps (Q) angle, hip abductor weakness, patella alta, and trochlear dysplasia. We list these not in order of importance but in the order in which they are usually encountered during initial evaluation. We advocate for examining both knees including axial patellofemoral radiographs because patellofemoral disorders are frequently bilateral. It is helpful to use an abnormality checklist so none are forgotten. Also useful is a simple shorthand for findings: 0 = normal (no abnormality), 1 = mild abnormality, 2 = moderate abnormality, 3 = severe

abnormality, with the right knee always recorded first (R/L). For example, severe left MPFL laxity is recorded as 0/3. Numerical values (eg, Q angles) can be directly recorded in this manner: 14°/23°.

1. Vastus Medialis Obliquus Deficiency

VMO deficiency is best seen as the sitting patient actively maintains the unsupported foot and leg at 30° knee flexion. Normally, the VMO inserts into the upper half or third of the medial edge of the patella; a deficient VMO inserts higher into the medial edge of the quadriceps tendon, or it is absent and leaves a characteristic hollow at the medial edge of the patella (**Figure 2**).⁴ Studies using ultrasonography and CT have found significant correlations between VMO abnormalities and anterior knee pain.^{5,6} Although there is no simple clinical method of measuring VMO deficiency, clinicians experienced in observing knees can assess VMO deficiency and grade each case mild, moderate, or severe. The VMO deficiency weakens the medial quadriceps vector, increasing the lateral vector, and thereby increases the “dynamic” Q angle, originally described by Brattström.⁷

2. Medial Patellofemoral Ligament Laxity

MPFL laxity is assessed with the lateral glide test. Again, the patient sits, but with quadriceps relaxed and foot and leg supported at 30° knee flexion. With the clinician mentally dividing the patella into vertical quadrants and pushing the patella laterally, the normal patella moves about 1 quadrant or 1 fingerbreadth. Severe MPFL laxity often elicits a positive apprehension response during the test. (Tip: Many patients are unable to relax the quadriceps while sitting; therefore, examine them supine and lift the knee into 30° flexion.) Such laxity usually means the MPFL was torn in a previous dislocation and remains elongated, leaving the patella vulnerable to repeated dislocations. The clinician should be alert to the possibility of hyperelastosis (Ehlers-Danlos syndrome) and a hyper-mobile patella. The opposite limb should be evaluated for asymmetric laxity.

3. Lateral Retinaculum Tightness

LR tightness is assessed with the medial glide test, again with the quadriceps relaxed and the knee supported at 30° flexion. With a normal LR, the patella can be pushed medially about 1 quadrant or 1 fingerbreadth. Some clinicians prefer the lateral tilt-up test, in which the lateral edge of the patella is lifted up, but this method is more difficult

to quantify, is affected by the cross-sectional shape of the patella, and lacks consistency.

4. Increased Quadriceps Angle

The Q angle is one of the most important factors in the normal functioning of the patellofemoral joint. For more than a century,⁸ multiple operations have been used successfully to move the tibial tubercle (TT) and patellar ligament from a lateral position to a medial position thereby decreasing the Q angle. It is only logical to measure this angle at every knee examination to check for an abnormal increase, and the degree. The term *quadriceps angle*, or *Q angle*, was first used in 1964 by Brattström,⁷ who defined it as the “supplemental angle” to the valgus angle formed by the “quadriceps’ resultant” (line of force or vector) “+ patella + ligamentum patellae.” This might be called the *dynamic Q angle*. With there being no clinical method of measuring the “quadriceps line of force,” or quadriceps vector, clinicians used a line from the anterior superior iliac spine to the center of the patella, yet still called it the Q angle. By convention, this anatomical Q angle has been accepted as the Q angle.

Because the Q angle is the only clinical measurement of TT lateralization at initial evaluation, its measurement should be standardized, accurate, and simple to perform. Placing the patient supine with the lower limb in neutral rotation (patella anterior) and the knee in full extension standardizes the position. In full extension, the tibia reaches its maximum external rotation owing to the terminal “screw home” mechanism. The clinician should center the patella to the trochlear groove (TG) while measuring the Q angle, as it is the relationship of the TT to the trochlea, not to the patella, that is important. If LR tightness prevents the patella from centering, that fact should be recorded during the medial glide test for LR tightness. For accuracy, the goniometer should have one or more arms long enough to reach the anterior superior iliac spine. A long-armed goniometer is simple to make, and 2 extendable goniometers are commercially available (**Figures 3A-3C**).

Despite the importance of measuring the Q angle, there has been no standard technique. Multiple authors have attempted to define the “normal” Q angle. In 1999, Post⁹ reviewed 7 articles on the topic and found no agreement. Mean normal Q angles varied widely, from 5° to 23° (SD range, 0.08°-5°). Grelsamer and colleagues,¹⁰ using a long-armed goniometer and standard technique,

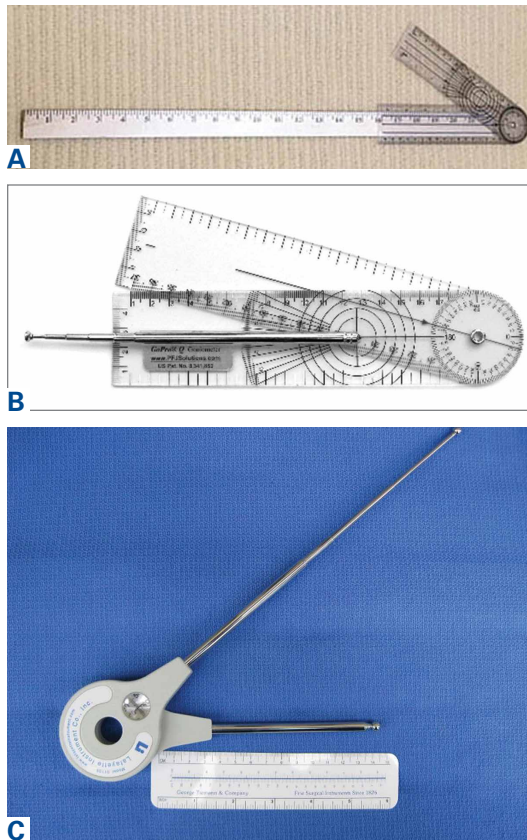


Figure 3. (A) Plastic goniometer glued accurately to 22-inch segment of yardstick. (B) Extendable pocket goniometer (GoPro Goniometer, PFJ Solutions). (C) Large extendable goniometer (Lafayette Gollehon Extendable Goniometer, Lafayette Instrument Company).

found a mean Q angle of 15.7° for women and 13.3° for men; the small, 2.4° difference between them disappeared when the measurements were corrected for height. Men and women of similar height have similar Q angles. These findings disproved the common misattribution of the differences to the wider female pelvis.

Given this confusion and the lack of accuracy in measuring the Q angle, many, if not most, surgeons turned to special CT and MRI scanning techniques to measure the distance of lateralization from TT to TG (TT-TG distance). This technique, by necessity, enforced a standardization not found in the earlier Q angles studies. Patients were positioned supine with the knee fully extended, and patellar position was ignored in favor of the TG. However, recent articles¹¹⁻¹⁴ have called into question the accuracy and usefulness of TT-TG distance as an assessment of TT lateralization. As such, standardized measurement of the Q angle remains a simple, inexpensive, and clinically relevant

method of assessing TT lateralization.

The possible causes of an increased Q angle are valgus limb alignment, internal femoral torsion, external tibial torsion, combined internal femoral and external tibial torsion with foot pronation (the “miserable malalignment” of James and colleagues¹⁵), and a TT-lateralizing proximal tibial malformation.

5. Hip Abductor Weakness

The step-down test is easily performed in the office by having the patient stand on a short stool or stair and then slowly step down with the opposite limb to just touch the heel and slowly arise again. A positive test is indicated by the Trendelenburg sign, with the pelvis dropping down and away from the symptomatic supporting limb, the flexing knee collapsing into valgus, and the patient tending to wobble and lack stability (Figure 4).¹⁶ With mild hip abductor weakness, these changes can be subtle, but they may become more severe with increasing weakness. Khayambashi and colleagues¹⁷ found that hip abductor weakness can be a major cause of patellofemoral pain.

6. Patella Alta

Patella alta not only allows the patella to escape the confines of the trochlea earlier during active knee extension increasing the risk of patellar dis-

location, but also decreases the contact footprint with the trochlea, increasing the patellofemoral joint reaction force and potentially causing patellofemoral pain and even secondary chondrosis. The simplest way to assess patellar height is with a lateral radiograph of the knee. The 3 popular methods (Insall-Salvati, Caton-Deschamps, Blackburn-Peel) all put the normal patellar height ratio at approximately 1:1, $\pm 20\%$. Berg and colleagues¹⁸ compared radiologic techniques for measuring patellar height ratio and found that Blackburn-Peel was the most accurate, reliable, and reproducible method.

7. Trochlear Dysplasia

Trochlear dysplasia, most simply a flattening of the TG, is perhaps the most important factor effecting normal patellofemoral function. However, it remains the most difficult to correctly address surgically. Senavongse and Amis¹⁹ conducted a cadaveric study demonstrating the prime importance of the TG. They found patellar stability was reduced 30% by releasing the VMO, 49% by cutting the MPFL in full knee extension, and 70% by flattening the trochlea. The most common, successful operations for correcting patellar instability depend on changing other factors that guide patellar excursion to compensate for this trochlear flattening.

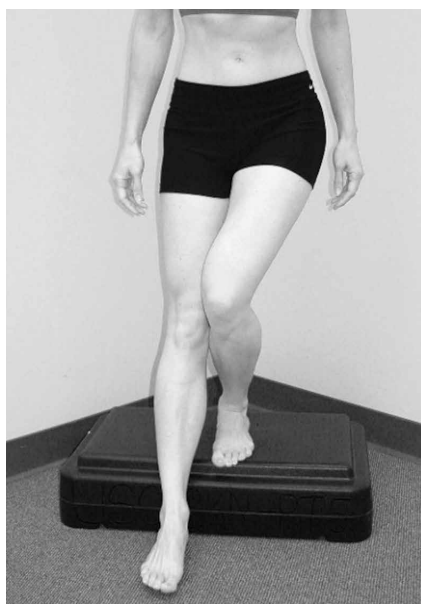

Figure 4. Positive step-down test with pelvis tilting down and away from supporting limb (Trendelenburg sign) and supporting knee collapsing medially into valgus.

Reprinted with permission from *Pathology and Intervention in Musculoskeletal Rehabilitation*.¹⁶

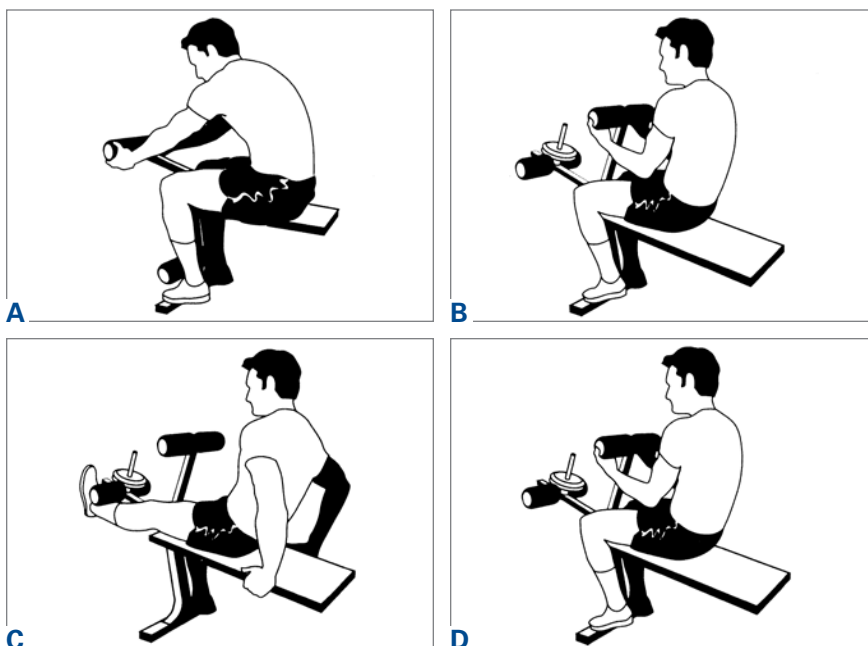


Figure 5. DeHaven exercises (progressive resistive quadriceps exercises in full extension). (A, B) Weight lifted by arms. (C) Leg fully extended to support weight for full 5 seconds. (D) Weight again supported by arms as knee is flexed to 90° without resistance.

Reprinted with permission from *The Patellofemoral Joint*.²⁶

The simplest way to assess trochlear dysplasia is to measure the sulcus angle on an accurate axial view radiograph of the knee at 45° flexion (Merchant view).²⁰ Dejour and colleagues²¹ popularized a technique of assessing and classifying trochlear dysplasia from a true lateral radiograph of the knee, which has the advantage of showing the trochlear at its proximal extent. Davies and colleagues²² evaluated the Dejour technique, along with patellar tilt, patellar height, and sulcus angle, to identify a rapid and reproducible radiologic feature that would indicate the need for further analysis by other imaging studies (eg, CT, MRI). They found that, if the sulcus angle was normal, analysis of other radiologic features was unlikely to reveal additional useful information. They also showed a correlation of increasing sulcus angle and severity of those other dysplasia features. Merchant and colleagues²⁰ found a mean normal sulcus angle of 138° (SD, 6°; range, 126°-150°), and Aglietti and colleagues²³ confirmed those findings with nearly identical values (mean, 137°; SD, 6°; range, 116°-151°).

Diagnosis and Initial Treatment Plan

Patellofemoral disorders generally are divided into patellofemoral pain and instability, but these 2 diagnostic categories are too broad to be useful. Patellofemoral pain is a symptom. Patellofemoral pain syndrome should never be used as a diagnosis because there is no accepted definition for the cluster of findings that customarily defines a syndrome. At initial evaluation, after the easily diagnosed causes of anterior knee pain (eg, prepatellar bursitis, TT apophysitis, patellar and quadriceps tendinitis) have been ruled out, the clinician should consider types of patellofemoral dysplasia for a presumptive diagnosis, which will then lead to a logical treatment program for each identified disorder. With a presumptive diagnosis established, almost all patients suffering from chronic anterior knee pain without history of injury are treated initially with rest, ice, and nonsteroidal anti-inflammatory drugs to restore joint homeostasis.³

Lateral Patellar Compression Syndrome

In 1975, Ficat and colleagues²⁴ described features of what they called *syndrome d'hyperpression externe de la rotule*. Two years later, Ficat and Hungerford²⁵ defined the syndrome as one "in which the patella is well centered in the trochlear sulcus and stable, but in which there is a *functional lateralization* onto a physiologically and often anatom-

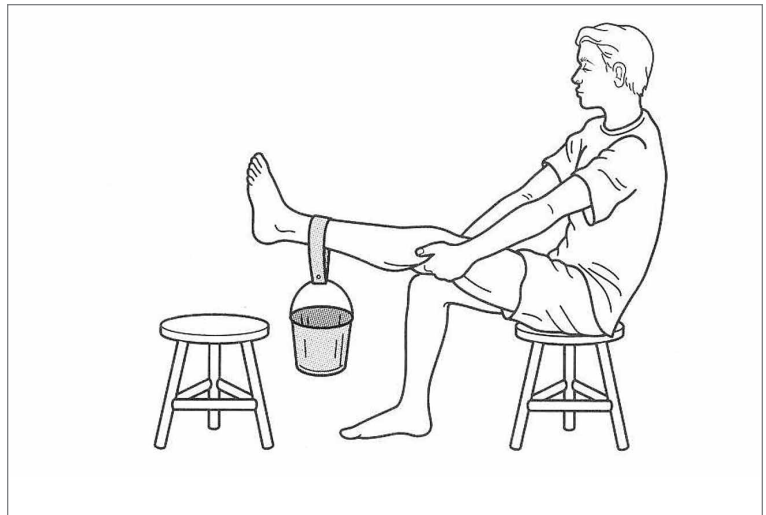

Figure 6. Simple home technique for isometric progressive resistive quadriceps exercises with knee in full extension or straight-leg weight lifting.

Reprinted with permission from *Operative Orthopedics*.²⁸

ically predominant lateral facet." Using the tools we have described here, the clinician usually finds the cause(s) of this "functional lateralization." Four abnormalities—VMO deficiency, LR tightness, increased standardized Q angle, and hip abductor weakness—can cause functional lateralization either alone when severe or in combination when mild or moderate.

For a presumptive diagnosis of LPCS, initial treatment is nonoperative, and successful in about 90% of patients. It should be obvious that most patients with chronic anterior knee pain have quadriceps atrophy. Physical therapy should be specifically focused on quadriceps strengthening, with absolutely no stress placed on the patellofemoral joint in flexion initially, and on hip abductor strengthening. Progressive resistive isometric quadriceps exercises can be performed with a weight-bench technique (**Figures 5A-5D**).²⁶ These isometric progressive resistive quadriceps (DeHaven²⁷) exercises can also be performed with a simple straight-leg weight-lifting program at home (**Figure 6**).²⁸ The advantage of isometric quadriceps strengthening is that the knee is in full extension, the patella lies above the trochlea, and there is no patellofemoral joint movement or compression. A patient of average stature can gradually increase quadriceps strength to resist or lift about 20 lb. Progressive hip abductor strengthening can be done in physical therapy or at home using side-lying abductor exercises with ankle weights. DeHaven²⁷ exercises should be painless when done correctly, but contraindicated in patients

with patellar tendinitis, quadriceps tendinitis, TT apophysitis (Osgood-Schlatter's), and anterior fat pad (Hoffa's) syndrome. When appropriate, certain adjunctive modalities for reducing functional lateralization should be tried. Use of McConnell taping and patellar bracing to resist this lateralization can be very helpful. If symptoms persist despite the 20-lb quadriceps goal being achieved and adequate hip abductor strength being demonstrated in a normal step-down test, conservative management has failed. Review and reassessment of the remaining abnormal physical factors (tight LR, increased Q angle) will lead to logical choices in surgical management.

Chronic Subluxation of Patella

With the use of axial patellofemoral radiographs (Merchant views),²⁰ the clinician can determine if the "patella is well centered in the trochlear sulcus and stable" (an important part of the definition of LPCS). If the patient has no symptoms of recurrent instability or patellar dislocation, and these radiographs show a laterally subluxed patella (one not well centered in the trochlea), the diagnosis is most likely CSP, a moderate form of patellofemoral dysplasia (section II of the Table). In addition to the 4 abnormalities used in the diagnosis of LPCS (mentioned earlier), trochlear dysplasia also comes into play in the diagnosis of CSP. Just as the other abnormalities can vary from mild to severe, trochlear dysplasia can vary from mild (slightly shallow sulcus angle) to severe (flat or even convex sulcus angle). As the sulcus becomes shallower, the patella slides more laterally, increasing the likelihood of patellar dislocation.

As the patient with CSP gives no history of episodic patellar instability, treatment for CSP is almost identical to that for LPCS, with the primary focus on isometric quadriceps strengthening (DeHaven isometric exercises)²⁷ and hip abductor muscle strengthening. In the presence of CSP radiographically, it is important to use McConnell taping and/or patellar bracing during muscular strengthening. A patient who achieves 20-lb isometric quadriceps strength, demonstrates a normal step-down test, and is assumed to be asymptomatic can be allowed to return to sports activities with use of a patellar brace. The patient should be counseled that there is an increased risk for patellar dislocation because of this chronic subluxation and the shallower sulcus.

As in LPCS, CSP symptoms that persist after dynamic strength is regained may require surgical

intervention. The severity of identified abnormal factors (tight LR, increased Q angle, trochlear dysplasia) guides the surgeon in selecting appropriate corrective technique(s).

Recurrent Dislocation of Patella

Admittedly, given the number and subtlety of abnormal factors, the diagnosis of LPCS as a cause of patellofemoral pain can be challenging. However, RDP is at the opposite end of the spectrum. A history of prior patellar dislocation(s) almost always makes the diagnosis of RDP easier. The patient occasionally complains of a recurrent symptom, the knee "going out" or "giving way," indicating that the diagnosis might be RDP. By carefully asking what the patient was doing and what happened when the knee "went out," the clinician may be able to determine if the injury stemmed from sudden patellar pain causing reflex inhibition of the quadriceps or was a true dislocation. Both may be described as "going out" or "giving way."

Assessment for the same 7 abnormalities helps establish the diagnosis, a logical treatment plan, and a guide for indicated surgery. The diagnostic focus is MPFL laxity and trochlear dysplasia. Prior lateral dislocation of the patella almost always requires rupture of the normal MPFL. The infrequent exception is a patient with hyper-elasticity of the skin and multiple joints (Ehlers-Danlos syndrome). Trochlear dysplasia is a significant risk factor for patellar dislocation. If the trochlea is normal and there is no MPFL laxity, the diagnosis of RDP should be questioned.

If surgery is indicated, the surgeon uses a list of the patient's abnormalities and their severity as a guide in selecting reconstructive techniques. The more abnormalities found and the greater the severity of each, the more techniques are needed to achieve success. Preoperative exercises help speed postoperative recovery by addressing quadriceps and hip abductor weakness. In addition, an active exercise program gives the surgeon insight into the patient's desire for and commitment to recovery. Other physical abnormalities to be considered in preoperative planning include MPFL laxity, LR tightness, increased Q angle, patella alta, and trochlear dysplasia.

Surgical tips: 1. When releasing the LR, never cut the vastus lateralis tendon, as this has a high likelihood of causing iatrogenic medial patellar subluxation.²⁹ 2. When medializing the TT, consider compensating for a shallow trochlea by "over-correcting" the Q angle to 5° to 10° measured with a surgical goniometer intraoperatively.

Summary

Basing clinical classification of disorders on etiology is a simple and effective way to diagnose common patellofemoral conditions. Identifying and rating the severity of patellofemoral dysplasia, using 7 commonly found physical abnormalities, guide the physician to a proper diagnosis and down logical treatment pathways. These principles should be incorporated into the routine evaluation of patellofemoral disorders to optimize diagnosis, formulate a treatment plan, and improve patient outcomes. After all, this is what our patients are asking us to do: *Try to find what's wrong, and then try to fix it!*

Dr. Merchant is Clinical Professor Emeritus, Department of Orthopedic Surgery, Stanford University School of Medicine, Stanford, California. Dr. Fulkerson is an Orthopedic Surgeon, Orthopedic Associates of Hartford, Hartford, Connecticut; Clinical Professor, Department of Orthopedic Surgery, University of Connecticut School of Medicine, Farmington, Connecticut; and President, The Patellofemoral Foundation, Farmington, Connecticut. Dr. Leadbetter is a former Adjunct Clinical Assistant Professor, Uniformed Services University of the Health Sciences, Bethesda, Maryland.

Address correspondence to: Alan C. Merchant, MD, MS, (email, kneemd@sbcglobal.net).

Am J Orthop. 2017;46(2):68-75. Copyright Frontline Medical Communications Inc. 2017. All rights reserved.

References

- Merchant AC. Classification of patellofemoral disorders. *Arthroscopy.* 1988;4(4):235-240.
- Merchant AC. Patellofemoral disorders: biomechanics, diagnosis, and nonoperative treatment. In: McGinty JB, Caspari RB, Jackson RW, Poehling GG, eds. *Operative Arthroscopy.* New York, NY: Raven Press; 1991:261-275.
- Dye SF. The knee as a biologic transmission with an envelope of function: a theory. *Clin Orthop Relat Res.* 1996;(325): 10-18.
- Merchant AC. A philosophy of the patellofemoral joint: a logical clinical approach. In: Sanchis-Alfonso V, ed. *Anterior Knee Pain and Patellar Instability.* 2nd ed. London, England: Springer; 2011:519-530.
- Jan MH, Lin DH, Lin JJ, Lin CH, Cheng CK, Lin YF. Differences in sonographic characteristics of the vastus medialis obliquus between patients with patellofemoral pain syndrome and healthy adults. *Am J Sports Med.* 2009;37(9):1743-1749.
- Pattyn E, Verdonk P, Steyaert A, et al. Vastus medialis obliquus atrophy: does it exist in patellofemoral pain syndrome? *Am J Sports Med.* 2011;39(7):1450-1455.
- Brattström H. Shape of the intercondylar groove normally and in recurrent dislocation of the patella. A clinical and x-ray anatomical investigation. *Acta Orthop Scand Suppl.* 1964;68:1-147.
- Roux D. Luxation habituelle de la rotule: traitement opératoire. *Rev Chir Orthop Reparatrice Appar Mot.* 1888;8: 682-689.
- Post WR. Clinical evaluation of patients with patellofemoral disorders. *Arthroscopy.* 1999;15(8):841-851.
- Grelsamer RP, Dubey A, Weinstein CH. Men and women have similar Q angles: a clinical and trigonometric evaluation. *J Bone Joint Surg Br.* 2005;87(11):1498-1501.
- Skellely N, Friedman M, McGinnis M, Smith C, Hillen T, Matava M. Inter- and intraobserver reliability in the MRI measurement of the tibial tubercle-trochlear groove distance and trochlea dysplasia. *Am J Sports Med.* 2015;43(4):873-878.
- Tensho K, Akaoka Y, Shimodaira H, et al. What components comprise the measurement of the tibial tuberosity-trochlear groove distance in a patellar dislocation population? *J Bone Joint Surg Am.* 2015;97(17):1441-1448.
- Camp CL, Heidenreich MJ, Dahm DL, Stuart MJ, Levy BA, Krych AJ. Individualizing the tibial tubercle-trochlear groove distance: patellar instability ratios that predict recurrent instability. *Am J Sports Med.* 2016;44(2):393-399.
- Ridley TJ, Hinckel BB, Kruckeberg BM, Agel J, Arendt EA. Anatomical patella instability risk factors on MRI show sensitivity without specificity in patients with patellofemoral instability: a systematic review. *JISAKOS.* 2016;1(3):141-152.
- James SL, Bates BT, Osternig LR. Injuries to runners. *Am J Sports Med.* 1978;6(2):40-50.
- Powers CM, Souza RB, Fulkerson JP. Patellofemoral joint. In: Magee DJ, Zachazewski JE, Quillen WS, eds. *Pathology and Intervention in Musculoskeletal Rehabilitation.* St. Louis, MO: Saunders Elsevier; 2008:601-636.
- Khayambashi K, Mohammadkhani Z, Ghaznavi K, Lyle MA, Powers CM. The effects of isolated hip abductor and external rotator muscle strengthening on pain, health status, and strength in females with patellofemoral pain: a randomized controlled trial. *J Orthop Sports Phys Ther.* 2012;42(1):22-29.
- Berg EE, Mason SL, Lucas MJ. Patellar height ratios. A comparison of four measurement methods. *Am J Sports Med.* 1996;24(2):218-221.
- Senavongse V, Amis AA. The effects of articular, retinacular, or muscular deficiencies on patellofemoral joint stability: a biomechanical study in vitro. *J Bone Joint Surg Br.* 2005;87(4):577-582.
- Merchant AC, Mercer RL, Jacobsen RH, Cool CR. Roentgenographic analysis of patellofemoral congruence. *J Bone Joint Surg Am.* 1974;56(7):1391-1396.
- Dejour H, Neyret P, Walch G. Factors in patellar instability. In: Aichroth PM, Cannon WD Jr, Patel DV, eds. *Knee Surgery: Current Practice.* London, England: Martin Dunitz; 1992.
- Davies AP, Costa ML, Shepstone L, Glasgow MM, Donell S. The sulcus angle and malalignment of the extensor mechanism of the knee. *J Bone Joint Surg Br.* 2000;82(8):1162-1166.
- Aglietti P, Insall JN, Cerulli G. Patellar pain and incongruence. I: measurements of incongruence. *Clin Orthop Relat Res.* 1983;(176):217-224.
- Ficat P, Ficat C, Baillieux A. External hypertension syndrome of the patella. Its significance in the recognition of arthrosis [in French]. *Rev Chir Orthop Reparatrice Appar Mot.* 1975;61(1):39-59.
- Ficat P, Hungerford DS. *Disorders of the Patellofemoral Joint.* Baltimore, MD: Williams & Wilkins; 1977.
- Merchant AC. The lateral compression syndrome. In: Fox JM, Del Pizzo W, eds. *The Patellofemoral Joint.* New York, NY: McGraw-Hill; 1993:157-175.
- DeHaven KE, Dolan WA, Mayer PJ. Chondromalacia patellae in athletes. Clinical presentation and conservative management. *Am J Sports Med.* 1979;7(1):5-11.
- Merchant AC. Patellofemoral joint disorders. In: Chapman MW, ed. *Operative Orthopedics.* Vol 3. Philadelphia, PA: Lippincott; 1988:2321-2366.
- Sanchis-Alfonso V, Merchant AC. Iatrogenic medial patellar instability: an avoidable injury. *Arthroscopy.* 2015;31(8):1628-1632.