

# A Rare Case of Spontaneous Fusion of the Knee

Ola S. Ahmed, MB BCh BAO, and James P. Cashman, MB BCh, FRCS

## Abstract

To our knowledge, this article is the first report of a case of spontaneous and progressive bony fusion of a knee joint without a prior diagnosis of inflammatory or septic arthritis or surgical arthrodesis.

Spontaneous knee fusion is an unusual and rarely reported phenomenon. Progressive stiffness is commonly experienced by patients with arthritis. However, most patients maintain some range of knee motion, which may be enhanced with medical treatment, rehabilitation with physiotherapy, and ambulation devices. To our knowledge, this article is the first report of a case of spontaneous and progressive bony fusion of a knee joint without a prior diagnosis of inflammatory or septic arthritis or surgical arthrodesis. The patient provided written informed consent for print and electronic publication of this case report.

## Case Report

In 2015, a 51-year-old woman presented to the orthopedics department with a 13-year history of complete loss of left knee flexion. She denied a history of trauma to or surgical intervention for the knee and denied a medical history of inflammatory or septic arthritis.

On initial referral to the department, in 2002, the patient, age 38 years at the time, had a 1-year history of progressive left knee stiffness and reduced range of motion (ROM). At the time, she recalled injuring the knee during an aerobics class 2 months prior. A physiotherapy trial (ROM actively and passively assessed 10°-90°) failed. All movement was painful, and 2 crutches were needed for ambulation. The patient was treated nonoperatively with analgesia and was advised to return to physiotherapy. Plain radiographs showed a small effusion but no

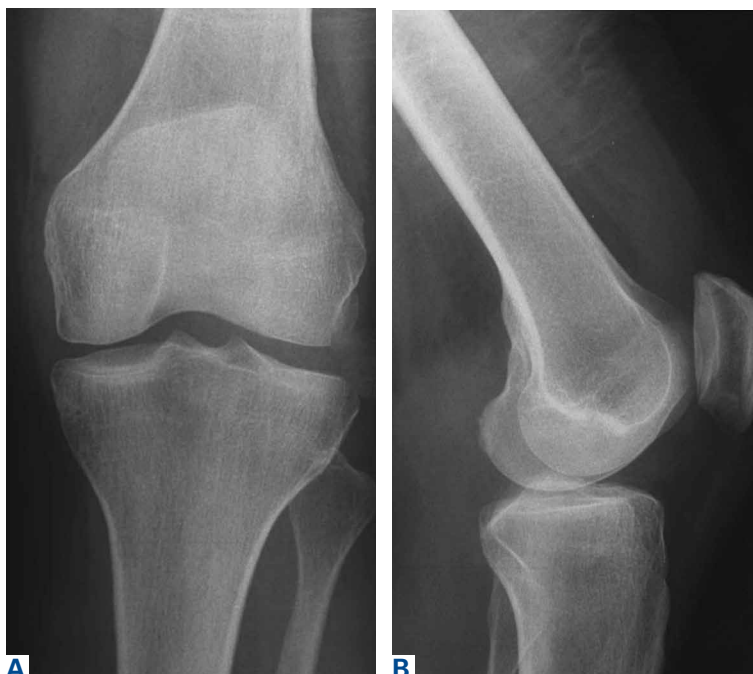

Figure 1. (A) Anteroposterior and (B) lateral radiographs of normal left knee, April 2002.

bony abnormalities or fractures (Figures 1A, 1B). Bone scan showed increased uptake in the joint, and immediate blood pool scans showed increased blood flow (Figures 2A, 2B). All inflammatory markers were within normal ranges: white blood cell

## Take-Home Points

- Post-infectious or post-inflammatory pathological knee arthrodesis is one of the most challenging complications in orthopedics.
- It can result in significant patient distress with some struggling to maintain any range of motion for functionality.
- TKA for the correction of knee ankylosis is an option, but not without significant morbidity and failure rates.

**Authors' Disclosure Statement:** The authors report no actual or potential conflict of interest in relation to this article.

count,  $7.71 \times 10^9/L$ , erythrocyte sedimentation rate, 16 mm/hr; and C-reactive protein level,  $<1$  nmol/L.

Four months after the initial referral, the patient returned to the outpatient department with persistent knee pain and ROM of  $5^\circ$  to  $20^\circ$ . A repeat radiograph showed extensive left knee joint destruction, cortical irregularity, and narrowing of the joint space (**Figures 3A, 3B**). Magnetic resonance imaging showed soft-tissue swelling with knee joint chondrolysis (**Figure 4**). At the time, the work-

ing diagnosis was an inflammatory phenomenon, and the plan was to perform an arthroscopy and biopsies, but the patient did not follow-up.

At the latest presentation (2015), the patient had a painless fixed extension deformity of the left knee joint and poor quality of life and wanted surgical intervention. Plain radiographs showed extensive left knee joint destruction and fusion (**Figures 5A, 5B**).

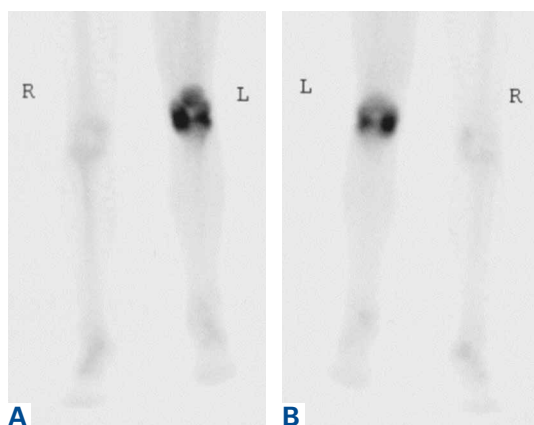
## Discussion

We have reported a rare case of spontaneous knee fusion in a middle-aged patient with no significant predisposing factors and no clear diagnosis. Serologic results were normal and not significant, but imaging was highly suggestive of an inflammatory process and provided a probable diagnosis of an underlying inflammatory condition and/or infection.

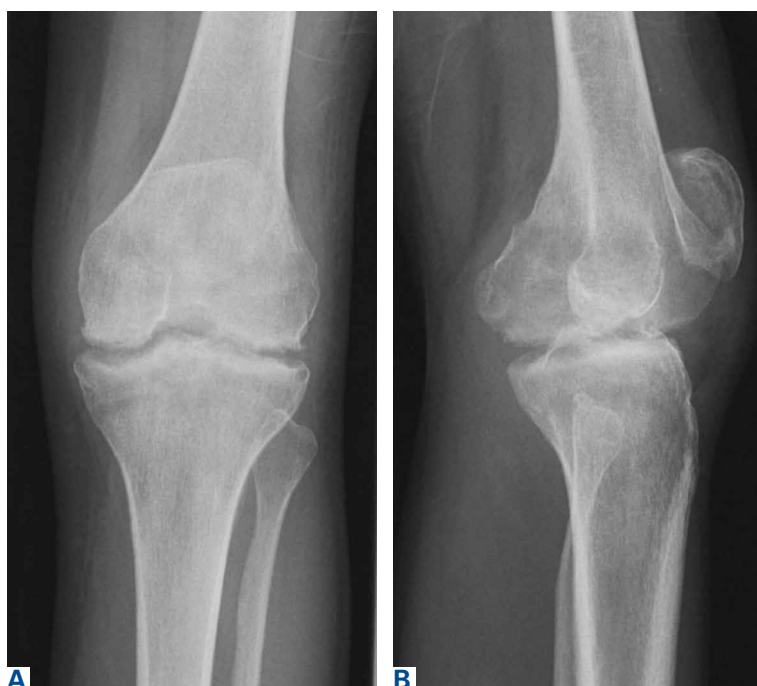In the literature, there are no other reports of similar cases of spontaneous knee joint fusion, though there are some rare cases of the phenomenon in other joints. In 2005, Budoff and Lichtman<sup>1</sup> reported a case of spontaneous wrist fusion in an 18-year-old patient with a background of Kienböck disease, which may have predisposed the patient to an underlying synovitis progressing to autofusion of the joint. In 2014, Lui<sup>2</sup> described the case of a 64-year-old woman with spontaneous subtalar fusion complicating a subtalar arthroereisis. Although an extensive literature review on the topic is difficult owing to the rarity of the condition, these few cases, unlike our case, appear to describe a predisposing factor or inciting event.

The reversibility of knee arthrodesis remains an issue in our patient's case and in other cases, and total knee arthroplasty (TKA) may be the most obvious operative intervention. Cameron and Hu<sup>3</sup> reported 17 cases of knee fusion take-down with conversion to TKA, and Kim and colleagues<sup>4</sup> reported 16 TKAs performed after spontaneous osseous ankylosis and 14 performed after formal knee fusion take-down. Although functional improvements were found in both studies, complication rates were relatively high, at least 53%. Other authors have used TKAs in cases of knee ankylosis after infectious or inflammatory arthritis, but results were suboptimal and unpredictable, and complication rates were 27% and 53.3%.<sup>5,6</sup>

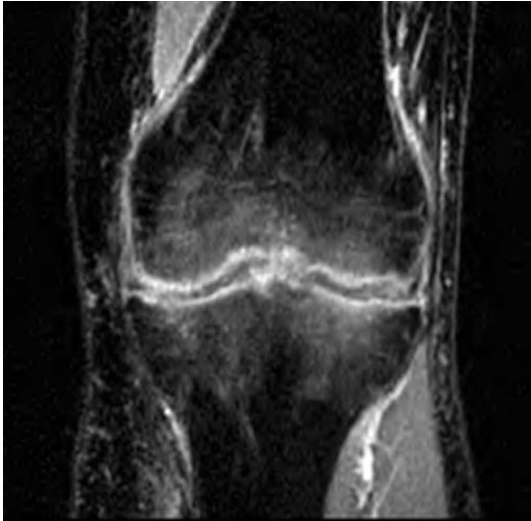
In this difficult scenario, our middle-aged patient's fixed extension deformity of the knee, likely the result of an idiopathic process, led to severe debilitation and poor quality of life. To perform a TKA in a 51-year-old patient is far from ideal. The



**Figure 2.** Technetium 99 bone scan of (A) anterior and (B) posterior right and left knee showing increased radiotracer uptake at the left knee indicative of increased bone activity at the knee, May 2002.



**Figure 3.** (A) Anteroposterior and (B) lateral radiographs of left knee show subchondral irregularity and sclerosis without joint-space narrowing, August 2002.



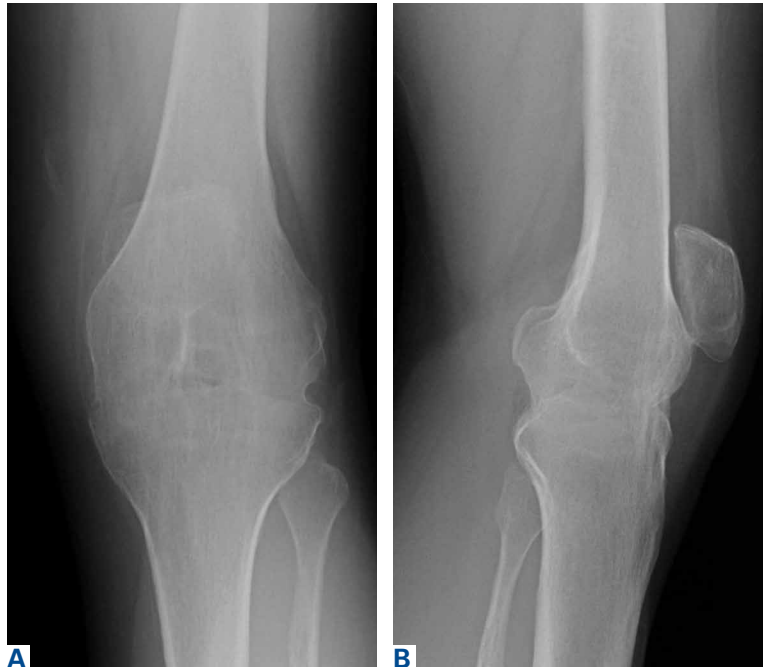**Figure 4.** Coronal short-T1 inversion recovery magnetic resonance imaging of the left knee shows a periarticular hyperintense signal adjacent to the joint in keeping with subchondral oedema, December 2002.

reversibility of formally fused and spontaneously fused knees is still in question, and, though there are reports of relatively satisfactory results, most operative options are fraught with complications.

Dr. Ahmed is a Specialist Registrar in Surgery, and Dr. Cashman is a Consultant Orthopaedic Surgeon, Department of Trauma and Orthopaedics, Mater Misericordiae University Hospital, Dublin, Ireland.

Address correspondence to: Ola S. Ahmed, MB BCH BAO, Department of Trauma and Orthopaedics, Mater Misericordiae University Hospital, 7 Eccles St, Dublin 7, Dublin, Ireland (tel, +353-1-803-2000; email, olaahmed@rcsi.ie).

*Am J Orthop.* 2017;46(2):E83-E85. Copyright Frontline Medical Communications Inc. 2017. All rights reserved.



**Figure 5.** (A) Anteroposterior and (B) lateral radiographs show ankylosed left knee in extended position with intact patellofemoral joint, February 2015.

## References

1. Budoff JE, Lichtman DM. Spontaneous wrist fusion: an unusual complication of Kienböck's disease. *J Hand Surg Am.* 2005;30(1):59-64.
2. Lui TH. Spontaneous subtalar fusion: an irreversible complication of subtalar arthroereisis. *J Foot Ankle Surg.* 2014;53(5):652-656.
3. Cameron HU, Hu C. Results of total knee arthroplasty following takedown of formal knee fusion. *J Arthroplasty.* 1996;11(6):732-737.
4. Kim YH, Kim JS, Cho SH. Total knee arthroplasty after spontaneous osseous ankylosis and takedown of formal knee fusion. *J Arthroplasty.* 2000;15(4):453-460.
5. Rajgopal A, Ahuja N, Dolai B. Total knee arthroplasty in stiff and ankylosed knees. *J Arthroplasty.* 2005;20(5):585-590.
6. Kim YH, Cho SH, Kim JS. Total knee arthroplasty in bony ankylosis in gross flexion. *J Bone Joint Surg Br.* 1999;81(2):296-300.