

Internal Carotid Artery Dissection After Indirect Blunt Cervical Trauma in an Ice Hockey Goaltender

Ryan M. Degen, MD, Matthew E. Fink, MD, Lisa Callahan, MD, Kenton Fibel, MD, Jim Ramsay, ATC, and Bryan T. Kelly, MD

Abstract

Internal carotid artery dissections are rare injuries that can result from both direct cervical trauma and indirect trauma causing sudden cervical hyperextension. Depending on the magnitude of the dissection, clinical presentation ranges from neurologic symptoms, such as Horner syndrome, to relatively mild but persistent headache symptoms, as in the case reported in this article. High clinical suspicion with subsequent neuroimaging is recommended in similar clinical scenarios. Our patient, an ice hockey goaltender, was conservatively treated with rest and serial neuroimaging studies to ensure resolution of the dissection. Eight weeks later, he returned to athletic competition with resolved symptoms and radiologically improved arterial stenosis.

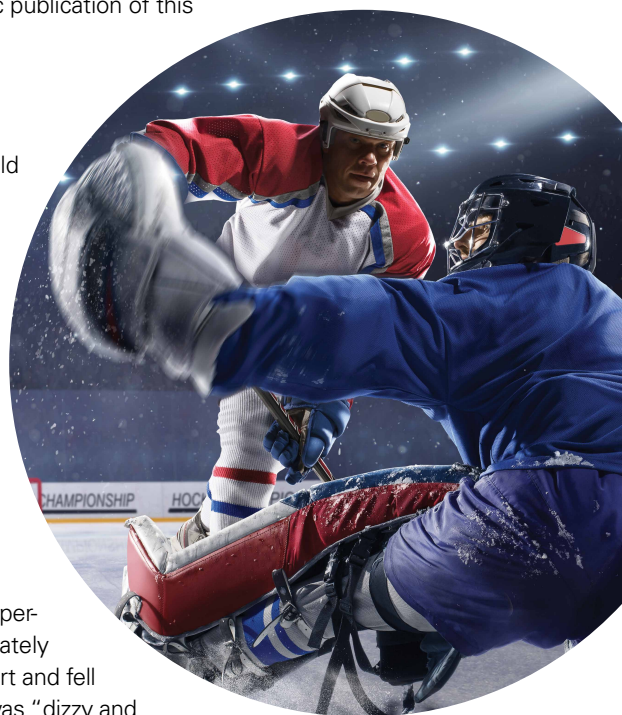Cervical artery dissection (CAD) is an uncommon but potentially life-threatening condition that accounts for a high proportion of ischemic strokes in patients under the age of 45 years.¹⁻⁴ The extracranial internal carotid arteries (ICAs) and vertebral arteries are most commonly involved; dissections can occur after either direct trauma to the neck, or indirect trauma resulting in acute hyperextension or hyperflexion.⁴⁻⁷ ICA dissection can be difficult to diagnose because of the varying symptomatology. Clinical presentation depends on stenosis location, degree of luminal narrowing, and presence or absence of ischemic stroke. Neurologic symptoms may be delayed, and misdiagnosis of an isolated soft-tissue con-

tusion, whiplash, can be made in the setting of indirect cervical trauma.

Although this entity is well described in the literature,^{2,3,5,8} there are few reported cases of injuries sustained during high-intensity athletic competition. In this case report, we describe the symptoms, physical examination findings, diagnostic imaging results, and treatment of a young male athlete who presented with delayed-onset symptoms of ICA dissection resulting from indirect cervical trauma sustained during an ice hockey game. We discuss the importance of a high level of clinical suspicion in the diagnosis of neck injuries sustained during athletic competition, as well as the need for early vascular imaging for diagnosis. The patient provided written informed consent for print and electronic publication of this case report.

Case Report

The patient was a right-handed 32-year-old professional hockey goaltender. Four days before diagnosis, his goaltending mask and attached neck-protector were inadvertently lifted by another player's stick just as a puck traveling at high speed struck him in the neck, to the right of the larynx, causing acute neck hyperextension. He immediately experienced discomfort and fell to the ice, saying he was "dizzy and



Authors' Disclosure Statement: The authors report no actual or potential conflict of interest in relation to this article.

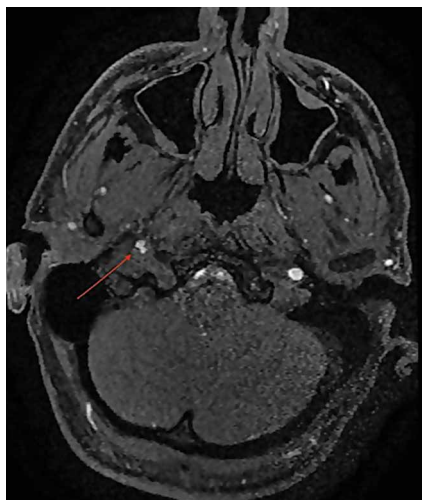


Figure 1. Stenosis (red arrow) of internal carotid artery secondary to intimal flap.

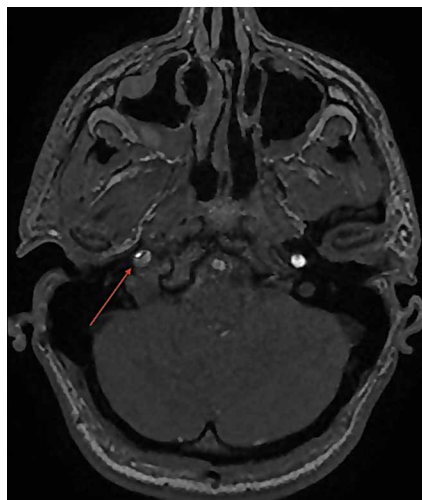


Figure 2. Progressive luminal stenosis (red arrow) after intramural hematoma formation.

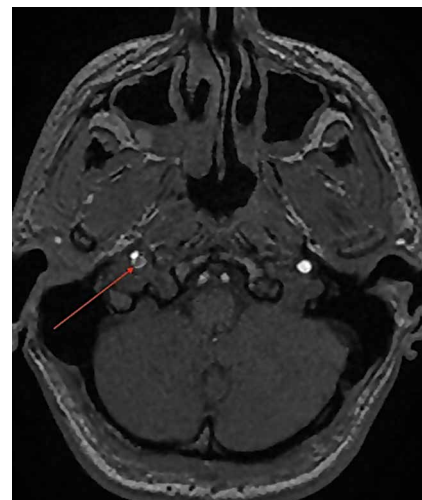


Figure 3. Pseudoaneurysm (red arrow) adjacent to carotid dissection.

light-headed.” Play was stopped, and medical personnel attended to him. His symptoms resolved, and he resumed play without any notable deficits. The next day, he noted discomfort at the impact site, but no additional symptoms, and received a presumptive diagnosis of cervical soft-tissue contusion. Continuing to participate in hockey that day, he did not develop any symptoms other than superficial cervical discomfort. However, the next morning, he presented complaining of severe right frontotemporal headache, which had persisted overnight. Orthopedic examination revealed palpable tenderness over the anterior cervical musculature, including the sternocleidomastoid

and strap muscles. There was no appreciable hematoma in the contused area. Cervical range of motion was otherwise preserved. Cervical spine examination, including dermatomal and myotomal examination, was normal, as was cranial nerve examination. However, given the headache intensity and the recency of the injury, the potential for vascular or neurologic injury was considered. A neurology consultation was obtained, and arrangements were made for advanced cross-sectional imaging.

On further evaluation, the patient denied loss of consciousness, seizure, vomiting, amnesia, visual disturbance, language or cognitive impairment, balance or

coordination difficulties, or any appreciable face or limb weakness. Review of systems was otherwise negative. Detailed neurologic examination did not reveal any cranial nerve deficits, and pupils were 3 mm, equal, and normally responsive to light and accommodation. Muscular tone and strength were symmetric and full in the upper and lower extremities. Gait, coordination, and response to vibration and temperature sensation were all preserved.

Magnetic resonance imaging of the head and neck was normal, but magnetic resonance angiography (MRA) of the neck showed a 1-cm-long region of the ICA, before piercing the petrous bone, with evidence of dissection. There was an associated intimal flap and about 50% luminal narrowing (**Figure 1**).

Given the normal neurologic examination, and no evidence of brain infarction or other neurovascular complications, the acute ICA dissection was managed with antiplatelet therapy using aspirin (325 mg/d). In addition, the patient was advised to refrain from strenuous physical activity and to present to the hospital immediately if symptoms worsened or any neurologic impairment developed. Follow-up and repeat MRA were planned to monitor healing progression.

Two weeks after injury, the patient returned for follow-up. His headache and neck pain had resolved. Physical examination findings were unchanged, and there were no notable neurologic deficits. Repeat MRA findings were essentially unchanged, except for slightly increased luminal stenosis, exceeding 50% (**Figure 2**), attributable to intramural hematoma formation. Adjacent to that

Take-Home Points

- ICA dissections may occur from direct or indirect trauma.
- Symptoms can be mild, including a persistent headache.
- High clinical suspicion is required for diagnosis when symptoms are mild.
- Neuroimaging is required for definitive diagnosis.
- Conservative management with serial imaging can yield successful outcomes.

was an associated pseudoaneurysm (Figure 3).

Continued antiplatelet therapy and relative rest were advised. At 4 weeks, imaging showed increased luminal diameter, with the intramural hematoma resolving (Figure 4).

At 6-week follow-up, the patient had no clinical symptoms and no recurrence of headaches. Neurologic findings were again negative. MRA showed interval improvement with nearly complete resolution of the stenosis, with a small area of resorbing hematoma within the former pseudoaneurysm (Figure 5).

Graduated return to activities was recommended, with cessation of activities and repeat assessment if symptoms returned. The patient successfully returned to his prior level of competition 8 weeks after injury. The Table summarizes the clinical events.

Discussion

In cases of direct (blunt) or indirect cervical trauma, CAD should be considered, as it carries a risk of potentially debilitating ischemic stroke in otherwise healthy young patients. Fortunately, CAD is rare; its annual incidence is 1 in 100,000, occurring in 0.08% to 1.2% of blunt trauma cases.⁹ However, CAD is the most common cause of stroke in young and middle-aged patients³; although it accounts for only 2% of all ischemic strokes, it causes 8% to 25% of ischemic strokes among patients under the age of 45 years.³ The ICA is particularly susceptible to injury, as it is mobile within the neck but relatively fixed at the base of the skull, where it pierces the petrous bone, making it susceptible to

strain.^{2,10} Participation in contact sports can result in direct trauma to the anterior neck, or in indirect trauma (acute hyperflexion, hyperextension, lateral flexion, or rotation) that may precipitate these injuries; therefore, CAD should be in the differential diagnosis for athletes who have had such an injury.

As symptoms of ICA dissection can vary depending on stenosis severity, diagnosis can be challenging. The classically associated triad of symptoms includes unilateral head, facial, or neck pain accompanied by partial Horner syndrome with progression to cerebral or retinal ischemia. However, these symptoms occur in less than a third of patients with ICA dissection.² Neck pain may occur secondary to blunt cervical trauma, consistent with a cervical soft-tissue contusion; however, it may have more severe implications and should be carefully monitored, particularly if accompanied by additional symptoms, such as headache.

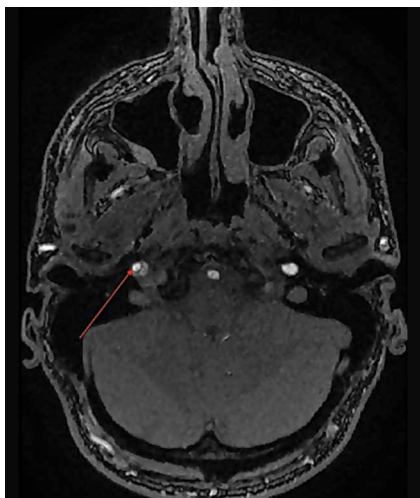


Figure 4. Resolving area of carotid artery stenosis (red arrow).

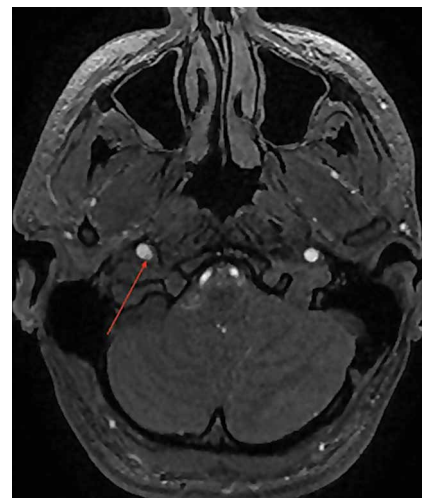


Figure 5. Resorbing intramural hematoma (red arrow).

Table. Summary of Clinical Events

Injury	Internal carotid artery dissection secondary to indirect cervical trauma (acute neck hyperextension/rotation)
Management	After symptom (persistent headache) presentation, patient underwent diagnostic magnetic resonance imaging of head and neck and magnetic resonance angiography (MRA) of neck. MRA showed internal carotid dissection and intimal flap with associated luminal narrowing.
Treatment	Treatment consisted of antiplatelet therapy and relative rest with serial MRA studies performed to monitor for progression and subsequent resolution of luminal narrowing.
Return-to-play program	Patient was asymptomatic for 4 weeks. Six weeks after injury, MRA showed resolution of luminal stenosis, and gradual return to sport program was initiated. Patient was monitored for recurrence of symptoms. After 2 weeks of progressive training, patient successfully returned to play.

Headaches, which are present in 44% to 69% of patients, are often unilateral and constant. Either headache or neck pain in isolation is relatively uncommon, occurring in <10% of cases,² though retrospective reviews of delayed-onset ICA dissection found atypical headache or neck pain in 100% of patients,¹¹ indicating that persistent symptoms should be further evaluated.

More commonly, patients present with neurologic symptoms, particularly Horner syndrome, which is caused by the disruption of the sympathetic nerve fibers adjacent to the ICA, resulting in ipsilateral ptosis and miosis. In addition, patients may present with cranial nerve palsies, most commonly involving cranial nerve XII (the hypoglossal nerve), resulting in tongue weakness and abnormal taste. These and other neurologic findings associated with retinal or cerebral ischemia should raise clinical suspicion for the injury and prompt computed tomography or MRA evaluation.

MRA has largely replaced conventional angiography for the diagnosis of CAD. As MRA is noninvasive, it allows for improved visualization of luminal narrowing and for evaluation of the arterial wall and intramural hematoma.² Because of the potential for devastating sequelae with missed or delayed diagnosis, several authors have become proponents of early aggressive screening for detection of these injuries.⁹ Postdiagnostic treatment depends on the presence of neurologic symptoms. Management is directed toward limiting neurologic deficits; anticoagulant or antiplatelet agents are used to prevent thromboembolic events. A randomized controlled trial and other studies have failed to find any appreciable difference in subsequent rates of stroke or associated complications with use of either class of medication.^{8,12} Conventionally, treatment is continued for 3 to 6 months, depending on clinical resolution. Endovascular or surgical intervention typically is reserved for extreme luminal narrowing, conditions that are preventing anticoagulation, an expanding area of dissection with a persistent pseudoaneurysm, and cases of failed medical management with subsequent ischemic stroke.²

The literature includes several case reports involving indirect trauma in recreational athletes. First, a 31-year-old woman sustained an ICA dissection secondary to a head injury that occurred during a soccer match; she presented with headache, altered sense of taste, and objective findings of ptosis and miosis consistent with Horner syndrome.¹³ Second, a 39-year-old man had an ICA

dissection after a snowboarding fall that caused neck hyperextension; he presented with periocular headache, ptosis, and miosis.⁶ Third, 3 people who participated in CrossFit training sustained ICA dissection.⁷ They presented with varying degrees of neurologic symptoms: ptosis and miosis; right-side upper extremity ataxia; and visual distortion and receptive aphasia. Our patient's ICA dissection resulted from indirect trauma that caused sudden hyperextension and lateral flexion in response to contact from a hockey puck. However, his case is unique in that symptoms onset was delayed, and there were no associated neurologic findings on clinical presentation. His case should raise awareness of this potential diagnosis, even in the absence of overt neurologic findings. In addition, the patient's return to sport at 8 weeks was facilitated by full clinical resolution of symptoms and thorough radiographic documentation of improved intramural narrowing. Finally, to our knowledge this is the first report of this injury in a professional athlete.

Conclusion

We have reported the case of a 32-year-old professional hockey goaltender who presented with isolated, persistent, worsening headache of delayed onset after ICA dissection. The ICA dissection resulted from indirect trauma, with reaction to a puck causing acute hyperextension and rotational injury. To our knowledge, this is the first report of a case of ICA dissection in an athlete, lacking neurologic examination findings that could aid in the diagnosis. The index of suspicion for CAD should be high after direct or indirect cervical trauma when patients present with unilateral neck pain or headache, even in the absence of neurologic findings, as stroke is a catastrophic but preventable complication.

Dr. Degen is an Orthopedic Sports Medicine Fellow, Dr. Callahan and Dr. Fibel are Primary Care Sports Medicine Physicians, Mr. Ramsay is Athletic Trainer, and Dr. Kelly is an Orthopedic Surgeon, Sports Medicine and Shoulder Service, Hospital for Special Surgery, New York, New York. Dr. Fink is Attending Neurologist, New York Presbyterian Hospital/Weill Cornell Medical Center, New York, New York

Address correspondence to: Bryan T. Kelly, MD, Sports Medicine and Shoulder Service, Hospital for Special Surgery, 535 E 70th St, New York, NY 10021 (tel, 212-606-1000, x80153; email, kellyb@hss.edu).

Am J Orthop. 2017;46(3):E139-E143. Copyright Frontline Medical Communications Inc. 2017. All rights reserved.

References

1. Mohan IV. Current optimal assessment and management of carotid and vertebral spontaneous and traumatic dissection. *Angiology*. 2014;65(4):274-283.
2. Patel RR, Adam R, Maldjian C, Lincoln CM, Yuen A, Arneja A. Cervical carotid artery dissection: current review of diagnosis and treatment. *Cardiol Rev*. 2012;20(3):145-152.
3. Biller J, Sacco RL, Albuquerque FC, et al; American Heart Association Stroke Council. Cervical arterial dissections and association with cervical manipulative therapy: a statement for healthcare professionals from the American Heart Association/American Stroke Association. *Stroke*. 2014;45(10):3155-3174.
4. Fukunaga N, Hanaoka M, Sato K. Asymptomatic common carotid artery dissection caused by blunt injury. *Emerg Med J*. 2011;28(1):50.
5. Chen J, Zhou X, Li C, Cheung BM. Risk of stroke due to spontaneous cervical artery dissection. *Intern Med*. 2013;52(19):2237-2240.
6. Kalantzis G, Georgalas I, Chang BY, Ong C, El-Hindy N. An unusual case of traumatic internal carotid artery dissection during snowboarding. *J Sports Sci Med*. 2014;13(2):451-453.
7. Lu A, Shen P, Lee P, et al. CrossFit-related cervical internal carotid artery dissection. *Emerg Radiol*. 2015;22(4):449-452.
8. CADISS Trial Investigators, Markus HS, Hayter E, Levi C, Feldman A, Venables G, Norris J. Antiplatelet treatment compared with anticoagulation treatment for cervical artery dissection (CADISS): a randomised trial. *Lancet Neurol*. 2015;14(4):361-367.
9. van Wessel KJ, Meijer JM, Leenen LP, van der Worp HB, Moll FL, de Borst GJ. Blunt traumatic carotid artery dissection still a pitfall? The rationale for aggressive screening. *Eur J Trauma Emerg Surg*. 2011;37(2):147-154.
10. Haneline M, Triano J. Cervical artery dissection. A comparison of highly dynamic mechanisms: manipulation versus motor vehicle collision. *J Manipulative Physiol Ther*. 2005;28(1):57-63.
11. Thomas LC, Rivett DA, Attia JR, Levi C. Risk factors and clinical presentation of cervical arterial dissection: preliminary results of a prospective case-control study. *J Orthop Sports Phys Ther*. 2015;45(7):503-511.
12. Lyrer P, Engelter S. Antithrombotic drugs for carotid artery dissection. *Cochrane Database Syst Rev*. 2010;(10):CD000255.
13. Creavin ST, Rice CM, Pollentine A, Cowburn P. Carotid artery dissection presenting with isolated headache and Horner syndrome after minor head injury. *Am J Emerg Med*. 2012;30(9):2103.e5-e7.