

# Multicenter Outcomes After Hip Arthroscopy: Epidemiology (MASH Study Group). What Are We Seeing in the Office, and Who Are We Choosing to Treat?

Benjamin R. Kivlan, PhD, PT, Shane J. Nho, MD, John J. Christoforetti, MD, Thomas J. Ellis, MD, Dean K. Matsuda, MD, John P. Salvo Jr, MD, Andrew B. Wolff, MD, Geoffrey S. Van Thiel, MD, MBA, Allston J. Stubbs, MD, MBA, and Dominic S. Carreira, MD

## Abstract

As the field of hip arthroscopy continues to grow rapidly, our understanding of the population of patients undergoing hip arthroscopy has led to improved diagnosis and management of hip joint pathologies. The Multicenter Arthroscopic Study of the Hip (MASH) Study Group conducts multicenter clinical studies in arthroscopic hip preservation surgery. Patients undergoing arthroscopic hip preservation surgery are enrolled in a large prospective longitudinal cohort at 10 separate sites nationwide by 10 fellowship-trained hip arthroscopists.

In this study, we collected epidemiologic data on the 1738 patients who enrolled between January 2014 and November 2016. These data include demographics, pathologic entities treated, patient-reported measures of disease, and surgical treatment preferences.

Our study results showed that patients

who elected hip arthroscopy were younger to middle-aged white females with pain primarily located in the groin region. Most had pain for at least 1 year, and it was commonly exacerbated by sitting and athletic activities. Patients reported clinically significant pain and functional limitation and a decrease in physical and mental health. It was not uncommon for patients to have undergone another, related surgery and nonoperative treatments, including intra-articular injection and/or physical therapy, before surgery. There was a high incidence of abnormal hip morphology suggestive of a cam lesion, but the incidence of arthritic changes on radiographs was relatively low. Labral tear was the most common diagnosis, and most often it was addressed with repair. Many patients underwent femoroplasty, acetabuloplasty, and chondroplasty in addition to labral repair.

Arthroscopic surgery of the hip has been growing over the past decade, with drastically increasing rates of arthroscopic hip procedures and increased education and interest

in orthopedic trainees.<sup>1-3</sup> The rise of this minimally invasive surgical technique may be attributed to expanding knowledge of surgical management of morphologic hip disorders as a means of hip

**Authors' Disclosure Statement:** Dr. Nho reports that he is Deputy Editor-in-Chief of *The American Journal of Orthopedics*; receives research support from Allosource, Arthrex, Athletico, DJ Orthopaedics, Linvatec, Miomed, Smith & Nephew, and Stryker; is a paid consultant to Ossur and Stryker; and receives publishing royalties and financial or material support from Springer. Dr. Christoforetti reports that he receives support from Arthrex and Breg. Dr. Ellis reports that he receives intellectual property royalties from Medacta and research support from Smith & Nephew and is a paid consultant to Stryker. Dr. Matsuda reports that he receives intellectual property royalties from Arthrocare, Zimmer Biomet, and Smith & Nephew and is a paid consultant to Orthopedics Overseas and Zimmer Biomet. Dr. Salvo reports that he is a paid consultant to Stryker. Dr. Wolff reports that he is a consultant to Stryker. Dr. Van Thiel reports that he is a paid consultant to Smith & Nephew and Zimmer Biomet, receives royalties from Zimmer Biomet, and has equity ownership in Zimmer Biomet. Dr. Stubbs reports that he is a consultant to Smith & Nephew; receives research support from Bauerfeind and departmental or divisional support from Arthrex, Mitek, and Smith & Nephew; and owns stock in Johnson & Johnson. Dr. Carreira reports that he is a paid consultant to Zimmer Biomet. Dr. Kivlan reports no actual or potential conflict of interest in relation to this article.

**Take-Home Points**

- MASH is a multicenter arthroscopic study of the hip that features a large prospective database of 10 separate institutions in the United States.
- The mean patient demographic was age 34.6 years, BMI 25.9 kg/m<sup>2</sup>, 62.8% females, and 97% white.
- Most patients had anterior or groin pain, but 17.6% had lateral hip pain, 13.8% had posterior hip pain, and 2.9% had low back or sacral pain.
- Patients typically had pain for about 1 year that was worsened with athletic activity as well as sitting.
- The most common surgical procedures that were performed included labral surgery in 64.7%, femoroplasty in 49.9%, acetabuloplasty in 33.3%, and chondroplasty in 31.1%

preservation. Many arthroscopic techniques have been developed to treat intra-articular hip joint pathologies, including femoroacetabular impingement (FAI), labral tears, and cartilage damage.<sup>4-11</sup>

These hip pathologies are widely recognized as painful limitations to activities of daily living and sports as well as early indicators of hip osteoarthritis.<sup>12,13</sup>

Limited evidence suggests that arthroscopic treatment of these intra-articular hip joint pathologies preserves the hip from osteoarthritis and progression to total hip arthroplasty.<sup>13-15</sup>

FAI is the most common etiology of pathologies related to arthroscopic surgery of the hip, including both labral tears and cartilage damage.<sup>4,7,14</sup> FAI is a morphologic bone disorder characterized by impingement of the femur and the acetabulum on flexion or rotation. The etiology of FAI is not

completely understood, but evidence suggests that stress to the proximal femoral physis during skeletal growth increases the risk of developing femoral head and neck deformations leading to cam-type FAI.<sup>15-17</sup> Understanding the characteristics of the patient population in which FAI occurs may shed light on the processes of intra-articular damage, such as labral tears and cartilage damage.

In the present study, we collected epidemiologic data, including demographics, pathologic entities treated, patient-reported measures of disease, and surgical treatment preferences, on a hip pathology population that elected to undergo arthroscopic surgery. These data are important in gaining a better understanding of the population and environment in which hip arthroscopy is performed across multiple centers throughout the United States and may help guide clinical practice and research to advance hip arthroscopy.

**Methods**

The Multicenter Arthroscopic Study of the Hip (MASH) Study Group conducts multicenter clinical studies in arthroscopic hip preservation surgery. Patients are enrolled in this large prospective longitudinal study at 10 sites nationwide by 10 fellowship-trained hip arthroscopists. Institutional Review Board approval was obtained from all institutions before patient enrollment. After enrollment, we collected comprehensive patient data, including demographics, common symptoms and their duration, provocative activities, patient-reported outcome measures (modified Harris Hip Score, International Hip Outcome Tool, 12-item Short Form Health Survey, visual analog scale pain rating, Hip Outcome Score), physical examination findings, imaging findings, diagnoses, surgical findings, and surgical procedures.

All study participants were patients undergoing arthroscopic hip surgery by one of the members of the MASH Study Group. Patients with incomplete preoperative information (needed for data analysis) were excluded. Data analysis was performed with SPSS Statistics Version 21.0 (SPSS Inc.) to obtain descriptive statistics of the quantitative data and frequencies of the nominal data.

**Results**

Between January 2014 and November 2016, we enrolled 1738 patients (647 male, 1091 female) in the study. **Table 1** lists the demographics of the population. Mean age was 34.6 years (range, 11-77 years); mean height, 67.1 inches (range, 54-180

**Table 1. Demographic Characteristics of Patients**

Demographic	Mean	Minimum	Maximum
Age, y	34.6	11	77
Height, in	67.1	54	180
Weight, lb	163.4	62	325
Body mass index, kg/m <sup>2</sup>	25.9	7	57.1
Sex, %			
Female	62.8		
Male	37.2		
Ethnicity, %			
Asian	0.3		
African-American	1.7		
Hispanic	1.0		
White	97		
Laterality			
Right	55		
Left	43		
Bilateral	2		
Smoker, %	1.2		
Worker's compensation, %	1.1		

inches); mean weight, 163.4 pounds (range, 62-325 pounds); and mean body mass index, 25.9 kg/m<sup>2</sup> (range, 7-57.1 kg/m<sup>2</sup>). Ninety-seven percent of the patients were white, 1.7% African-American, 1% Hispanic, and 0.30% Asian. In 55% of the cases, the right side was involved; in 43%, the left side; and in 2%, both sides. Only 1.2% of patients reported being a smoker, and 1.1% had services paid through worker's compensation claims.

Regarding symptom location, 40.9% of patients described pain in the groin region, 24.2% in the anterior hip region, and 11.3% in a C-sign distribution (**Table 2**). Lateral pain was reported by 17.6% of patients, and 13.8% of patients complained of pain in the posterior hip and buttock region. **Figure 1** shows that, before surgery, symptoms lasted more than 2 years in 38.4% of cases, between 1 and 2 years in 22%, between 4 and 12 months in 28.7%, and less than 4 months in 10.9%. **Figure 2** shows that symptoms were provoked during sports in 47.1% of cases, while sitting in 46.8%, while walking in 39.5%, while standing in 26.4%, and while climbing stairs in 19%. In addition, 22.3% of patients had a detectable limp, and catching, clicking, or locking occurred in 23.4% of patients.

**Table 3** lists the results of the patient-reported outcome measures. Mean visual analog scale pain rating was 51.8 (range, 0-100), mean modified Harris Hip Score was 53.8 (range, 0-91), mean Hip Outcome Score for activities of daily living was 62.3 (range, 5.9-100), mean Hip Outcome Score for sports was 39.4 (range, 0-100), and mean International Hip Outcome Tool was 33.9 (range, 0-99.3).

Of the 1738 patients enrolled, 424 (24.4%) had prior surgery related to current symptoms, 252 (14.5%) had 1 previous surgery, 120 (6.9%) had 2 previous surgeries, and 52 (3%) had 3 previous surgeries. Twenty-six patients (1.5%) had a previous revision hip arthroscopy on the ipsilateral side, and 14 (0.8%) had a previous hip arthroscopy on the contralateral side. Before surgery, 80% of patients received an intra-articular injection of corticosteroid and lidocaine. The peritrochanteric region was injected in 11.5% of patients and the psoas bursa in 2.2% (**Table 4**). Eighty percent of patients attended physical therapy for their hip before electing to have surgery.

Of the 1011 patients who had magnetic resonance imaging (MRI) performed, 943 (93.3%) had abnormal acetabular labrum findings, and 163 (17.1%) had acetabular articular damage. According to radiographic evaluation, 953 patients

Table 2. Location of Symptoms

Location	Primary, n	Secondary, n	Total, N	% of Total
Groin	503	209	712	40.9
Anterior	267	154	421	24.2
Lateral	131	175	306	17.6
Posterior	62	178	240	13.8
C sign	117	79	196	11.3
Back/sacroiliac	6	44	50	2.9
Lower abdomen	0	4	4	0.2

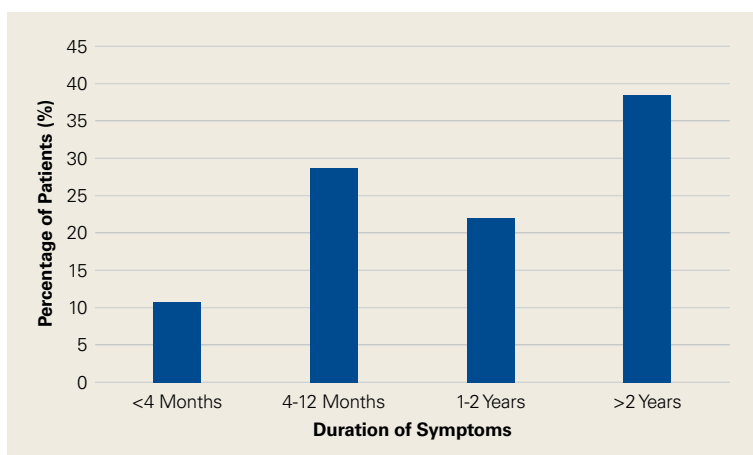


Figure 1. Duration of symptoms.

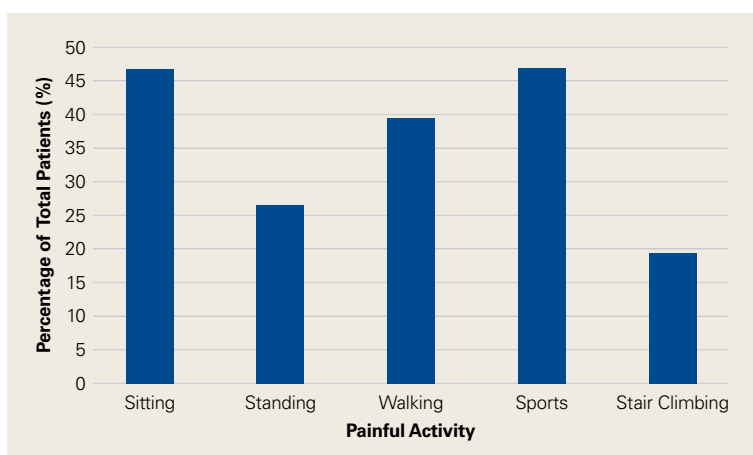


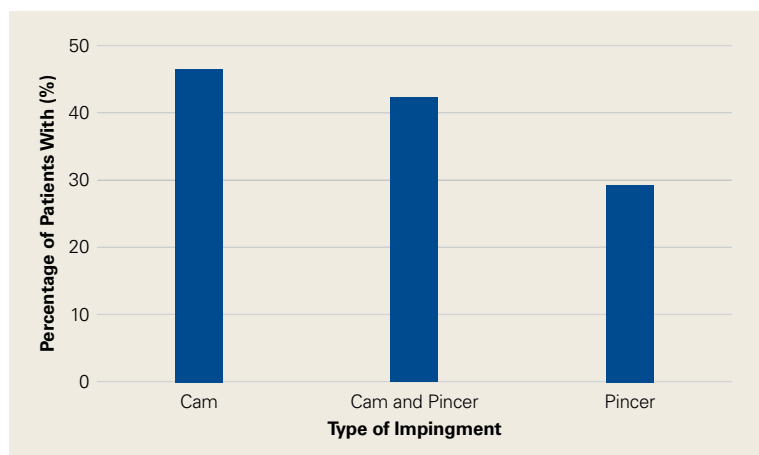
Figure 2. Provocation of symptoms during activity.

had abnormal hip joint morphology consistent with FAI. **Figure 3** shows the FAI classification percentages. The combination of cam-type and pincer-type impingement was noted in 42.6% of

**Table 3. Preoperative Patient-Reported Outcome Measures**

Outcome Measure	Mean	Minimum	Maximum
Modified Harris Hip Score			
ADLs	9.4	0	14
Gait	25.1	0	33
Pain	19.4	0	44
Total	53.8	0	91
Hip Outcome Score			
ADLs	62.3	5.9	100
Sports	39.4	0	100
12-item Short Form Health Survey			
Mental Health	51.5	18.8	71.3
Physical Health	35.3	14.5	62.2
International Hip Outcome Tool			
	33.9	0	99.3
Pain Visual Analog Scale			
	51.8	0	100

Abbreviation: ADL, activity of daily living.



**Figure 3.** Femoroacetabular impingement classification.

**Table 4. Prior Treatment**

	Total (N)	% of Total
Number of Prior Surgeries		
1	252	14.5%
2	120	6.9%
3	52	3.0%
Total	424	24.4%
Ipsilateral Hip Arthroscopy		
	26	1.5%
Contralateral Hip Arthroscopy		
	14	0.8%
Injections		
Intra-articular	1391	80%
Peritrochanteric	200	11.5%
Psoas bursa	38	2.2%

cases, isolated cam-type impingement in 47%, and isolated pincer-type impingement in 29.5% (61 of the 107 isolated pincer cases had positive radiographic signs of focal acetabular overcoverage). Conversely, 84 patients (4.8%) had signs of hip dysplasia (lateral center edge angle, <25°). Of all 1738 patients, 1602 (92.5%) had Tönnis grade 0 osteoarthritis on radiographic evaluation, 6.3% had Tönnis grade 1, and 1.5% had Tönnis grade 2. The lateral joint space was the most common location for arthrosis (2.1%), followed by the medial joint space (1.3%) and the central joint space (1.1%).

On clinical examination, 1079 patients (62.1%) had a positive anterior impingement sign. The subspine impingement sign was positive in 447 patients (25.7%), and the trochanteric pain sign was positive in 400 (23%). **Table 5** lists range-of-motion values for flexion and hip rotation from 90° of flexion. Loss of motion for hip flexion (<110°) occurred in 57.3% of patients, hip internal rotation of <15° in 42%, external rotation of <45° in 47.3%, and total hip rotation of <60° in 41.7%.

As seen in **Table 6**, labral pathology was the most common diagnosis (1426/1738 patients, 82%). Of the entire population, 354 (20.4%) had mild complexity labral tears, 288 (16.6%) had moderate complexity labral tears, and 130 (7.5%) had severe complexity labral tears. Of the 1738 cases total, 487 (28%) had labral bruising, and 167 (9.6%) had degenerative tears. Other diagnoses were 4 cases of septic arthritis (0.2%), 2 cases of avascular necrosis (0.1%), 36 cases of gluteus minimus/medius tears (2.1%), and 198 ligamentum teres tears (11.4%).

As seen in **Table 7**, the most common procedure was femoroplasty (867/1738, 49.9%). Other common procedures were synovectomy (833, 47.9%), acetabuloplasty (579, 33.3%), and acetabular chondroplasty (541, 31.1%). Of the 1124 labral tears, 847 (75.3%) were repaired, 154 (13.7%) were reconstructed, and 81 (7.2%) were débrided.

### Discussion

In this study, we collected epidemiologic data (demographics, pathologic entities treated, patient-reported measures of disease, surgical treatment preferences) from a large multicenter population of hip pathology patients who elected to undergo arthroscopic surgery. Our results showed these patients were most commonly younger to middle-aged white females with pain primarily in the groin region. Most had pain for at least 1 year, and it was commonly exacerbated by sitting and athletics.

Patients reported clinically significant pain and functional limitation, which showed evidence of affecting general physical and mental health. It was not uncommon for patients to have undergone another, related surgery and nonoperative treatments, including intra-articular injection and/or physical therapy, before surgery. There was a high incidence of abnormal hip morphology suggestive of a cam lesion, but the incidence of arthritic changes on radiographs was relatively low. Labral tear was the most common diagnosis, and most often it was addressed with repair. Many patients underwent femoroplasty, acetabuloplasty, and chondroplasty in addition to labral repair.

According to patient-reported outcome measures administered before surgery, 40% to 65% of patients seeking hip preservation surgery reported functional deficits and pain—which falls within the range of results from other multicenter studies on the epidemiology of FAI.<sup>18,19</sup> There was, however, a high amount of variability in individual scores on the functional and pain measures; some patients rated their functional ability very high. These findings were supported by the general health forms measuring global physical and mental health. Mean Physical Health and Mental Health scores on the 12-item Short Form Health Survey indicated that patients seeking hip preservation surgery thought their hip condition affected their general well-being. This finding is consistent with research on FAI,<sup>18</sup> hip arthritis,<sup>20</sup> and total hip arthroplasty.<sup>19</sup>

Our results further showed that hip arthroscopists commonly prescribed alternative treatment measures ahead of surgery. Before elective surgery, 80% of patients received an intra-articular injection, underwent physical therapy, or both. This could suggest a high failure rate for patients who chose conservative treatment approaches for hip-related pathology. However, our study was limited in that it may have included patients who had improved significantly with conservative measures and decided to forgo arthroscopic hip surgery. Although conservative treatment often is recommended in an effort to potentially avoid surgery, there is a lack of research evaluating the efficacy of nonoperative care.<sup>21,22</sup>

Analysis of diagnostic imaging and clinical examination findings revealed some unique characteristics of patients undergoing elective hip preservation surgery. MRI showed labral pathology in an overwhelming majority of these patients, but few had evidence of articular damage. Previous research has found a 67% rate of arthritic changes

Table 5. **Range of Motion of Hip Joint**

Range of Motion	Degrees		
	Mean	Minimum	Maximum
Flexion	107	30	140
Internal rotation	16.2	-20	70
External rotation	45.3	0	90
Total rotation	61.7	5	160
Hypomobility, %			
Flexion <110°		57.3	
Internal rotation <15°		42	
External rotation <45°		47.3	
Total rotation <60°		41.7	
Hypermobility, %			
Flexion >120°		8	
Internal rotation >35°		5	
External rotation >60°		8.7	
Total rotation >90°		5	

Table 6. **Intraoperative Diagnoses of Patients Undergoing Hip Preservation Surgery**

Diagnosis	n	%
Labral pathology	1426	82
Complex tear	772	68.7
Mild	354	20.4
Moderate	288	16.6
Severe	130	7.5
Labral bruising	487	28
Labral degeneration	167	9.6
Other		
Ligamentum teres tear	198	11.4
Gluteus minimus/medius tear	36	2.1
Septic arthritis	4	0.2
Avascular necrosis	2	0.1

on diagnostic imaging, but our rate was much lower (17%).<sup>23</sup> Radiograph evaluation confirmed the pattern: More than 90% of our patients had Tönnis grade 0 osteoarthritis. Tönnis grade 1 or 2 osteoarthritis is a predictor of acetabular cartilage degeneration,<sup>23</sup> and long-term studies have related these osteoarthritic changes to poorer hip arthroscopy outcomes.<sup>24</sup> Thus, the lower incidence of osteoarthritis in our study population may reflect current evidence-based practice and a contemporary approach to patient selection.

Table 7. **Surgical Procedures**

Procedure	n	%
Arthroscopic labral surgery	1124	64.7
Débridement	81	7.2
Débridement/repair	36	3.2
Débridement/reconstruction	2	0.2
Reconstruction	154	13.7
Reconstruction/repair	4	0.4
Repair	847	75.3
.....		
Other		
Femoroplasty	867	49.9
Synovectomy	833	47.9
Acetabuloplasty	579	33.3
Acetabular chondroplasty	541	31.1
Femoral chondroplasty	238	13.7
Ligamentum teres débridement	198	11.4
Irrigation and débridement	94	5.4
Iliotibial band release	85	4.9
Gluteus minimus/medius repair	36	2.1
Acetabular microfracture	31	1.8
Trochanteric bursectomy	28	1.6
Core decompression	5	0.3

Most of our patients had isolated cam-type FAI as opposed to pincer-type FAI or a combination of cam and pincer—contrary to research findings that combination cam–pincer FAI is most prevalent.<sup>25,26</sup> Our results are more consistent with more recent research findings of a higher incidence of isolated cam lesion, particularly in female patients, and combination cam–pincer in male patients.<sup>18,27,28</sup> Similar distributions of surgical procedures and diagnoses exist between the present study and other multicenter evaluations of the epidemiologic characteristics of patients with hip pathology.<sup>18</sup>

Our study had several limitations. First, the population consisted entirely of patients who sought evaluation by a hip arthroscopy specialist and underwent elective surgery. Therefore, the data cannot be applied to a more general orthopedic population or to patients who consult other medical specialists. Second, the population, which was 97% white and had small percentages of African-American, Latino, and Asian patients, lacked ethnic diversity. This finding is consistent with recent epidemiologic research in which ethnicity was identified as a factor in patterns of hip disease.<sup>13,29,30</sup> Access to specialists, however, was likely affected by multiple other factors. Fourth, the validity and the reliability of the imaging modalities used have been questioned.<sup>31-33</sup> There is controver-

sy regarding ideal imaging modalities for assessment of articular cartilage damage<sup>31,32</sup> and FAI. However, the modalities that we used to determine diagnoses in this study are well supported<sup>26</sup> and represent common practice patterns.

Dr. Kivlan is Assistant Professor, Duquesne University, Pittsburgh, Pennsylvania. Dr. Nho is Assistant Professor, Department of Orthopedic Surgery, Division of Sports Medicine, Hip Preservation Center, Rush University Medical Center, Chicago, Illinois. Dr. Christoforetti is Director, Center for Athletic Hip Injury, Allegheny Health Network, Pittsburgh, Pennsylvania, and Assistant Professor, Department of Orthopaedic Surgery, Drexel University College of Medicine, Philadelphia, Pennsylvania. Dr. Ellis is an Orthopedic Surgeon, Orthopedic One, Dublin, Ohio; Ohio Orthopedic Surgery Institute, Columbus, Ohio; and Dublin Methodist Hospital, Dublin, Ohio. Dr. Matsuda is Director of Hip Arthroscopy, DISC Sports and Spine Center, Marina Del Rey, California. Dr. Salvo is a Hip and Sports Medicine Surgeon, Rothman Institute, Philadelphia, Pennsylvania, and Clinical Associate Professor, Department of Orthopedic Surgery, Thomas Jefferson University Hospital, Philadelphia, Pennsylvania. Dr. Wolff is an Orthopedic Surgeon, Hip Preservation and Sports Medicine, Washington Orthopaedics and Sports Medicine, Washington, DC. Dr. Van Thiel is an Orthopedic Surgeon, Rockford Orthopedics, Rockford, Illinois, and Faculty, Department of Orthopedics, Rush University Medical Center, Chicago, Illinois. Dr. Stubbs is an Arthroscopic Surgeon, Wake Forest University, Winston-Salem, North Carolina. Dr. Carreira is an Orthopedic Surgeon, Tenet Healthcare Orthopedics and Sports Medicine, Fort Lauderdale, Florida, and Assistant Professor of Orthopedics, Nova Southeastern University, Fort Lauderdale, Florida.

Address correspondence to: Dominic S. Carreira, MD, Florida Institute of Orthopedic Surgical Specialists, 2307 W Broward Blvd, Suite 200, Fort Lauderdale, FL 33304 (tel, 954-465-9849; email, dcarreira@gmail.com).

*Am J Orthop.* 2017;46(1):35-41. Copyright Frontline Medical Communications Inc. 2017. All rights reserved.

**References**

1. Cvetanovich GL, Chalmers PN, Levy DM, et al. Hip arthroscopy surgical volume trends and 30-day postoperative complications. *Arthroscopy.* 2016;32(7):1286-1292.
2. Peters CL, Aoki SK, Erickson JA, Anderson LA, Anderson AE. Early experience with a comprehensive hip preservation service intended to improve clinical care, education, and academic productivity. *Clin Orthop Relat Res.* 2012;470(12):3446-3452.
3. Siebenrock KA, Peters CL. ABJS Carl T. Brighton workshop on hip preservation surgery: editorial comment. *Clin Orthop Relat Res.* 2012;470(12):3281-3283.
4. Parvizi J, Leunig M, Ganz R. Femoroacetabular impingement. *J Am Acad Orthop Surg.* 2007;15(9):561-570.
5. Poh SY, Hube R, Dienst M. Arthroscopic treatment of femoroacetabular pincer impingement. *Oper Orthop Traumatol.* 2015;27(6):536-552.
6. Javed A, O'Donnell JM. Arthroscopic femoral osteochondroplasty for cam femoroacetabular impingement in patients over

- 60 years of age. *J Bone Joint Surg Br.* 2011;93(3):326-331.
7. Groh MM, Herrera J. A comprehensive review of hip labral tears. *Curr Rev Musculoskelet Med.* 2009;2(2):105-117.
  8. Philippon MJ, Nepple JJ, Campbell KJ, et al. The hip fluid seal—part I: the effect of an acetabular labral tear, repair, resection, and reconstruction on hip fluid pressurization. *Knee Surg Sports Traumatol Arthrosc.* 2014;22(4):722-729.
  9. White BJ, Herzog MM. Labral reconstruction: when to perform and how. *Front Surg.* 2015;2:27.
  10. Yen YM, Kocher MS. Chondral lesions of the hip: microfracture and chondroplasty. *Sports Med Arthrosc.* 2010;18(2):83-89.
  11. Jordan MA, Van Thiel GS, Chahal J, Nho SJ. Operative treatment of chondral defects in the hip joint: a systematic review. *Curr Rev Musculoskelet Med.* 2012;5(3):244-253.
  12. Griffin DW, Kinnard MJ, Formby PM, McCabe MP, Anderson TD. Outcomes of hip arthroscopy in the older adult: a systematic review of the literature [published online October 18, 2016]. *Am J Sports Med.* doi:10.1177/0363546516667915.
  13. Ganz R, Leunig M, Leunig-Ganz K, Harris WH. The etiology of osteoarthritis of the hip. *Clin Orthop Relat Res.* 2008;466(2):264-272.
  14. Kaya M, Suzuki T, Emori M, Yamashita T. Hip morphology influences the pattern of articular cartilage damage. *Knee Surg Sports Traumatol Arthrosc.* 2016;24(6):2016-2023.
  15. Beck M, Leunig M, Parvizi J, Boutier V, Wyss D, Ganz R. Anterior femoroacetabular impingement: part II. Midterm results of surgical treatment. *Clin Orthop Relat Res.* 2004;(418):67-73.
  16. Byrd JT. Hip arthroscopy in athletes. *Oper Tech Sports Med.* 2005;13(1):24-36.
  17. Werner BC, Gaudiani MA, Ranawat AS. The etiology and arthroscopic surgical management of cam lesions. *Clin Sports Med.* 2016;35(3):391-404.
  18. Clohisy JC, Baca G, Beaulé PE, et al; ANCHOR Study Group. Descriptive epidemiology of femoroacetabular impingement: a North American cohort of patients undergoing surgery. *Am J Sports Med.* 2013;41(6):1348-1356.
  19. Shia DS, Clohisy JC, Schinsky MF, Martell JM, Maloney WJ. THA with highly cross-linked polyethylene in patients 50 years or younger. *Clin Orthop Relat Res.* 2009;467(8):2059-2065.
  20. Gandhi SK, Salmon JW, Zhao SZ, Lambert BL, Gore PR, Conrad K. Psychometric evaluation of the 12-item Short-Form Health Survey (SF-12) in osteoarthritis and rheumatoid arthritis clinical trials. *Clin Ther.* 2001;23(7):1080-1098.
  21. Loudon JK, Reiman MP. Conservative management of femoroacetabular impingement (FAI) in the long distance runner. *Phys Ther Sport.* 2014;15(2):82-90.
  22. Wall PD, Fernandez M, Griffin DR, Foster NE. Nonoperative treatment for femoroacetabular impingement: a systematic review of the literature. *PM R.* 2013;5(5):418-426.
  23. Nepple JJ, Carlisle JC, Nunley RM, Clohisy JC. Clinical and radiographic predictors of intra-articular hip disease in arthroscopy. *Am J Sports Med.* 2011;39(2):296-303.
  24. McCormick F, Nwachukwu BU, Alpaugh K, Martin SD. Predictors of hip arthroscopy outcomes for labral tears at minimum 2-year follow-up: the influence of age and arthritis. *Arthroscopy.* 2012;28(10):1359-1364.
  25. Beck M, Kalhor M, Leunig M, Ganz R. Hip morphology influences the pattern of damage to the acetabular cartilage: femoroacetabular impingement as a cause of early osteoarthritis of the hip. *J Bone Joint Surg Br.* 2005;87(7):1012-1018.
  26. Tannast M, Siebenrock KA, Anderson SE. Femoroacetabular impingement: radiographic diagnosis—what the radiologist should know. *AJR Am J Roentgenol.* 2007;188(6):1540-1552.
  27. Kapron AL, Peters CL, Aoki SK, et al. The prevalence of radiographic findings of structural hip deformities in female collegiate athletes. *Am J Sports Med.* 2015;43(6):1324-1330.
  28. Lee WY, Kang C, Hwang DS, Jeon JH, Zheng L. Descriptive epidemiology of symptomatic femoroacetabular impingement in young athlete: single center study. *Hip Pelvis.* 2016;28(1):29-34.
  29. Dudda M, Kim YJ, Zhang Y, et al. Morphologic differences between the hips of Chinese women and white women: could they account for the ethnic difference in the prevalence of hip osteoarthritis? *Arthritis Rheum.* 2011;63(10):2992-2999.
  30. Solomon L, Beighton P. Osteoarthritis of the hip and its relationship to pre-existing in an African population. *J Bone Joint Surg Br.* 1973;55(1):216-217.
  31. Keeney JA, Peelle MW, Jackson J, Rubin D, Maloney WJ, Clohisy JC. Magnetic resonance arthrography versus arthroscopy in the evaluation of articular hip pathology. *Clin Orthop Relat Res.* 2004;(429):163-169.
  32. Schmid MR, Nötzli HP, Zanetti M, Wyss TF, Hodler J. Cartilage lesions in the hip: diagnostic effectiveness of MR arthrography. *Radiology.* 2003;226(2):382-386.
  33. Chevillotte CJ, Ali MH, Trousdale RT, Pagnano MW. Variability in hip range of motion on clinical examination. *J Arthroplasty.* 2009;24(5):693-697.