

Plesiomonas shigelloides Periprosthetic Knee Infection After Consumption of Raw Oysters

Joshua W. Hustedt, MD, MHS, and Sarim Ahmed, MD

Abstract

Periprosthetic infections are a leading cause of morbidity after total joint arthroplasty. Common pathogens include *Staphylococcus aureus*, streptococcus, enterococcus, *Escherichia coli*, and *Pseudomonas aeruginosa*. However, there are many cases in which rare bacteria are isolated. This case report describes a periprosthetic knee infection caused by *Plesiomonas shigelloides*.

In the United States, *P shigelloides* and 2 other Vibrionaceae family members, *Vibrio vulnificus* and *Vibrio parahaemolyticus*, are most often contracted from eating raw oysters and shellfish. *P shigelloides* usually causes a self-limiting watery diarrhea, but in immunosuppressed people it can cause septicemia.

In this case report, a chemically and biologically immunosuppressed man consumed raw oysters and developed *P shigelloides* septicemia and acute periprosthetic knee infection that required surgical intervention.

infection with *P shigelloides* occurred after consumption of raw oysters.

P shigelloides is a gram-negative facultative anaerobic organism in the Vibrionaceae family,⁷ which also includes *Vibrio vulnificus* and *Vibrio parahaemolyticus*. *P shigelloides* is most well-known for causing diarrhea and septicemia in people who have consumed raw oysters or shellfish in the United States.^{8,9} Although *P shigelloides* infection is rare, there have been clinically significant outbreaks from contaminated water in Japan,¹⁰ consumption of freshwater fish in the Democratic Republic of the Congo,¹¹ and consumption of raw oysters in the United States.^{8,9} Children and immunosuppressed people are most susceptible to the disease, which most commonly manifests as self-limiting watery diarrhea, with septicemia only in advanced cases.¹²

There are very few reports of *P shigelloides* in the orthopedic population. In the medical literature, we found only 1 case of septic arthritis in a native knee; disease progression resulted in the patient's death.¹³

In this article, we report a case of *P shigelloides* septicemia that caused periprosthetic knee infection in a chemically and biologically immunosuppressed patient. The patient provided written informed consent for print and electronic publication of this case report.

Case Report

Out of concern about a periprosthetic knee infection, a 66-year-old man was transferred from a regional medical center to our tertiary referral center. The patient reported a 3-day history of significant knee pain, swelling, and erythema that started the day after he consumed raw oysters at a seafood bar. He was unable to bear weight on the right knee and remained at home 1 day before presenting to the regional medical center.

The patient had undergone elective right total

Periprosthetic infection is a leading cause of morbidity after total joint arthroplasty.¹ Despite advances in modern surgical practices, infection rates continue to range from 1% to 3% among all arthroplasty procedures performed in the United States.²⁻⁵ The most common causes of periprosthetic infection include *Staphylococcus aureus*, streptococcus, enterococcus, *Escherichia coli*, and *Pseudomonas aeruginosa*.⁶ However, many other pathogens that cause periprosthetic infection should be considered in the clinical setting. In this case report, periprosthetic knee

Authors' Disclosure Statement: The authors report no actual or potential conflict of interest in relation to this article.

knee arthroplasty 18 months earlier, without previous issue (Figures A, B), and had a medical history of type 2 diabetes mellitus, psoriatic arthritis, hypertension, hyperlipidemia, hypothyroidism, and benign prostatic hypertrophy. Medications included etanercept (a tumor necrosis factor inhibitor) and prednisone for psoriatic arthritis, sitagliptin, metformin, levothyroxine, lisinopril, rosuvastatin, and tamsulosin.

On presentation to our facility, the patient described pain in the right knee. Physical examination revealed swelling and erythema of the knee. Vital signs were within normal limits, with a temperature of 98.5°F. Laboratory work-up revealed white blood cell count of 17,700 with 79% neutrophils and 9% lymphocytes, serum C-reactive protein level of 270 mg/L, and erythrocyte sedimentation rate of 46 mm/h. Aspiration of the knee yielded about 100 mL of thick, brownish synovial fluid. Gram stain of the knee aspirate revealed gram-negative rods and many white blood cells. Nucleated cell count of the aspirate was 22,400 with 88% neutrophils. Blood cultures were obtained, and broad-spectrum antibiotics (vancomycin and ceftriaxone) were started in preparation for surgery.

Within 24 hours, the patient was taken for irrigation and débridement with polyethylene exchange of the right knee. Surgical exploration revealed brownish purulent fluid in the knee. The polyethylene insert was removed, and a complete synovectomy was performed for knee débridement. Nine liters of triple antibiotic (utilized bacitracin, polymyxin, and gentamicin) saline were used to copiously clean the metal surfaces of the implant, and a new polyethylene liner was inserted. Absorbable calcium sulfate antimicrobial beads, stimulant beads with 1 gram of vancomycin and 1.2 grams of tobramycin, were implanted both inside and over the knee capsule during closure.

Blood cultures, knee aspirate, and surgical cultures were all positive for *P shigelloides*. Of note, the patient did not describe having diarrhea, a symptom common in *P shigelloides* infection. After final cultures were received, the patient was placed on intravenous ceftriaxone and oral levofloxacin for 6 weeks. Three months later, he reported full return to activity and clearance of the infection.

Discussion

This case is a reminder that periprosthetic knee infection can occur from a variety of pathologic organisms and that obtaining a complete history is an important part of any diagnostic work-up. Al-

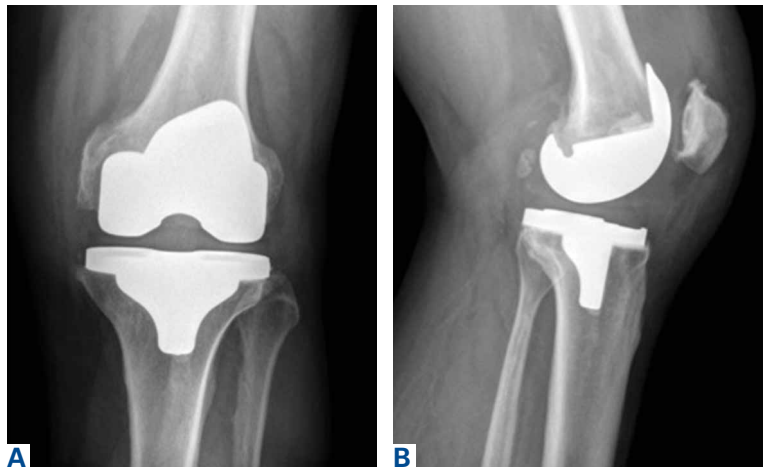


Figure. (A) Anteroposterior and (B) lateral radiographs of total knee prosthesis infected with *Plesiomonas shigelloides*.

though *P shigelloides* infection is rare, our patient had important historical findings that led to suspicion of Vibrionaceae infection: recent consumption of raw oysters, immunosuppression with etanercept and prednisone for psoriatic arthritis, and diabetes with hemoglobin A_{1c} of 9.9% and presenting blood sugar of 338 mg/dL. His positive blood cultures represented *P shigelloides* septicemia, which seeded the knee prosthesis and led to acute periprosthetic infection. To our knowledge, this is the first report of *P shigelloides* periprosthetic infection in the orthopedic literature. The only other reported case of *P shigelloides* septicemia leading to septic arthritis in a native knee occurred in a 68-year-old Australian man who had end-stage liver disease and eventually died from complications of the *P shigelloides* infection.¹³

Although *P shigelloides* infection is rare, outbreaks have occurred around the world.^{7,11,14} Infections are most commonly associated with consumption of raw shellfish or freshwater fish or with water contamination.¹² In the United States, the only described vector for disease has been consumption of raw oysters and shellfish—in particular, those harvested from the warm waters of the Gulf Coast.^{8,9} *P shigelloides* usually causes a self-limiting watery diarrhea. However, in children and immunosuppressed patients, *P shigelloides* can lead to

Take-Home Points

- History and physical examination are key in identifying possible etiologies of orthopedic infections.
- If identified in the acute setting, periprosthetic infections can successfully be treated with irrigation, débridement, and polyethylene liner exchange.
- Discussion with an interdisciplinary medical team, including infectious disease specialists, can aid in improved diagnosis and treatment of periprosthetic infections.

life-threatening septicemia.¹² In the United States, *P. shigelloides* cases often occur in the summer, likely related to the easy growth of the bacteria from shellfish in the Gulf Coast's warm water and mud.⁸ This predilection for summer infections has been documented around the world.¹⁵

Our patient reported eating raw oysters imported to the US Southwest from an unknown location. He likely was susceptible to *P. shigelloides* infection, as he was immunosuppressed with etanercept and prednisone. However, there were no traditional diarrheal symptoms. Case reports have described nondiarrheal symptoms in children and other immunosuppressed people.¹²

There is much to learn from this case report. Most important, it highlights the need to obtain a complete history and perform a thorough physical examination. Our patient's 2 key historical findings, immunosuppressive medication use and raw oys-

ter consumption, point strongly toward Vibrionaceae infection. Although a majority of periprosthetic infections are caused by common organisms, such as *Staphylococcus* and *Streptococcus* species, orthopedic clinicians should continue to expand their knowledge of periprosthetic infections, as many other pathogens can cause disease.

Dr. Hustedt is a Resident, Department of Orthopedics, and Dr. Ahmed is an Assistant Professor of Orthopedics, University of Arizona College of Medicine-Phoenix, Arizona.

Address correspondence to: Joshua W. Hustedt, MD, MHS, Department of Orthopedics, Banner University Medical Center, 1320 N 10th St, Suite A, Phoenix, AZ 85006 (tel, 602-839-3671; fax, 602-839-3788; email, joshua.hustedt@email.arizona.edu).

Am J Orthop. 2017;46(1):E32-E34. Copyright Frontline Medical Communications Inc. 2017. All rights reserved.

References

1. Parvizi J, Adeli B, Zmistowski B, Restrepo C, Greenwald AS. Management of periprosthetic joint infection: the current knowledge: AAOS exhibit selection. *J Bone Joint Surg Am.* 2012;94(14):e104.
2. Fehring TK, Odum S, Griffin WL, Mason JB, Nadaud M. Early failures in total knee arthroplasty. *Clin Orthop.* 2001;(392):315-318.
3. Kurtz SM, Lau E, Schmier J, Ong KL, Zhao K, Parvizi J. Infection burden for hip and knee arthroplasty in the United States. *J Arthroplasty.* 2008;23(7):984-991.
4. Clohisy JC, Calvert G, Tull F, McDonald D, Maloney WJ. Reasons for revision hip surgery: a retrospective review. *Clin Orthop.* 2004;(429):188-192.
5. Vessely MB, Whaley AL, Harmsen WS, Schleck CD, Berry DJ. The Chitranjan Ranawat Award: long-term survivorship and failure modes of 1000 cemented condylar total knee arthroplasties. *Clin Orthop.* 2006;(452):28-34.
6. Peel TN, Cheng AC, Buising KL, Choong PF. Microbiological aetiology, epidemiology, and clinical profile of prosthetic joint infections: are current antibiotic prophylaxis guidelines effective? *Antimicrob Agents Chemother.* 2012;56(5):2386-2391.
7. Wong TY, Tsui HY, So MK, et al. *Plesiomonas shigelloides* infection in Hong Kong: retrospective study of 167 laboratory-confirmed cases. *Hong Kong Med J.* 2000;6(4):375-380.
8. Holmberg SD, Wachsmuth IK, Hickman-Brenner FW, Blake PA, Farmer JJ 3rd. *Plesiomonas* enteric infections in the United States. *Ann Intern Med.* 1986;105(5):690-694.
9. Rutala VA, Sarubi FA Jr, Finch CS, McCormack JN, Steinkraus GE. Oyster-associated outbreak of diarrhoeal disease possibly caused by *Plesiomonas shigelloides*. *Lancet.* 1982;1(8274):739.
10. Tsukamoto T, Kinoshita Y, Shimada T, Sakazaki R. Two epidemics of diarrhoeal disease possibly caused by *Plesiomonas shigelloides*. *J Hyg (Lond).* 1978;80(2):275-280.
11. Van Damme LR, Vandepitte J. Frequent isolation of *Edwardsiella tarda* and *Plesiomonas shigelloides* from healthy Zairese freshwater fish: a possible source of sporadic diarrhea in the tropics. *Appl Environ Microbiol.* 1980;39(3):475-479.
12. Brenden RA, Miller MA, Janda JM. Clinical disease spectrum and pathogenic factors associated with *Plesiomonas shigelloides* infections in humans. *Rev Infect Dis.* 1988;10(2):303-316.
13. Gordon DL, Philpot CR, McGuire C. *Plesiomonas shigelloides* septic arthritis complicating rheumatoid arthritis. *Aust N Z J Med.* 1983;13(3):275-276.
14. Medema G, Schets C. Occurrence of *Plesiomonas shigelloides* in surface water: relationship with faecal pollution and trophic state. *Zentralbl Hyg Umweltmed.* 1993;194(4):398-404.
15. Huq MI, Islam MR. Microbiological & clinical studies in diarrhoea due to *Plesiomonas shigelloides*. *Indian J Med Res.* 1983;77:793-797.

This paper will be judged for the Resident Writer's Award.