

# Nontraumatic Knee Pain

## A Diagnostic & Treatment Guide

Carlton J. Covey, MD, FAAFP, Matthew K. Hawks, MD

Little has been written about nontraumatic nonarthritic knee pain in adults. This article fills that void with practical tips and an at-a-glance resource.

### PRACTICE RECOMMENDATIONS

- Consider radiography for a patient with patellofemoral pain syndrome if examination reveals an effusion, the patient is age 50 or older, or the condition does not improve after eight to 12 weeks of treatment. **C**
- Order plain radiography for all patients with patellofemoral instability to assess for osseous trauma/deformity; consider MRI if you suspect significant soft-tissue damage or the patient does not respond to conservative therapy. **C**
- Perform joint aspiration with synovial fluid analysis for patients with painful knee effusion and provide an orthopedic referral without delay when an infectious joint is suspected. **A**

#### Strength of recommendation (SOR)

- A** Good-quality patient-oriented evidence
- B** Inconsistent or limited-quality patient-oriented evidence
- C** Consensus, usual practice, opinion, disease-oriented evidence, case series

Jane, age 42, presents with right knee pain that she's had for about six months. She denies any trauma. Jane describes the pain as "vague and poorly localized" but worse with activity. She says she started a walking/running program nine months ago, when she was told she was overweight (BMI, 29). She has lost 10 pounds since then and hopes to lose more by continuing to exercise. Further review reveals that Jane has experienced increasing pain while ascending and descending stairs and that the pain is also exacerbated when she stands after prolonged sitting.

If Jane were your patient, what would you include in a physical examination, and how would you diagnose and treat her?

**K**nee pain is a common presentation in primary care. While traumatic knee pain is frequently addressed in the medical literature, little has been written about chronic nontraumatic nonarthritic knee pain such as Jane's. Thus, while physical exam tests often lead to the correct diagnosis for traumatic knee pain, there is limited information on the use of such tests to determine the etiology of chronic knee pain.

This review was developed to fill that gap. The pages that follow contain general guidance on the diagnosis and treatment of chronic nontraumatic knee pain. The conditions are presented anatomically—anterior, lateral, medial, or posterior—with common etiologies, history and physical exam findings, and diagnosis and treatment options for each (see Table, page 28).<sup>1-31</sup>

### ANTERIOR KNEE PAIN

#### Patellofemoral pain syndrome (PFPS)

The most common cause of anterior knee pain, PFPS is a complex entity with an etiology that has not been well described.<sup>2</sup> The quadriceps tendon, medial and lateral retinacula, iliotibial band

---

**Carlton J. Covey** and **Matthew K. Hawks** are with the Nellis Family Medicine Residency Program at Nellis Air Force Base in Nevada. Dr. Covey is also with the Uniformed Services University of the Health Sciences in Bethesda, Maryland. *The authors reported no potential conflict of interest relevant to this article. The opinions and assertions contained herein are the private views of the authors and are not to be construed as official or as reflecting the views of the US Air Force Medical Department or the US Air Force at large. This article originally appeared in The Journal of Family Practice (2014;63[12]:720-728).*

(ITB), vastus medialis and lateralis, and the insertion of the patellar tendon on the anterior tibial tubercle all play a role in proper tracking of the patellofemoral joint; an imbalance in any of these forces leads to abnormal patellar tracking over the femoral condyles, and pain ensues. PFPS can also be secondary to joint overload, in which excessive physical activity (eg, running, lunges, or squats) overloads the patellofemoral joint and causes pain.

Risk factors for PFPS include strength imbalances in the quadriceps, hamstring, and hip muscle groups, and increased training, such as running longer distances.<sup>4,32</sup> A recent review showed no relationship between an increased quadriceps (Q)-angle and PFPS, so that is no longer considered a major risk factor.<sup>5</sup>

**Diagnosis.** PFPS is a diagnosis of exclusion and is primarily based on history and physical exam. Anterior knee pain that is exacerbated when seated for long periods of time (the “theater sign”) or by descending stairs is a classic indication of PFPS.<sup>1</sup> Patients may complain of knee stiffness or “giving out” secondary to sharp knee pain and a sensation of popping or crepitus in the joint. Swelling is not a common finding.<sup>2</sup>

A recent meta-analysis revealed limited evidence for the use of any specific physical exam tests to diagnose PFPS. But pain during squatting and pain with a patellar tilt test were most consistent with a diagnosis of PFPS. (The patellar tilt test involves lifting the lateral edge of the patella superiorly while the patient lies supine with knee extended; pain with < 20° of lift suggests a tight lateral retinaculum). Conversely, the absence of pain during squatting or the absence of lateral retinacular pain helps rule it out.<sup>2</sup> A physical exam of the cruciate and collateral ligaments should be performed in a patient with a history of instability. Radiography is not needed for a diagnosis but may be considered if examination reveals an effusion, the patient is 50 or older, or no improvement occurs after eight to 12 weeks of treatment.<sup>33</sup>

**Treatment.** The most effective and strongly supported treatment for PFPS is a six-week physiotherapy program focusing on strengthening the quadriceps and hip muscles and stretching the quadriceps, ITB, hamstrings, and hip flexors.<sup>4,5</sup> There is limited information about the use of NSAIDs, but they can be considered for short-term management.<sup>2</sup>

**Patellar taping and bracing** have shown some promise as adjunct therapies for PFPS, although the data for both are nonconclusive. There is a paucity

of prospective randomized trials of patellar bracing, and a 2012 Cochrane review found limited evidence of its efficacy.<sup>34</sup> But a 2014 meta-analysis revealed moderate evidence in support of patellar taping early on to help decrease pain,<sup>6</sup> and a recent review suggests that it can be helpful in both the short and long term.<sup>7</sup>

Taping or bracing may be useful when combined with a tailored physical therapy program. Evidence for treatments such as biofeedback, chiropractic manipulation, and orthotics is limited, and they should be used only as adjunctive therapy.<sup>4</sup>

When you examine Jane, you find no swelling of the affected knee. You perform the tilt test, which elicits pain. Squatting causes some pain, as well. You diagnose PFPS and provide a referral for six weeks of physiotherapy.

### Patellofemoral instability (PFI)

PFI occurs when the patella disengages completely from the trochlear groove.<sup>11</sup> PFI’s etiology also relates to the complexity of the patellofemoral joint. Here, too, stability of the joint is achieved with a combination of soft-tissue and bony restraints. At full extension and early flexion of the knee, however, the mechanisms of stability are limited, resulting in increased instability. Other associated factors include Q-angle, lateral pull from a tight ITB, and opposing forces from the vastus lateralis and vastus medialis obliquus (VMO).<sup>8-10</sup>

**Risk factors for PFI.** The most common predisposing factors for PFI are trochlear dysplasia, patella alta, and lateralization of the tibial tuberosity or patella.<sup>10,11</sup> Older patients, predominately women, have an increased risk for PFI.<sup>9</sup> Patients usually have a history of patellar subluxation or dislocation in their youth, with approximately 17% of those who had a first dislocation experiencing a recurrence.<sup>9</sup> A family history of PFI is common, as well.<sup>10</sup>

**Diagnosis.** Patients with PFI often present with nonspecific anterior knee pain secondary to recurrent dislocation.<sup>13</sup> Notable exam findings include

- A positive J sign (noted if the patella suddenly shifts medially during early knee flexion or laterally during full extension)
- Decreased quadriceps (specifically VMO) and hamstring strength and flexibility
- Patellar hypermobility, which should be no more than a quarter to a half of the patellar diameter bilaterally

**TABLE**  
Nontraumatic Knee Pain: What to Look for, How Best to Treat

Diagnosis	History	Physical exam	Treatment
PFPS*	Anterior pain + Theater sign Descending stairs exacerbates	No effusion + Patellar tilt test Pain with squatting	Quad and hip strengthening Hip flexor, hamstring, iliotibial band, and quad stretching Taping/bracing may help
Chronic dislocation	Anterior pain Snapping/feeling of dislocation History of dislocation	+ J sign Hypermobile patella + Patellar tilt test + Patellar apprehension	VMO strengthening Bracing Surgery may be needed
Patellar tendinopathy†	Anterior pain that worsens with activity, especially jumping	Focal suprapatellar pain (assess for tendon integrity)	Eccentric training Physical therapy PRP injections may be considered
ITBS	Lateral pain that worsens with repetitive knee flexion	+ Noble's test + Ober's test	Refrain from activity that causes pain/activity modification NSAIDs Physical therapy Corticosteroid injections
Plica syndrome	Medial pain Catching/locking	+ Mediapatellar plica test Palpation of plica	Physical therapy Quad strengthening NSAIDs Corticosteroids
Anserine bursitis	Medial pain Obesity, particularly in females Diabetes	Pain with palpation at insertion of anserine complex Edema not always present	Rest Cryotherapy NSAIDs Corticosteroids Weight loss, diabetes treatment, as indicated
Popliteal cyst	Posterior pain/fullness History of other knee pathology	Palpable mass in popliteal fossa + Foucher's sign	Treat underlying condition Knee flexion Ice NSAIDs Aspiration/corticosteroids
Knee effusion	Chronic knee swelling, possibly intermittent, worse with activity	Red, hot, swollen knee indicates possible infection	Joint aspiration is a must if joint infection is a consideration Orthopedic referral if infection is found

Abbreviations: ITBS, iliotibial band syndrome; PFPS, patellofemoral pain syndrome; PRP, platelet-rich plasma; VMO, vastus medialis obliquus.

\*Diagnosis of exclusion.

†The Victorian Institute of Sport Assessment (VISA) questionnaire can be used to follow the progress and severity of patellar tendinosis.<sup>31</sup>

+ A positive result is indicative of the diagnosis.

- Pain during a patellar tilt test
- A positive patellar apprehension test.<sup>10</sup> (With the patient lying with the knee flexed to 20°, place thumbs on the medial patella and push laterally; the patient will straighten leg with pain or “ap-prehension” prior to patellar dislocation.)

Plain radiography should be ordered in all cases to assess for osseous trauma/deformity and to help guide surgical consideration. MRI can provide additional information when significant soft-tissue damage is suspected or the patient does not improve with conservative therapy.<sup>8,11</sup>

**Treatment.** A recent Cochrane review showed that conservative treatment (VMO strengthening, bracing, and proprioceptive therapy) prevented future dislocations more effectively than surgical intervention.<sup>11</sup> However, surgery is indicated when obvious predisposing anatomic conditions (osteochondral fracture, intra-articular deformity, or a major tear of a medial soft-tissue stabilizer) are clearly shown on imaging.<sup>8,11</sup>

## Patellar tendinopathy

An overuse injury often called “jumper’s knee” because it is associated with high-intensity jumping sports (eg, volleyball and basketball), patellar tendinopathy is an insertional tendinopathy with pain most commonly at the proximal patellar tendon.<sup>10</sup> The pathology of the injury, though poorly understood, is believed to result from an impaired healing response to microtears.<sup>12,14</sup>

**Diagnosis.** Patients with patellar tendinopathy typically present with anterior suprapatellar pain aggravated by activity. Classically, the pain can occur in any of four phases<sup>12</sup>

1. Pain isolated after activity
2. Pain that occurs during activity but does not impede activity
3. Pain that occurs both during and after the activity and interferes with competition
4. A complete tendon disruption.

Examination should include an assessment of the patellar tendon for localized thickening, nodularity, crepitus, and focal suprapatellar tenderness. The muscle-tendon function should be evaluated by assessing knee mobility and strength of the quads via straight-leg raise, decline squat, or single-leg squats.<sup>12</sup> The Victorian Institute of Sport Assessment (VISA) questionnaire can be used to quantify the symptoms and to help track the patient’s progress throughout therapy.<sup>31</sup> There are no proven special

tests or radiologic studies to aid in the diagnosis of patellar tendinopathy,<sup>14</sup> but MRI can be used for further evaluation when findings are equivocal.<sup>35</sup>

**Treatment.** A wide range of options, from eccentric training (eg, three sets of 15 repetitions performed twice a day for 12 weeks) and physical therapy to platelet-rich plasma (PRP) injections, sclerosing injections, and surgery, are available for the treatment of patellar tendinopathy.<sup>13-15</sup> While no specific data have proven the superiority of any one therapy, expert consensus recommends eccentric exercise as initial therapy, performed for 12 weeks.<sup>14,15</sup>

It’s also interesting to note that a recently published study showed that three weekly PRP injections helped 75% of patients—all of whom failed to respond to four months of eccentric therapy—return to their presymptom activity level within 90 days.<sup>16</sup> Corticosteroid injections should not be used to treat patellar tendinopathy due to the risk for tendon rupture.<sup>15</sup> Orthopedic referral for surgical intervention should be considered for patients who fail to respond after three to six months of conservative therapy.<sup>14</sup>

## LATERAL KNEE PAIN

### Iliotibial band syndrome (ITBS)

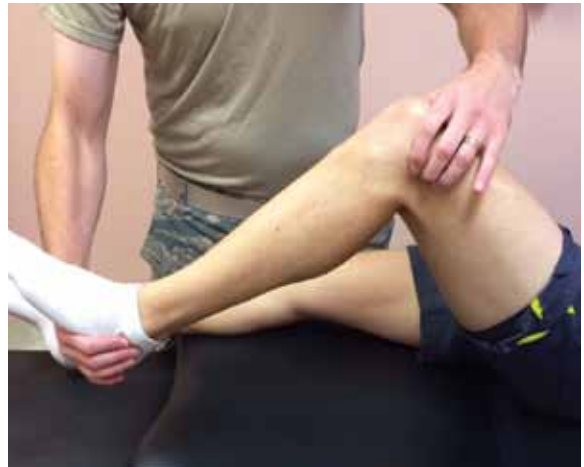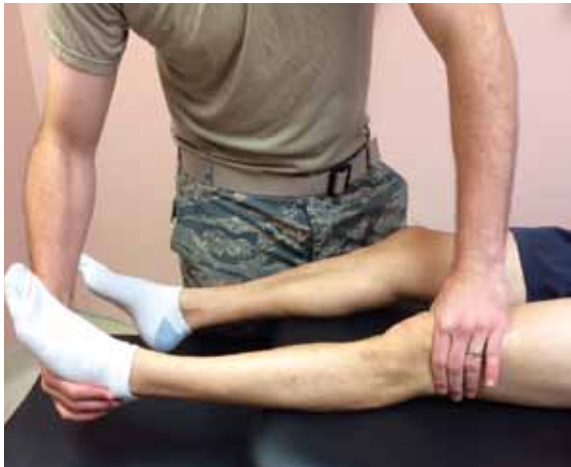A common source of lateral knee pain, ITBS is found particularly in runners, cyclists, and endurance athletes.<sup>17-19,36,37</sup> The exact pathophysiology behind this diagnosis is debatable, but the most accepted etiology is inflammation generated from microtrauma to the soft tissues with inadequate healing time, resulting in persistent inflammation. ITBS is often associated with excessive overall running mileage, a sudden increase in mileage, or an abrupt change in training.<sup>18,37</sup>

**Diagnosis.** Patients often complain of persistent nontraumatic lateral knee pain that worsens with repetitive knee flexion (eg, running or cycling).<sup>17-19,37</sup> A physical exam will often reveal pain over the lateral femoral condyle and a positive Noble’s test (see Figure 1, page 30). A positive Ober’s test (see Figure 2, page 32) is suggestive of ITBS, as well. The sensitivity and specificity of these tests are not well established, but in patients performing repetitive knee flexion activities with subjective lateral knee pain, pain over the lateral femoral condyle and a positive Ober’s and/or Noble’s test suggest an ITBS diagnosis.<sup>18</sup> Imaging is not indicated initially, but MRI should be used in refractory cases to rule out other etiologies.<sup>17,19</sup>

**Treatment.** First-line therapy for ITBS is conservative,<sup>17-19,36,37</sup> often involving a combination of

**FIGURE 1**

Suspect iliotibial band syndrome? Perform Noble's test



Photos Courtesy of Carlton J. Covey, MD, FAAPF

Palpate over the lateral femoral condyle and flex/extend the knee. If the action elicits pain, the test is positive for iliotibial band syndrome.

techniques such as refraining from the activity that triggers the pain, NSAIDs, activity modification to reduce the strain over the ITB, myofascial release via foam rollers, and physical therapy focused on stretching the ITB, tensor fasciae latae, and gluteus medius while strengthening the gluteus medius and core muscles.<sup>17</sup> No single program has been shown to be better than another.

**Corticosteroid injections** are second-line therapy and have been shown to improve pain compared with placebo up to two weeks postinjection.<sup>17,19</sup> When symptoms persist for more than six months despite conservative treatment, surgical intervention may be indicated.<sup>18,19</sup> Patients who experience temporary pain relief with corticosteroid injections often respond best to surgery.<sup>36</sup>

### MEDIAL KNEE PAIN

#### Medial plica syndrome

Because of its anatomic location, the medial plica—which can be palpated in up to 84% of the population<sup>20</sup>—is susceptible to impingement by the medial femoral condyle or the patellofemoral joint. Trauma with repetitive knee movement leads to inflammation and thickening of the plica, resulting in medial plica syndrome.<sup>20,38</sup> Initial inflammation may be triggered by blunt trauma, a sudden increase in activity, or transient synovitis.<sup>22</sup>

**Diagnosis.** Medial plica syndrome is a challeng-

ing diagnosis. Patients generally have nonspecific complaints of aching medial knee pain, locking, and catching similar to complaints of a medial meniscal injury.<sup>20</sup>

Evaluation should include the mediopatellar plica test, which is performed with the patient lying supine with the knee fully extended. Pressure is placed over the inferomedial patellofemoral joint, creating an impingement of the medial plica between the finger and the medial femoral condyle. Elimination or marked diminishing of pain with knee flexion to 90° is considered a positive test.<sup>21</sup>

A recent systematic review found this test to be more diagnostically accurate than an MRI (sensitivity of the test is 90% and specificity is 89%, vs 77% and 58%, respectively, for MRI) for detection of medial plica syndrome. Ultrasound is almost as accurate, with a sensitivity of 90% and specificity of 83%.<sup>39</sup>

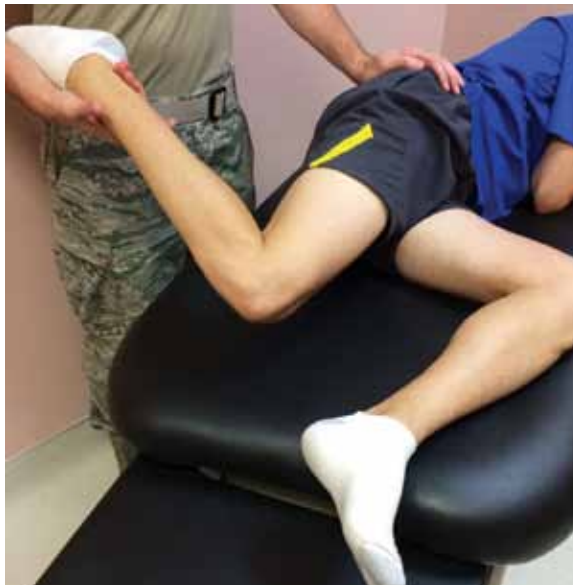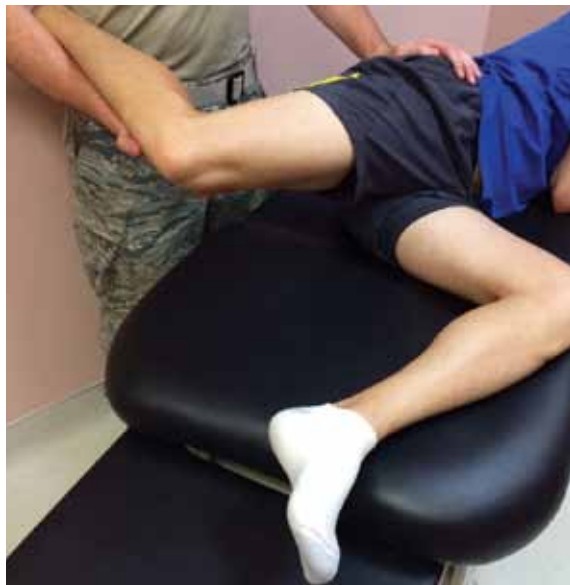**Treatment** of medial plica syndrome centers on physiotherapy and quadriceps strengthening,<sup>20</sup> augmented with NSAIDs. Intra-articular corticosteroid injections are considered second-line treatment.<sup>20,22</sup> An orthopedics referral is indicated to consider arthroscopic plica removal for refractory cases.<sup>20,22</sup>

#### Pes anserine bursitis

The anserine bursal complex, located approximately 5 cm distal to the medial joint line, is formed by the combined insertion of the sartorius, gracilis, and

**FIGURE 2**

Ober's test is also useful for ITBS



Photos Courtesy of Carlton J. Covey, MD, FAAPF

Abduct and extend the affected hip with one hand and stabilize the pelvis with the other, then allow the knee to passively fall. The leg should drop to parallel as shown on the right; failure to do so suggests a tight iliotibial band that can lead to iliotibial band syndrome.

semitendinosus tendons,<sup>39</sup> but the exact mechanism of pain is not well understood. Whether the pathophysiology is from an insertional tendonitis or overt bursitis is unknown, and no studies have focused on prevalence or risk factors. What is known is that overweight individuals and women with a wide pelvis seem to have a greater predilection and those with pes planus, diabetes, or knee osteoarthritis are at increased risk.<sup>23</sup>

**Diagnosis.** Medial knee pain reproduced on palpation of the anatomic site of insertion of the pes anserine tendon complex supports a diagnosis of pes anserine bursitis, with or without edema. Radiologic studies are not needed but may be helpful if significant bony pathology is suspected. Ultrasound, CT, and MRI are not recommended.<sup>23</sup>

**Treatment.** Resting the affected knee, cryotherapy, NSAIDs, and use of a pillow at night to relieve direct bursal pressure are recommended.<sup>33</sup> Weight loss in obese patients, treatment of pes planus, and control of diabetes may be helpful, as well. Although the literature is limited and dated, corticosteroid injection has been found to reduce the pain and may be considered as second-line treatment.<sup>24-26</sup>

## POSTERIOR KNEE PAIN

### Popliteal (Baker's) cyst

The popliteal fossa contains six of the numerous bursa of the knee; the bursa beneath the medial head of the gastrocnemius muscle and the semimembranosus tendon is most commonly involved in the formation of a popliteal cyst.<sup>40</sup> It is postulated that increased intra-articular pressure forces fluid into the bursa, leading to expansion and pain. This can be idiopathic or secondary to internal derangement or trauma to the knee.<sup>41</sup> Older age, a remote history of knee trauma, or a coexisting joint disease such as osteoarthritis, meniscal pathology, or rheumatoid arthritis are significant risk factors for popliteal cysts.<sup>27</sup>

**Diagnosis.** Most popliteal cysts are asymptomatic in adults and discovered incidentally after routine imaging to evaluate other knee pathology. However, symptomatic popliteal cysts present as a palpable mass in the popliteal fossa, resulting in pain and limited range of motion.

During the physical exam with the patient lying supine, a medial popliteal mass that is most prominent with the knee fully extended is common. A positive Foucher's sign (the painful mass is palpated

posteriorly in the popliteal fossa with the knee fully extended; pain is relieved and/or the mass reduced in size with knee flexion to 45°) suggests a diagnosis of popliteal cyst.<sup>27,28</sup>

Radiologic studies are generally not needed to diagnose a popliteal cyst. However, if diagnostic uncertainty remains after the history and physical exam, plain knee radiographs and ultrasound should be obtained. This combination provides complementary information and helps rule out a fracture, arthritis, and thrombosis as the cause of the pain.<sup>27</sup> MRI is helpful if the diagnosis is still in doubt or if patients are suspected of having significant internal derangement leading to cyst formation. Arthrography or CT is generally not needed.<sup>27,41</sup>

**Treatment.** As popliteal cysts are often associated with other knee pathology, management of the underlying condition often leads to cyst regression. Keeping the knee in flexion can decrease the available space and assist in pain control in the acute phase.<sup>27</sup> Cold packs and NSAIDs can also be used initially. Cyst aspiration and intra-articular corticosteroid injection have been shown to be effective for cysts that do not respond to this conservative approach.<sup>27</sup> However, addressing and managing the underlying knee pathology (eg, osteoarthritis, meniscal pathology, or rheumatoid arthritis) will prevent popliteal cysts from recurring.

## WHEN THE PROBLEM IS PAINFUL KNEE EFFUSION

Nontraumatic knee effusion can be the primary source of knee pain or the result of underlying pathology. It is mentioned here because clinical suspicion is paramount to diagnosis of a septic joint—a serious cause of painful knee effusion that warrants prompt treatment.

As in other causes of knee pain, a detailed history of the character of the pain is essential. Septic arthritis and crystalline disease (gout, pseudogout) should be suspected in patients without a history of trauma who cannot bear weight. Systemic complaints point to an infection and, with the exception of a possible low-grade fever, are not typically seen in crystalline disease. Notable findings include an erythematous, hot, swollen knee and pain with both active and passive movement.

Plain radiographs of the knee should be ordered to rule out significant trauma or arthritis as the etiology. It is important to perform joint aspiration with synovial fluid analysis. Fluid analysis should include

a white blood cell (WBC) count with differential, Gram stain and cultures, and polarized light microscopy (not readily available in an outpatient setting).<sup>29</sup>

Synovial fluid analysis characteristics suggestive of a septic joint include turbid quality, WBC > 50,000/μL, an elevated protein content, and a low glucose concentration.<sup>30</sup> Gram stain and culture will help identify the infectious agent. Orthopedic referral should not be delayed in patients with a suspected infectious joint. Corticosteroids should not be injected during aspiration if infection is being ruled out.

When Jane returns for a follow-up visit eight weeks later, she states that the knee pain has resolved and that she has returned to running. She has lost an additional eight pounds and continues to diet. And, at the advice of her physical therapist, she is continuing her physiotherapy regimen at home to prevent a recurrence of PFPS. **CR**

## REFERENCES

1. Earl JE, Vetter CS. Patellofemoral pain. *Phys Med Rehabil Clin N Am*. 2007;18:439-458.viii.
2. McGowan HJ, Beutler A. Patellofemoral syndrome. Essential Evidence Plus. [www.essentialevidenceplus.com](http://www.essentialevidenceplus.com). Accessed April 14, 2015.
3. Nunes GS, Stapait EL, Kirsten MH, et al. Clinical test for diagnosis of patellofemoral pain syndrome: systematic review with meta-analysis. *Phys Ther Sport*. 2013;14:54-59.
4. Rixe JA, Glick JE, Brady J, et al. A review of the management of patellofemoral pain syndrome. *Phys Sportsmed*. 2013;41:19-28.
5. Bolgla LA, Boling MC. An update for the conservative management of patellofemoral pain syndrome: a systematic review of the literature from 2000 to 2010. *Int J Sports Phys Ther*. 2011;6:112-125.
6. Barton C, Balachandar V, Lack S, et al. Patellar taping for patellofemoral pain: a systematic review and meta-analysis to evaluate clinical outcomes and biomechanical mechanisms. *Br J Sports Med*. 2014;48:417-424.
7. Dutton RA, Khadavi MJ, Fredericson M. Update on rehabilitation of patellofemoral pain. *Curr Sports Med Rep*. 2014;13:172-178.
8. Kapur S, Wissman RD, Robertson M, et al. Acute knee dislocation: review of an elusive entity. *Curr Probl Diagn Radiol*. 2009;38:237-250.
9. Colvin AC, West RV. Patellar instability. *J Bone Joint Surg Am*. 2008;90:2751-2762.
10. Tscholl PM, Koch PP, Fucentese SF. Treatment options for patellofemoral instability in sports traumatology. *Orthop Rev (Pavia)*. 2013;5:e23.
11. Earhart C, Patel DB, White EA, et al. Transient lateral patellar dislocation: review of imaging findings, patellofemoral anatomy, and treatment options. *Emerg Radiol*. 2013;20:11-23.
12. Tan SC, Chan O. Achilles and patellar tendinopathy: current understanding of pathophysiology and management. *Disabil Rehabil*. 2008;30:1608-1615.
13. Gaida JE, Cook J. Treatment options for patellar tendinopathy: critical review. *Curr Sports Med Rep*. 2011;10:255-270.
14. Rodriguez-Merchan EC. The treatment of patellar tendinopathy. *J Orthop Traumatol*. 2013;14:77-81.
15. Childress MA, Beutler A. Management of chronic tendon injuries. *Am Fam Physician*. 2013;87:486-490.
16. Charoussat C, Zaoui A, Bellaiche L, et al. Are multiple platelet-rich plasma injections useful for treatment of chronic patellar tendinopathy in athletes? A prospective study. *Am J Sports Med*. 2014;42:906-911.
17. Strauss EJ, Kim S, Calcei JG, et al. Iliotibial band syndrome: evaluation and


- management. *J Am Acad Orthop Surg*. 2011;19:728-736.
18. Bellary SS, Lynch G, Housman B, et al. Medial plica syndrome: a review of the literature. *Clin Anat*. 2012;25:423-428.
  19. Hong JH, Kim JS. Diagnosis of iliotibial band friction syndrome and ultrasound guided steroid injection. *Korean J Pain*. 2013;26:387-391.
  20. Bellary SS, Lynch G, Housman B, et al. Medial plica syndrome: a review of the literature. *Clin Anat*. 2012;25:423-428.
  21. Kim SJ, Jeong JH, Cheon YM, et al. MPP test in the diagnosis of medial patellar plica syndrome. *Arthroscopy*. 2004;20:1101-1103.
  22. Schindler OS. 'The Sneaky Plica' revisited: morphology, pathophysiology and treatment of synovial plicae of the knee. *Knee Surg Sports Traumatol Arthrosc*. 2014;22:247-262.
  23. Helfenstein M Jr, Kuromoto J. Anserine syndrome. *Rev Bras Rheumatol*. 2010;50:313-327.
  24. Abeles M. Osteoarthritis of the knee: anserine bursitis as an extra-articular cause of pain. *Clin Res*. 1983;31:4471-4476.
  25. Kang I, Han SW. Anserine bursitis in patients with osteoarthritis of the knee. *South Med J*. 2000;93:207-209.
  26. Yoon HS, Kim SE, Suh YR, et al. Correlation between ultrasonographic findings and the response to corticosteroid injection in pes anserinus tendinobursitis syndrome in knee osteoarthritis patients. *J Korean Med Sci*. 2005;20:109-112.
  27. Stein D, Cantlon M, MacKay B, et al. Cysts about the knee: evaluation and management. *J Am Acad Orthop Surg*. 2013;21:469-479.
  28. Canoso JJ, Goldsmith MR, Gerzof SG, et al. Foucher's sign of the Baker's cyst. *Ann Rheum Dis*. 1987;46:228-232.
  29. Palmer T. Knee pain. Essential Evidence Plus. www.essentialevidenceplus.com. Accessed April 14, 2015.
  30. Franks AG Jr. Rheumatologic aspects of knee disorders. In: Scott WN, ed. *The Knee*. St. Louis: Mosby; 1994:315-329.
  31. Visentini PJ, Khan KM, Cook JL, et al. The VISA score: an index of severity of symptoms in patients with jumper's knee (patellar tendinosis). Victorian Institute of Sport Tendon Study Group. *J Sci Med Sport*. 1998;1:22-28.
  32. Halabchi F, Mazaheri R, Seif-Barghi T. Patellofemoral pain syndrome and modifiable intrinsic risk factors; how to assess and address? *Asian J Sports Med*. 2013;4:85-100.
  33. Dixit S, DiFiori JP, Burton M, et al. Management of patellofemoral pain syndrome. *Am Fam Physician*. 2007;75:194-202.
  34. Callaghan MJ, Selfe J. Patellar taping for patellofemoral pain syndrome in adults. *Cochrane Database Syst Rev*. 2012;4:CD006717.
  35. Atanda AJ Jr, Ruiz D, Dodson CC, et al. Approach to the active patient with chronic anterior knee pain. *Phys Sportsmed*. 2012;40:41-50.
  36. Ellis R, Hing W, Reid D. Iliotibial band friction syndrome—a systematic review. *Man Ther*. 2007;12:200-208.
  37. Kirk KL, Kuklo T, Klemme W. Iliotibial band friction syndrome. *Orthopedics*. 2000;23:1209-1217.
  38. Stubbings N, Smith T. Diagnostic test accuracy of clinical and radiological assessments for medial patella plica syndrome: a systematic review and meta-analysis. *Knee*. 2014;21:486-490.
  39. Alvarez-Nemegyei J, Canoso JJ. Evidence-based soft tissue rheumatology IV: anserine bursitis. *J Clin Rheumatol*. 2004;10:205-206.
  40. Fritschy D, Fasel J, Imbert JC, et al. The popliteal cyst. *Knee Surg Sports Traumatol Arthrosc*. 2006;14:623-628.
  41. Handy JR. Popliteal cysts in adults: a review. *Semin Arthritis Rheum*. 2001;31:108-118.

**Clinician  
Reviews**

IN PARTNERSHIP WITH



American  
Society of  
Endocrine PAs



National Kidney  
Foundation Council of  
Advanced Practitioners

**Clinician Reviews offers expert-authored features and departments for your use in daily practice.**

•••••

You can look forward to content endorsed by these professionals in the form of  
Conferences and Events • Continuing Education • Specialty Q&A