

Skin & Allergy News

www.skinandallergynews.com

VOL. 41, No. 1

The Leading Independent Newspaper for Medical, Surgical, and Aesthetic Dermatology

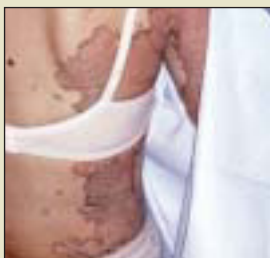JANUARY 2010

WHAT'S NEW

- **Predictions for 2010** from the SKIN & ALLERGY NEWS Editorial Advisory Board. 4
- **Etanercept during pregnancy** found to increase risk of having a child with malformations. 8
- **AAD 'Seal of Recognition'** program to be phased out, as costs exceed revenue. 9
- **Gadolinium-based** contrast agent black box warnings touted as reason for reduction of NSF. 10
- **California's mandate** for health checks before elective cosmetic surgery is debated. 13
- **Toxin, filler combination** doubled the duration of aesthetic response in lower-face study. 17
- **Radiation after lymphadenectomy** found to reduce melanoma recurrence in high-risk patients. 20
- **Gardasil and Cervarix** are not interchangeable, expert says. 21
- **CMS announces** specialty consultations will no longer be covered. Dr. Joseph S. Eastern bids farewell but not without protest. 22



CASE OF THE MONTH



COURTESY DR. RICHARD P. MCCLINTOCK JR.

A 47-year-old woman with a previously reported biopsy diagnosis of pityriasis rubra pilaris presented with aggravation of a scaling, papular eruption. *What's your diagnosis?* 31

Groups Unite Under Stop Medical Taxes Coalition

BY ALICIA AULT

As the Senate continued to debate the Democrats' health reform proposal, it was not clear whether a proposed 5% tax on elective cosmetic surgery, including injectables, would survive the floor fight and the eventual conference committee to reconcile the House and Senate bills.

Physician groups—not just dermatologists—have united in opposition to the tax, saying that it is discriminatory, and, they point out, it has proven to be an inefficient means of collecting revenue in the only state with such a tax.

Even so, the American Academy of Dermatology expects more states to look at a cosmetic tax as a potential revenue source this year, Dr. David Pariser, presi-

dent of the AAD, said in an interview.

New Jersey has taxed elective cosmetic procedures since 2004, levying a 6% fee at the point of sale—the physician's office—but the state has had a 59% shortfall based on projected revenue estimates, according to the Stop Medical Taxes Coalition. The newly formed group, which is sponsored by Botox maker Allergan Inc., represents 22 medical organizations, the AAD, the American Society for Aesthetic Plastic Surgery (ASAPS), the American Society for Dermatologic Surgery Association, the American Association of Neurologic Surgeons, and the American Society of Breast Surgeons.

The American Medical Association also came out in opposition to the tax. In a letter to Senate Majority Leader

The AAD expects more states to look at a cosmetic tax as a potential revenue source this year.

Harry Reid of Nevada, the AMA said that it "strongly opposes taxes on physician services to fund health care programs or to accomplish health system reform." The organization said that it was concerned that the exceptions outlined in the bill weren't clear enough or broad enough.

And, said the AMA, the tax could be expanded in the future to cover other health care items or services that might not be considered medically necessary.

The Stop Medical Taxes Coalition wrote to all 50 Senators in late November, outlining its objections. A chief argument: The tax would fall disproportionately on working women.

According to survey data collected by the American Society of Plastic Surgeons

See **Groups Unite** page 2

Elastography Delves Deep to ID Skin Cancer

BY PATRICE WENDLING

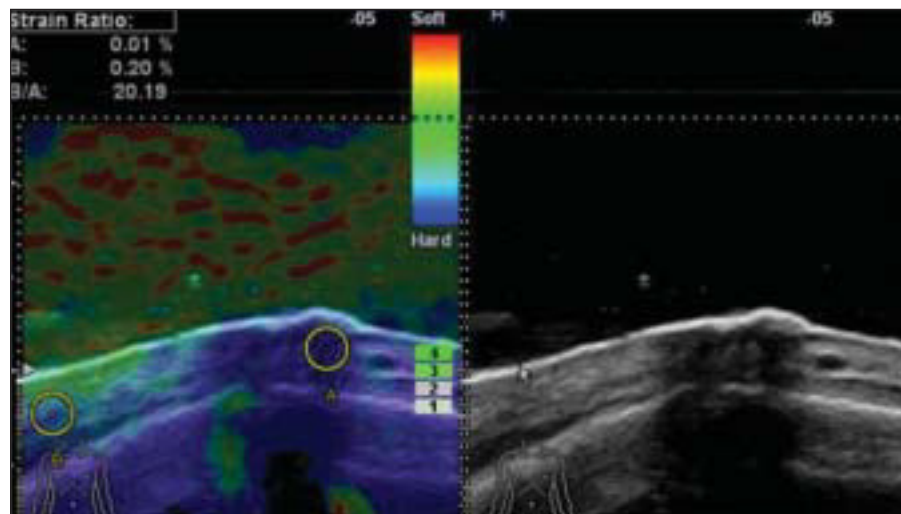
CHICAGO — An ultrasound technique that measures tissue elasticity could dramatically alter the way in which skin cancer is diagnosed.

In a prospective study of 56 patients with proliferative malignant neoplasms or benign skin lesions, the use of ultrasound elastography analysis prior to biopsy correctly differentiated benign from malignant lesions in 100% of cases (*P value equal .0007*), Dr. Eliot Siegel reported at the annual meeting of the Radiological Society of North America.

"We believe that ultrasound has tremendous potential that is completely untapped now to characterize and delineate the extent of skin lesions currently evaluated visually," he said.

"We believe it has tremendous promise to reduce unnecessary biopsies," he added.

Elastography noninvasively estimates the axial tissue strain, or elastic properties of tissue. Cystic lesions demonstrate



An elastogram (left) and ultrasound (right) show squamous cell carcinoma of the skin. The technique could eliminate unnecessary biopsies of benign skin lesions.

high levels of elasticity, while malignant lesions are relatively "hard" with a very low level of elasticity.

Ultrasound with elastography, more so than optical or light images, is unique in its ability to provide the proper depth

at which to analyze lesions—around 5 mm below the surface, said Dr. Siegel, vice chair of radiology and a professor at the University of Maryland in Baltimore. This may be useful in the early

See **Elastography** page 18

SKIN DISEASE EDUCATION FOUNDATION'S 34TH ANNUAL www.sdefderm.com

Hawaii Dermatology Seminar[™]

A CONTINUING MEDICAL EDUCATION CONFERENCE

FEBRUARY 14-19, 2010

HILTON WAIKOLOA HOTEL, BIG ISLAND HAWAII

Approved for 35.5 AMA PRA Category 1 Credit(s)[™]

Jointly sponsored by



an Elsevier business

Assess Future Risk Before Mohs Defect Repair

BY SUSAN LONDON

SEATTLE — Successful reconstruction of facial defects created by Mohs surgery requires knowledge not only of appropriate operative techniques, but also of patients and their cancers.

Assessing a patient's skin cancer risk factors is key before repairing any Mohs defect, according to Dr. Michael L. Bentz, professor and chairman of the division of plastic and reconstructive surgery at the University of Wisconsin, Madison. "It's important to know who is more likely to come back with other skin cancers because it may change the way you stage and think about the reconstruction," he said.

A prerequisite for successful reconstruction is ensuring that the cancer has been adequately treated, Dr. Bentz said at the annual meeting of the American Society of Plastic Surgeons.

"The first thing you are going to throw at these patients reconstructively is your best option, so you want to make sure that you have not compromised that by inadequate primary tumor treatment." He recommended a good working relationship between the Mohs and reconstructing surgeon (if applicable), a careful review of pathology reports, and, if necessary, a reassessment of margins.

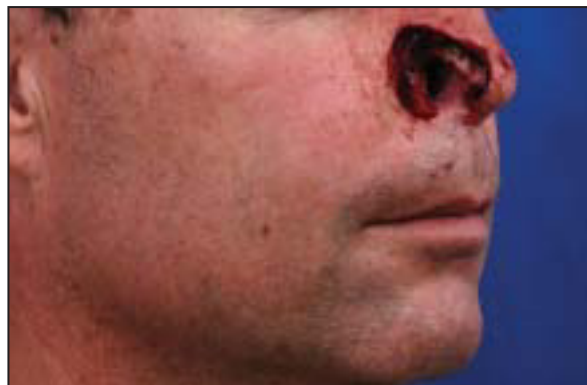"Knowing your tumor is important," he said. It is prudent to avoid initial definitive reconstruction of defects from dermatofibrosarcoma protuberans because of its high recurrence rate. "My goal with these is to get them grafted, let them sit a year or two, and then come back and do the definitive reconstruction," he explained.

Maximizing the likelihood of a successful and uneventful reconstruction also requires a thorough preoperative assessment of the patient, given that most patients with skin cancer are older, with comorbidities, and that many take medications, particularly anticoagulants, that may need to be tapered.

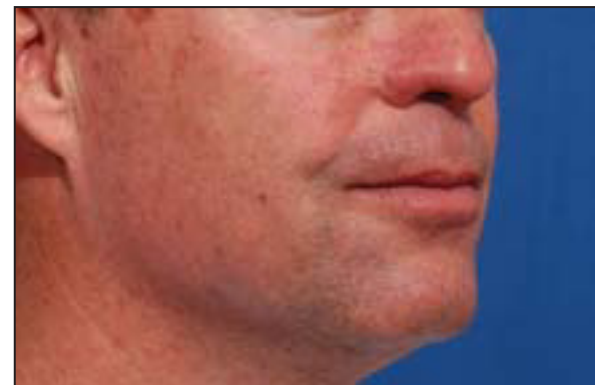Dr. Bentz and Dr. Frederick J. Menick, a plastic surgeon in private practice in Tucson, Ariz., went on to discuss the best way to repair defects and the best flaps to use.

► **Pericranial flaps.** These flaps are often a good option for repairing Mohs defects of the forehead, especially if bone is exposed, noted Dr. Bentz. "For patients who particularly are at risk of other skin cancers, you want to use big flaps because if you use small flaps, you will have difficulty using them again," he said.

► **Cheek flaps.** If they are elevated to reconstruct lat-



This patient's defect from Mohs surgery was repaired with a modified folding line technique developed by Dr. Frederick J. Menick as part of his three-stage forehead flap approach.



PHOTOS COURTESY DR. FREDERICK J. MENICK

eral forehead defects, cheek flaps should be suspended from bone. "They weigh a fair amount and there is some tension on them," he said. "So taking a permanent suture and suspending them to the appropriate tension point in bone, with or without drilling holes, helps avoid postoperative complications."

Reconstructing Mohs cheek defects poses several challenges, including the limited number of lines available for hiding donor sites and the potential for distorting the eyelid. "You want to be thoughtful about how you reallocate cheek tissue, trying to hide your donor site and yet minimize the associated complications," he said.

► **Lip defects.** Principles of cleft lip repair are often helpful in reconstructing larger Mohs defects of the lip, according to Dr. Bentz. "Don't be afraid to take the whole lip down to full-thickness fashion and put it back together," he advised.

► **Ear defects.** Small defects can be reconstructed with full-thickness grafts, ideally taken from somewhere other than the ipsilateral retroauricular area, given the possibility of subsequent cancers of that ear requiring a retroauricular flap. Large ear defects can be reconstructed with a variety of techniques, but they all require attention to avoid constricting or accentuating the ear.

► **Nose defects.** When reconstructing small, superficial Mohs defects of the nose, Dr. Menick said that he mainly uses secondary healing, small composite grafts (for minor rim defects), and one-stage nasolabial flaps (for alar sidewall defects), along with a lot of full-thickness forehead skin grafts.

When reconstructing Mohs defects of the nose that

are large (over 1.5 cm in diameter), deep, or adversely located (affecting the tip or columella), he recommended a forehead flap over the two-stage nasolabial flap. The forehead flap does not distort the nasolabial fold, is less obvious during the maturation phase, and never dies or contracts excessively.

► **Forehead grafts.** The secret to getting good results with a forehead skin graft is to not apply it right after the Mohs excision or if a Bovie has been used in the area, noted Dr. Menick. "I send the patient home, have them put Vaseline on the defect, wash it with soap and water, [and] wait about 14 days till it starts to granulate and all that burn injury is spit out," he explained.

As to the type of forehead flap, he expressed a preference for the vertical flap, which, compared with the oblique flap, is much less likely to distort the eyebrow and leaves more options if patients need a second flap. "The vertical forehead flap is reliable, efficient, more vascular, and more widely applicable—it works like a charm," he said.

Dr. Menick also endorsed the three-stage forehead flap over the two-stage because the added intermediate operation provides the ability to sculpt and contour the nose. Other relative merits include its provision of a thin, supple cover; a maximal blood supply; and an ideal framework. Adding an intermediate operation lengthens reconstruction from a 1-month procedure to a 2-month procedure, he acknowledged, but patients generally tolerate it, especially given the aesthetic outcome. ■

Disclosures: Dr. Bentz and Dr. Menick had no relevant conflicts of interest.

Technique May Rival Excision

Elastography from page 1


detection of melanoma before the classic signs such as asymmetry or changes in border are present on the skin's surface. In addition, elastography could have a role during surgery.

"This also could guide the surgeon as the surgeon is doing an excision or biopsy to not just look at the tip of the iceberg that they can see at the skin surface, but actually to be able to look deeper, so they can see exactly which areas they can cut out safely and still remove the entire tumor without unnecessarily removing more than that," he said.

Elastography software is available on most new ultrasound machines, and has been used with promising results for breast, thyroid, and liver cancer. It has not been used to explore skin lesions, except for one prior study from 2007.

That study used absolute strain values, whereas Dr. Siegel and associates also cal-

culated strain ratios. Malignant lesions had higher strain ratios (minimum 5.3; maximum 32.2), compared with benign lesions (min. 0.01; max. 3). None of the malignant lesions violated a strain-ratio



The information gleaned could rival 'information that a pathologist would see after the lesion was excised.'

DR. SIEGEL

cutoff of 3-5, Dr. Siegel said. He presented a few examples, including a squamous cell carcinoma with a ratio of 13.27 and a benign keloid with a ratio of 1.25.

Although preliminary, the data suggest that strain ratios may also be useful in

distinguishing between malignant lesions. Squamous cell carcinomas had a higher ratio overall, said coauthor Dr. Bahar Dasgeb, a radiologist and second-year dermatology resident at Wayne State University in Detroit. Moreover, the strain ratio was higher, even within squamous cell or basal cell cancers, when more invasive cells were present.



'A couple of clinical dermatologists said, "there is no other way."'

DR. DASGEB

If strain ratios are combined with higher ultrasound frequencies, it's possible that the anatomic information gleaned from elastography "could rival the information that a pathologist would see after the lesion was excised," Dr.

Siegel said. "That's really the direction that we'd like to head into for research and development, as we look at much higher ultrasound frequencies."

The current study used a clinically available 14- to 16-mHz ultrasound unit.

The findings were enthusiastically received when presented by Dr. Dasgeb at the Michigan Dermatological Society meeting in November.

"The feedback from Mohs' surgeons was amazing," she said in an interview. "A couple of clinical dermatologists said, 'there is no other way.'"

She suggested transitioning this technology from radiology to clinical dermatology would not be difficult nor take long because of need and the rising incidence and economic impact of skin cancer. It is estimated that one in five Americans will develop skin cancer at some point in their lives. ■

Disclosures: Dr. Siegel disclosed receiving research grants from several imaging companies. Dr. Dasgeb had no disclosures.