

Breast Elastography Found Useful as Adjunct

BY PATRICE WENDLING

CHICAGO — The use of elastography, or the ability to measure the stiffness of lesions during ultrasound, may help distinguish benign from malignant breast lesions, suggest results of a study of 193 women.

Elastography correctly identified 98% of lesions that were shown on biopsy to be malignant. With biopsied benign lesions, elastography properly identified 78% of the lesions, Dr. Stamatia V.



'The addition of elastography could potentially help decrease the need to perform a biopsy.'

DR. DESTOUNIS

Destounis, a diagnostic radiologist at a breast imaging and diagnosis center in Rochester, N.Y., reported in a poster at the annual meeting of the Radiological Society of North America.

"The addition of elastography could potentially help decrease the need to perform a biopsy, or could reduce the need for additional imaging of benign lesions, thus reducing the associated patient anxiety," she told reporters, noting that as many as 20% of young women have breast fibroadenomas.

Elastography software has been available for some time, but is having a resurgence in recent years, particularly in thyroid, prostate, and breast applications as the technology advances and the software is included on new imaging units.

The technology can also be applied to a standard unit without an additional upgrade, with the images read side by side, she said at a press briefing during the meeting.

Overall, elasticity imaging increases the specificity of ultrasound by measuring the compressibility and mechanical properties of a lesion. Tumors are typically stiffer than surrounding tissue, whereas cysts have a "bull's eye" appearance on elastography, Dr. Destounis said. Cancerous lesions also tend to be larger than benign findings on elastography.

The study was conducted in 2007-2009 and included 193 patients (average age, 54 years) who underwent elastography at the time of standard breast ultrasound utilizing a Siemens Sonoline Antares or Siemens S2000 ultrasound unit.

A total of 58 lesions did not undergo biopsy and were predetermined to be benign. Biopsies were performed in 140 lesions, of which 59 were cancers, 69 were benign, 1 was an atypical papillary neoplasm, and 11 were cyst aspirations in which fluid was drained and the abnormality resolved.

Of the 140 biopsies, the elastogram image correlated with the standard B-mode ultrasound image in 58 of the 59 cancers (98%). One case was interpreted as benign by elastography, but was a cancer on needle biopsy, said Dr. Destounis, also of the department of imaging sciences at the University of Rochester.

Of the 69 benign findings observed, the elastogram and B-mode ultrasound images correlated in 54 (78%) of cases. Four did not correlate and measured larger on elastography, and 11 cases were unclear, she said.

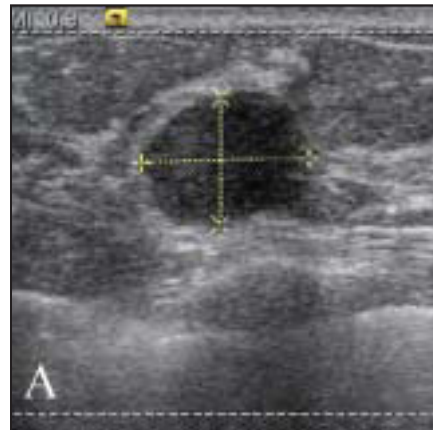
"Women are becoming more and more

concerned about unnecessary procedures and unnecessary needle biopsies and the anxiety that creates," Dr. Destounis said.

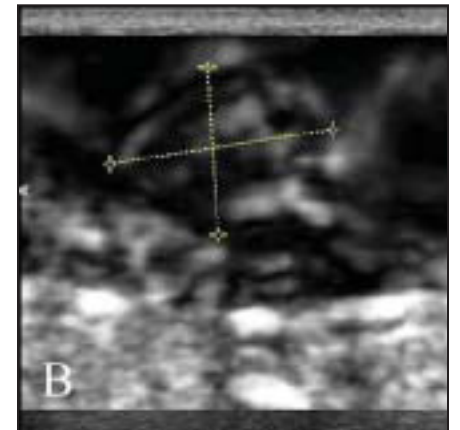
"I think this may be an additional tool, specifically for some of the benign findings like the fibroadenomas in young women or some of the cystic structures that you can really identify with elastography. You have to use your clinical judg-

ment. I'm not using elastography in a vacuum. I'm using it in correlation with everything else." ■

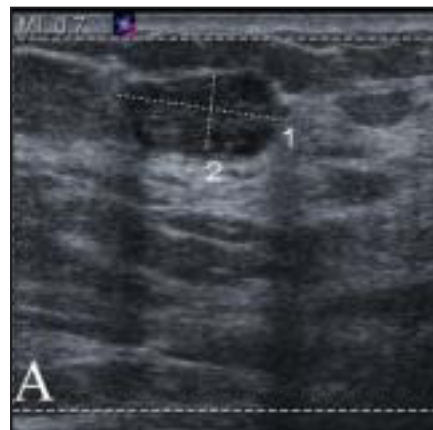Disclosures: Dr. Destounis is a consultant for Carestream Health, an advisory board member for Siemens, and an investigator for Siemens, Fujifilm Holdings, Hologic, and U-Systems.



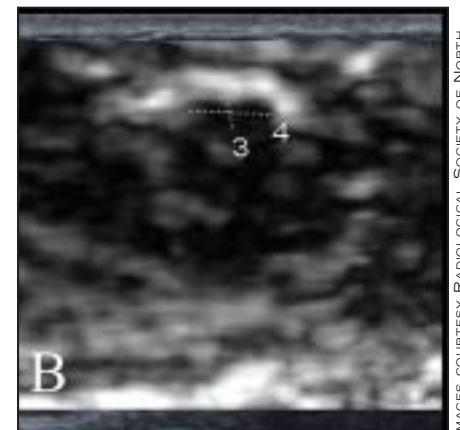
Ultrasound reveals the presence of a solid mass in a patient's breast.



A mass that's cancerous appears larger on elastography than on ultrasound.



Ultrasound shows a nodule consistent with this patient's fibroadenoma.



Benign lesions appear smaller on elastography than on ultrasound.

IMAGES COURTESY RADIOLOGICAL SOCIETY OF NORTH AMERICA

Sharp Rise Seen in Prophylactic Contralateral Mastectomy

BY BETSY BATES

SAN ANTONIO — Breast cancer patients undergoing prophylactic contralateral mastectomy are generally not at high risk for contralateral breast cancer, and may be influenced by anxiety or imaging studies that may not have clinical relevance, based on a study presented at the San Antonio Breast Cancer Symposium.

Rates of prophylactic contralateral mastectomy have increased "dramatically" among women with all stages of breast cancer in the United States in recent years, said Dr. Tari A. King, a breast cancer surgeon at Memorial Sloan-Kettering Cancer Center in New York City.

From January 1997 to December 2005, for example, rates of the procedure increased from 7% to 24% of women who underwent mastectomy at her institution, she said in an inter-

view following her presentation.

Dr. King and her associates sought to learn whether the increase in prophylactic mastectomy could be attributed to better awareness of risk factors for contralateral recurrence or treatment factors related to the index lesion.

A total of 2,965 women underwent mastectomy for stage 0-III unilateral breast cancer during the study period, 407 of whom (13.7%) opted to have a prophylactic mastectomy of the contralateral breast within 12 months. The majority (367) had the contralateral procedure immediately following breast cancer surgery.

Women who opted for prophylactic contralateral mastectomy were younger than those who did not undergo the added surgery (mean age, 45 vs. 54 years) and more likely to be white (93% vs. 7%).

The *P* values for both charac-

teristics were highly significant.

Equally significant was that women choosing contralateral prophylactic mastectomy were more likely to have a family history of breast cancer (68% vs. 32%). Dr. King noted, however, that 43% of patients opting for additional surgery had no first-degree relatives with breast cancer. Almost half (49%) had two first-degree relatives with breast cancer, and just 8% had two or more first-degree relatives with the disease.

Just 13% of those who underwent prophylactic surgery were considered "high risk" because they were BRCA gene carriers (37 patients) or had undergone prior mantle radiation for Hodgkin's disease (15 patients).

Index cancer pathology revealed only ductal carcinoma in situ in 22% of patients who opted to have their contralateral breasts removed, suggesting that they were at exceedingly

low risk of a contralateral recurrence. The mean tumor size was larger among women who failed to have prophylactic surgery (2.16 cm vs. 1.53 cm), as was positive node status (57% vs. 47%); both differences were statistically significant.

Clinical management factors strongly associated with prophylactic surgery included MRI at diagnosis and an additional biopsy in the contralateral breast because of MRI results. Nearly half of women who decided on additional surgery (43%) had undergone an MRI, compared with just 16% of those who did not opt to have a prophylactic mastectomy.

The MRIs led to an additional contralateral or bilateral biopsy in 29% of women who chose added surgery, compared with just 4% in the group who did not (*P* less than .0001). However, many of the women with MRI findings never had a biopsy to

confirm whether a malignancy was present in the contralateral breast, instead deciding preemptively on a contralateral prophylactic mastectomy.

Breast conservation surgery was attempted in more women in the prophylactic mastectomy group (28%, compared with 16%; *P* less than .0001). The same women were more likely to undergo breast reconstruction, 87% vs. 51% (*P* less than .0001), suggesting that some women may have chosen the added surgery in order to achieve cosmetic symmetry.

After a median follow-up of 6 years, contralateral breast cancer developed in 12 (0.4%) women who did not undergo contralateral prophylactic mastectomies. ■

Disclosures: Neither Dr. King nor any of her coinvestigators reported any relevant financial disclosures.