

# Autofluorescence Endoscope Detects Endometriosis

BY JEFF EVANS AND  
HEIDI SPLETE  
Senior Writers

LAS VEGAS — An endoscopic device that has been used to detect lesions in the bladder and lung was able to detect unusual and inconspicuous endometrial lesions during laparoscopy that cannot be seen under white light, Dr. Steven F. Palter said in his award-winning presentation at the annual meeting of the American Association of Gynecologic Laparoscopists.

Dr. Palter and his colleagues conducted a pilot study using the D-Light system to detect lesions in patients suspected of having endometriosis because of pelvic pain or infertility. All suspected lesions were biopsied and excised for pathologic confirmation. Eight of 10 women were diagnosed with endometriosis, and 34 biopsies were reviewed.

Overall, 79% of the lesions diagnosed with autofluorescence were confirmed to be endometriosis. And the new technique revealed additional lesions in 75% of the patients who had endometriosis. As a result, 10 additional biopsies were taken, and 90% of these new lesions were confirmed.

"Therefore, 5 of 6 patients with suspected additional disease were confirmed," Dr. Palter said. In other words, the autofluorescent technology identified additional disease in 62.5% of the patients studied.

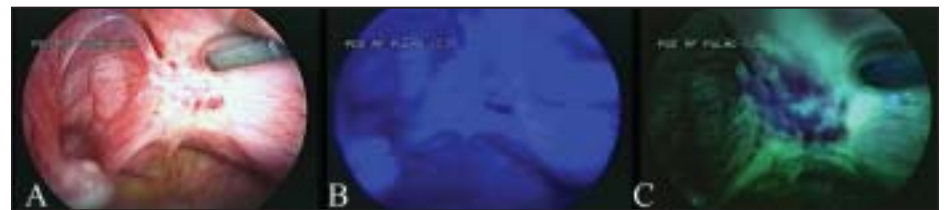"Our pilot study demonstrated the ability to visualize the endometriosis, and further studies are ongoing on clinical outcomes," noted Dr. Palter, medical and scientific director of Gold Coast IVF, Syos-

set, N.Y. He disclosed that he serves as a consultant to Karl Storz Endoscopy-America, which makes the D-Light system.

"This was the first complete use of the system in the pelvis without drug dyes for the diagnosis of endometriosis in the United States," said Dr. Palter. "Further studies are obviously required to determine the clinical outcome" of pain-free survival in patients who undergo a more complete excision of diseased tissue as a result of the imaging system.

The D-Light system has not been approved for pelvic use by the Food and Drug Administration, but it received IRB approval for the study. It's not yet known whether autofluorescence endoscopy will provide enough information on the depth of the lesion to know whether ablative or surgical excision will be the most appropriate treatment, he said.

In contrast to the classical dark, black, hemosiderin-like endometrial lesions that can



In regular endoscopy, white light is used (A). The light is filtered from white into a narrower, blue range (B). Reflected blue light is filtered; endometrial lesions may appear dark blue if they block the green background fluorescence, now visible (C).

be seen with normal white light, there are subtle and atypical clear, red, and white endometrial lesions with high metabolic activity that are now recognized as earlier forms of the disease. These atypical forms are found in most patients. The new autofluorescence endoscope system could improve the ability to see these lesions and render their detection less dependent on the ability and experience of the user, he said.

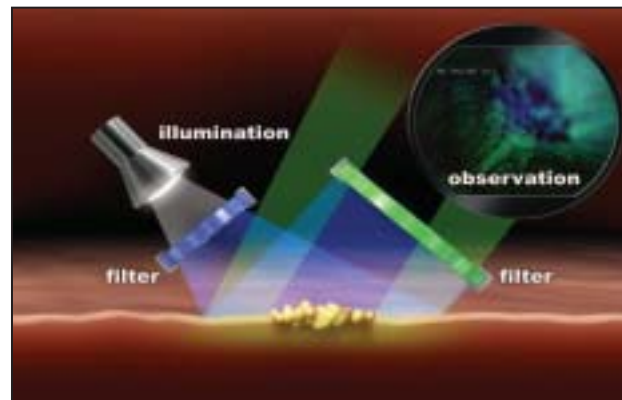
The standard method for the diagnosis of endometriosis is by direct, white-light illumination of lesions during laparoscopy with confirmation by biopsy.

Under normal white light illumination, most light is reflected back from the tissue at the same wavelength. A small percentage of photons are absorbed by the tissue and released at another wavelength in the process of autofluorescence. In regular endoscopy, the autofluorescent light is present but cannot be seen, since

it is overpowered by the large amount of white light, Dr. Palter said.

An autofluorescence endoscope differs from a regular endoscope by the use of two additional colored filters that enhance the visualization of autofluorescent light. The first one filters the light illuminating the tissue from the wavelength range in a normal white light mode into a narrower, blue-light range, which intensifies the amount of fluorescent light that is released from the tissue at a higher wavelength. Another filter blocks reflected light with a wavelength shorter than 450 nm. This second filter blocks more than 99.5% of the reflected blue light, enhancing the small amount of fluorescent light emitted from the tissue so that it can be visualized. Endometrial lesions may appear dark blue if they block the green background fluorescence or they may be hyperfluorescent with an increased level of fluorescence, compared with the background.

Further details of the studies, including photos and videos of the system, are available on Dr. Palter's Web site and blog about future technology and medicine at <http://docinthemachine.com/afendo>. ■



An autofluorescence endoscope differs from a regular endoscope by the use of two additional colored filters.

IMAGES COURTESY DR. STEVEN F. PALTER

## Use of Ultrasound for Endometrial Cancer Screening Is Weighed

BY ROBERT FINN  
San Francisco Bureau

SANTA MONICA, CALIF. — Transvaginal ultrasound has a specificity as high as 97% in screening asymptomatic women for endometrial cancer, but its use in the general population would result in a substantial number of false positives, according to a poster presentation at the biennial meeting of the International Gynecologic Cancer Society.

Using an endometrial-thickness cutoff of 10 mm or greater results in a 97% specificity and a 56% sensitivity, wrote Dr. Ian Jacobs of University College London and his colleagues. A cutoff of 5 mm or greater would result in a specificity of 86% and a sensitivity of 82%.

Using different cutoffs, depending on whether or not a woman used hormone replacement therapy, did not appreciably change the overall sensitivity or specificity.

The risk of endometrial cancer is associated with increasing weight, a history of breast cancer, and a history of any other cancer, but the study showed that limiting screening with transvaginal ultrasound to a higher-risk group of the population would result in only a slight increase in specificity.

Incorporating information on endometrial abnormalities can increase sensitivity somewhat, but at the expense of specificity. The investigators defined endometrial abnormalities as including polyps, fluid in the cavity, and/or thickened, cystic, irregular, or heterogeneous endometrium. Using the 10-mm cutoff for endometrial thickness and/or the presence of an endometrial abnormality resulted in a sensitivity of 73% and a specificity of 90% (compared with 56% and 97% without considering abnormalities).

The study used results from the U.K. Collaborative Trial of Ovarian Cancer Screening.

Among the 38,668 asymptomatic women for whom transvaginal ultrasound results were available, 82 women were found to have endometrial cancer, including 5 with complex hyperplasia and 4 with atypical hyperplasia.

The investigators noted that current recommendations call for screening only women at especially high risk because of hereditary cancer syndromes. There is only limited enthusiasm for screening the general population, because endometrial cancer is found in stage I about 70% of the time and these patients have a relatively high 5-year survival rate of 85%. On the other hand, women diagnosed with stage Ic have a 5-year survival of 42%, and those with stage IV have a 5-year survival of 25%.

Screening of the general population would be expected to benefit those women but at the expense of significant false-positive rates that would result in some women having unnecessary diagnostic procedures. ■

## Hysteroscopy Not Implicated In Endometrial Ca Recurrence

SANTA MONICA, CALIF. — While hysteroscopy is the most accurate tool for evaluating abnormal uterine bleeding, the technique can cause the intraperitoneal spread of malignant endometrial cells. This has raised concerns that hysteroscopy might be responsible for a worse prognosis in women with endometrial cancer.

But in a poster presentation at the biennial meeting of the International Gynecologic Cancer Society, Dr. A. Ben Arie and colleagues found no evidence that hysteroscopy was associated with an increase in endometrial cancer recurrences.

The retrospective study involved 392 women provisionally diagnosed with stage I endometrial adenocarcinoma at five medical centers in Israel. Dr. Ben Arie of Kaplan Medical Center, Rehovot, Israel, and colleagues examined the women's medical records, retrieving data on mode of diagnosis, histologic type, grade and stage of the disease, and the patient's outcome.

Three different diagnostic methods were employed in the women—25% had an endometrial biopsy, 49% had uterine curettage, and 26% had hysteroscopy. Endometrial adenocarcinoma was found in 88.5% of the women, and the other 11.5% had uterine serous papillary cancer, clear cell cancer, or small cell cancer. The cancer was stage I in 81% of the women, stage II in 2% of the women, and stage III in 17% of the women.

At a mean follow-up time of 55 months (range 12-233 months), recurrences were found in 5% of the women who had hysteroscopy, 4.7% of the women who had curettage, and 13.1% of the women who had endometrial biopsy. There was no statistically significant difference in the recurrence rate among the three diagnostic methods.

The investigators concluded that hysteroscopy is safe in the assessment of abnormal uterine bleeding.

—Robert Finn