

Micrometastases Don't Hurt Melanoma Prognosis

BY FRAN LOWRY
Orlando Bureau

ORLANDO — It is possible that the presence of micrometastases on sentinel lymph node biopsy may have little clinical prognostic value when predicting the survival of patients with malignant melanoma, according to a review of 415 patients.

The overall survival of those who

had micrometastases less than 1 cm was similar to the overall survival achieved by patients with no metastases, Dr. Arun P. Venkat reported at the annual meeting of the American Society for Dermatologic Surgery.

In contrast, overall survival was significantly worse in patients who had macrometastases greater than 1 cm, said Dr. Venkat.

Micrometastases are most often de-

tected with sentinel lymph node biopsy (SLNB), whereas macrometastases can be detected clinically or with positron emission tomography/computed tomography (PET/CT).

“Improved immunohistologic techniques are making it easier to find micrometastases in malignant melanoma, so the real question is whether micrometastases are an accurate predictor of recurrences and prognosis or are we

unnecessarily upstaging patients by finding more micrometastases?” said Dr. Venkat, who is a dermatology resident at the University of Iowa Hospitals and Clinics in Iowa City.

The prognostic relevance of micrometastases versus macrometastases “has not been clearly differentiated,” he noted.

The 415 patients had been followed for at least 3 months: 73 were deemed to

Negative Stain Still Positive for Rare Malignancy

SAN FRANCISCO — The diagnosis of blastic natural killer-cell lymphoma requires a dermatopathologist who knows the typical immunohistochemical patterns of the disease and is aware of exceptions to rules.

Also called CD4-positive, CD56-positive (CD4+/CD56+) hematodermic neoplasm, the disease is a rare, aggressive malignancy that frequently presents with skin lesions. Immunohistochemical staining typically produces immunopositivity for CD4, CD56, and CD123, but rare cases have been reported of patients who tested negative in one or more of these immunohistochemical studies.

At the annual meeting of the American Society of Dermatopathology, Dr. Rajwant Malhotra and Dr. Alison L. Uzieblo reported on two cases of CD4+/CD56+ hematodermic neoplasm presenting as skin nodules and plaques. One of the cases in their poster was CD123-negative.

“Loss of CD123 expression is a distinctly unusual event” in CD4+/CD56+ hematodermic neoplasm, wrote the authors, both from the anatomic pathology department at Beaumont Hospital, Royal Oak, Mich. Given the poor prognosis associated with this disease, “it is important to be aware of this potential phenomenon when evaluating cutaneous hematolymphoid malignancies.”

One patient was a 77-year-old man who presented with skin lesions on his back and trunk. Flow cytometric analysis subsequently showed bone marrow involvement. The second patient, a 70-year-old man, had a 3-cm nodular plaque on his scalp. Further clinical evaluation found no evidence of bone marrow involvement.

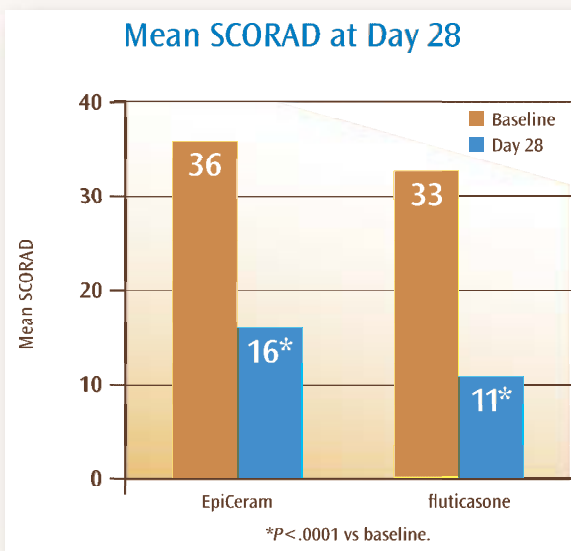
Histological examination of biopsies from both patients revealed dense dermal infiltrates composed of sheets of medium-sized cells with angulated to round nuclear contours in the dermis. The lesional cells were positive for CD4, CD43, and CD56, but only one patient's biopsy demonstrated CD123 positivity. Both showed a high proliferation rate with Ki-67 staining noted in approximately 50% of cells in one patient and 70% of cells in the other.

—Sherry Boschert

NEW EpiCeram[®] Skin Barrier Emulsion—

Deliver the efficacy of a midpotent corticosteroid without the associated long-term risks¹

There was no statistically significant difference in efficacy between EpiCeram and fluticasone propionate 0.05% cream at day 28¹



Scoring of Atopic Dermatitis (SCORAD) is a clinical tool that assesses severity and intensity of atopic dermatitis.

References: 1. Data on File. A prospective, randomized, investigator-blind, controlled, pilot study comparing the effect of EpiCeram device versus conservative standard of care therapy utilizing mid-strength topical steroid (fluticasone propionate 0.05%) in the treatment of atopic dermatitis in pediatric patients. Promius Pharma LLC, Bridgewater, NJ; 2008. 2. EpiCeram[®] [package insert]. Promius Pharma, LLC, Bridgewater, NJ; 2008.

©2008 Promius[™] Pharma, LLC.

Contraindicated in persons with a known hypersensitivity to any component of the formulation. After application, a temporary tingling sensation may occur. Please see important safety information and full prescribing information on the back page. For more information, please visit www.EpiCeram.com.