

# MRI Reveals New Epilepsy Surgery Candidates

BY MICHELE G. SULLIVAN  
Mid-Atlantic Bureau

**H**emispherectomy or cortical resection may cure catastrophic epilepsy even in a child with generalized seizures, with MRI rather than EEG identifying surgical candidates, according to Dr. Elaine Wyllie, director of the child neurology center at the Cleveland Clinic Children's Hospital.

Candidates for the surgery are children in whom the epileptogenic focus is a unilateral brain lesion that probably occurred prenatally, perinatally, or during infancy. "These extensive congenital or early-acquired unilateral brain lesions may produce generalized—or even contralateral—maximum epileptiform discharge patterns on EEG," she said in an interview. "Despite these EEG findings, you can still get favorable surgical results in some cases, if you have a clear unilateral brain lesion on MRI with side-appropriate semiology." Children with this clinical picture are typically turned away from surgery.

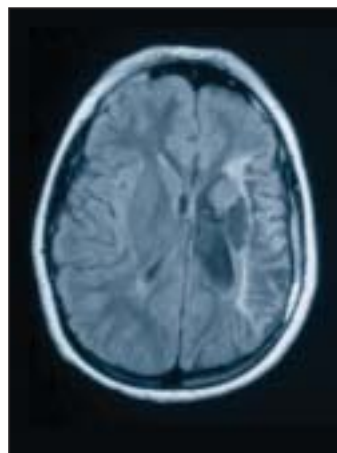
In the 1990s, she said, a team from the University of California, Los Angeles, began to report surgical cures of infantile spasms and hypsarrhythmia—that is, seizure types with diffuse EEG patterns (*Epilepsia* 1993;34:764-71). Other centers, including the Cleveland Clinic, soon were replicating the results. "When a lesion occurs this early, it's actually interacting with the time-locked processes of brain development: the formation of the cortex, the migration of neurons, the increase in synaptogenesis, and myelination," Dr. Wyllie said. "And when the lesion interacts with this dynamic process, you get the development of epilepsy that looks different—electrically and clinically—from what you see when a fixed electrical brain system acquires a lesion." In fact, she said, the healthier side of the brain can sometimes express more pronounced epileptiform discharges than does the injured side.

Although the EEG findings—considered in isolation—may suggest that the child has generalized seizures, the seizure semiology, motor deficits, and MRI all point to a focal source. This seeming contradiction makes hemi-

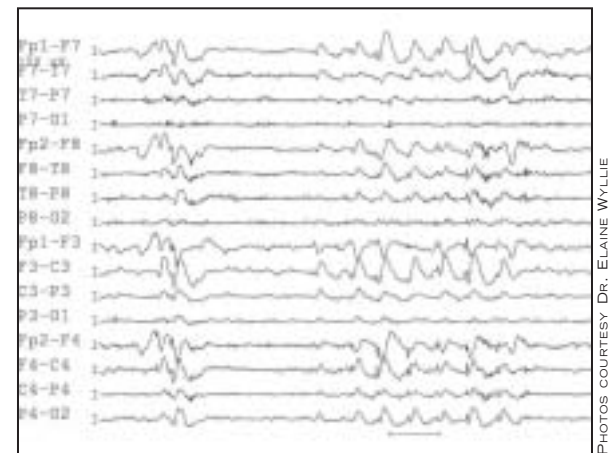
spherectomy a difficult decision for both physician and parent.

At a recent meeting of the Child Neurology Society, Dr. Wyllie reported some preliminary findings from a retrospective study of 50 such children, all of whom underwent functional hemispherectomy or cortical resection at the Cleveland Clinic in 1999-2004. All had ictal or interictal epileptiform discharges that were either generalized or maximum contralateral to the surgical site, and early brain lesions that were unilateral or very strongly asymmetrical. Even though all of the children had an obvious focus for their seizures, their generalized EEG patterns had eliminated some of these patients as surgical candidates at other centers they had visited.

One of her first such patients, a 12-year-old, was a prime example, Dr. Wyllie said. His seizures began when he was 1 month old, and by the time he was 5 months old, he had developed a right hemiparesis with no fine finger movement. By 9 years of age, he had developed medically refractory epilepsy, with daily right arm tonic seizures. His MRI showed a middle cerebral artery infarct, which probably occurred between 34 weeks' gestation and birth, with left-sided gliosis and cortical and subcortical encephalomalacia, all of which corresponded with his seizure semiology and neurologic exam. But his ictal and interictal EEGs showed generalized discharges, mainly in the right hemisphere. "We had to ignore these features on EEG and go with what we saw on the MRI, the exam, and the seizure type," she said. "He had a left functional hemispherectomy in 1999, and has been off all medications since 2001. He hasn't had any seizures since, has gradu-



Encephalomalacia from a perinatal infarction is shown on MRI (left); perioperative interictal EEG in the same patient shows generalized slow spike-wave complexes (right).



PHOTOS COURTESY DR. ELAINE WYLLIE

ated from high school, and is now learning a trade."

Many of the other 49 patients with focal lesions and diffuse EEGs had a similarly good outcome, she said. Her preliminary results, based on each patient's last follow-up, showed that 72% had become seizure free since their surgery. Major improvements—resolution of catastrophic epilepsy with some remaining seizures—occurred in several of the other patients, with only 6 of the original 50 experiencing little or no improvement. The three wound infections resolved with antibiotics and cranioplasty, one hydrocephalus that required a shunt, and one late expanding cyst that required fenestration. The next step is to further define the best surgical candidates, she said. Her current work-up includes the following considerations:

- ▶ Imaging must identify an extensive brain lesion that probably occurred pre- or perinatally or during infancy.
- ▶ The lesion must be capable of epileptogenesis.
- ▶ The lesion must be unilateral or strongly asymmetric.
- ▶ Seizures must be medically refractory.
- ▶ Hemispherectomy candidates must have side-appropriate motor deficit that will not be worsened by surgery.
- ▶ A video EEG can be helpful in confirming seizures. ■

## Patients' Artwork Grants Insight Into Living With Epilepsy

BY DOUG BRUNK  
San Diego Bureau

SAN DIEGO — Artwork created by persons with epilepsy can help others gain insight to the experiences of patients with the condition, Dr. Steven C. Schachter said at the annual meetings of the American Epilepsy Society and the Canadian

League Against Epilepsy. Dr. Schachter has collected more than 1,200 paintings, photographs, and other works of art by 52 artists with epilepsy from around the world. "I often show the art when I'm seeing other patients to help them verbalize feelings," he said.

Many of the works in his collection appear in "Vision: Artists Living With Epilepsy" (Elsevier Science and Technology, 2003), a book edited by Dr. Schachter. All royalties from sales of the book support the Epilepsy Foundation.

Studying the art of people with epilepsy serves to recognize their contributions to society, but it also raises certain research questions, said Dr. Schachter, professor of neurology at Harvard Medical School, Boston, and director of neurotechnology at the Center for Integration of Medicine and Innovative Technology, Boston. "For example, are people with epilepsy particularly likely to engage in artistic activities?" he asked. "Is there a link between epilepsy and creativity? If so, what are the epilepsy-specific variables that are involved?"

While he did not offer answers to those questions during his presentation, he did discuss four general themes that emerge in the artwork in his collection:

- ▶ **Seizures and the postictal state.** Many works represent the artists' conscious ex-

periences during their seizures. One artist says during her seizures her world seems very unreal, he said. "She feels like she's walking in a dreamlike state. Her art represents this experience."

For many epilepsy patients, "the postictal state is their only clue that they've had a seizure. It can be a period of time with very intense emotional symptoms." One artist told Dr. Schachter that after having a seizure she "has an overwhelming sense that everything she knows to be present in her world is actually distant in time and space. With that comes a powerful sense of anguish, pain, and loneliness."

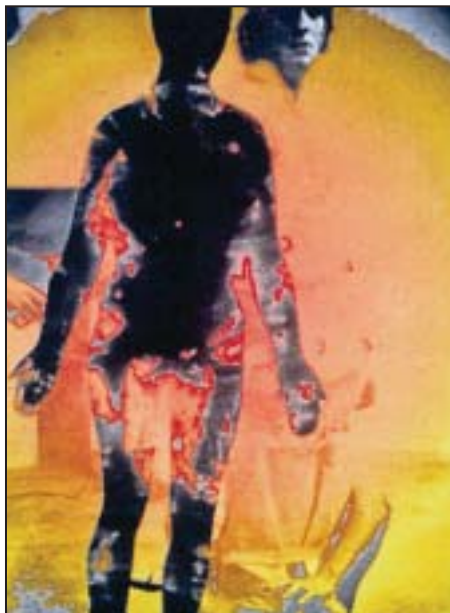▶ **Psychiatric comorbidities.** Themes that reflect anxiety and depression also are common in the artwork, and the prevalence of these conditions may be higher in people with epilepsy than in the general population. The fear of the next seizure and the fear of dying "are all common anxieties people with epilepsy have," he said. One of his patients likened the beginning of a seizure to being "in front of an oncoming train with no way to escape." Psychosis also occurs in patients with epilepsy, perhaps as a function of severity.

▶ **Psychosocial aspects of epilepsy.** These include themes of isolation from society, stigma, and reminders of living with epilepsy. "For some patients, the place

where they feel the safest is their home or bedroom, which is a common theme in the art," Dr. Schachter said.

▶ **Non-epilepsy related.** There are many artists with epilepsy "whose art has no ostensible connection to their epilepsy at all," he said. Such works serve to destigmatize epilepsy, "to emphasize that people with epilepsy ... can be creative and contribute to society. It's art for art's sake."

The presentation was part of the AES Annual Course, a program supported by an educational grant from Abbott Laboratories, Cyberonics, and GlaxoSmithKline Pharmaceuticals. ■



JENNIFER HALL

Dr. Schachter has collected over 1,200 works such as 'Transcending' (above).

## National Walk for Epilepsy in March

**T**he Epilepsy Foundation is hosting the first National Walk for Epilepsy on March 31 in Washington, D.C. The 5K walk, sponsored by Ortho-McNeil Neurologics, should help raise \$1 million to support programs "to eliminate stigma and raise awareness of epilepsy," according to the Foundation, which expects 5,000 people to participate. More information is available at: [www.walkforepilepsy.org](http://www.walkforepilepsy.org). ■