

# Dual-Energy CT May Aid Diagnosis of Gout

BY SHERRY BOSCHERT

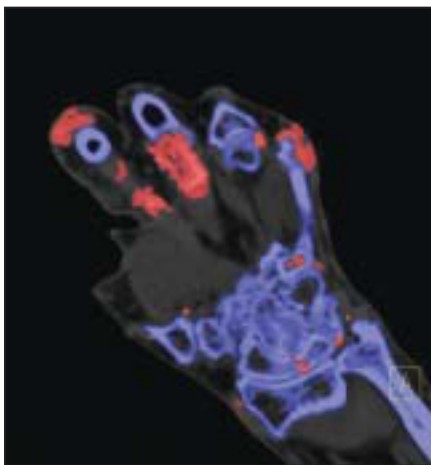San Francisco Bureau

SAN FRANCISCO — Dual-energy CT scans showed red-colored uric acid deposits in 20 consecutive patients with clinically obvious tophaceous gout but not in 10 control subjects with other nongout joint conditions.

The 100% sensitivity and specificity of dual-energy computed tomography (DECT) scans to identify uric acid deposits could provide a sorely needed accurate imaging tool to aid in the diagnosis of gout and its response to treatment, Dr. Abdullatif M. Alarfaj said at the annual meeting of the American College of Rheumatology.

DECT assesses chemical composition and provides specific color-coded displays to differentiate between uric acid (which shows up as red), calcium (blue), and other renal calculi, previous investigators have shown.

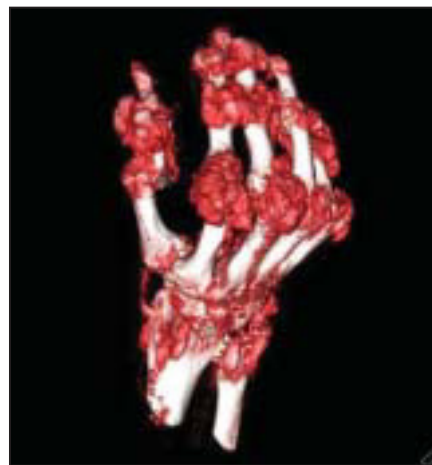The current proof-of-concept study, in addition to assessing the accuracy of DECT in gout patients, also measured the uric acid burden in peripheral joints and performed a computerized quantifi-



DECT shows uric acid deposits in red, while calcium in bone looks blue.

cation of tophus volume. The volume of uric acid deposits in each anatomic area was measured by automated volume estimation software. The sum of tophus volume in the hands, wrists, elbows, feet, ankles, and knees comprised the total uric acid volume of peripheral joints.

DECT scans identified 440 areas of urate deposition, compared with 111 areas identified on clinical examination, reported Dr. Alarfaj of the University of



A 3-D volume-rendered image of the same patient shows many tophi (red).

British Columbia, Vancouver, and his associates. The investigators have no conflicts of interest related to this study.

DECT could be useful in detecting subclinical tophus deposits and the extent of intra- and extra-articular gout, Dr. Alarfaj suggested. Treatment response might be monitored by using DECT to measure both individual tophus volume and total tophus burden.

This relatively new technology also may

prove useful in evaluating nodular lesions, diagnosing concurrent gout in patients with other arthropathies, and identifying urate deposits in body areas that are atypical for gout or challenging to assess.

An individual DECT scan can cost about one-sixth of the amount for an MRI, Dr. Alarfaj's senior investigator, Dr. Hyon Choi, said during a question-and-answer session. The DECT hardware equipment is expensive but is used for a variety of purposes, such as imaging coronary artery calcifications and renal calculi, added Dr. Choi, also of the university.

The technology provides dramatic color displays and can be used to create impressive three-dimensional images of uric acid deposits that could aid clinicians in communicating about the disease to patients with gout, he added.

The patients in the gout group of the study had an average 12-year history of the disease and nine painful joints in the previous year. The mean serum uric acid level was 492 micromol/L. The patients had a mean age of 63 years, 15 (75%) were men, and 12 (60%) were white. Comorbid conditions were present in 17 patients (85%).

## New Agents for Gout Provide Alternatives to Allopurinol

BY NANCY WALSH

New York Bureau

FORT LAUDERDALE, FLA. — The likely approval of febuxostat for the treatment of gout means that there soon will be an alternative for the underserved group of patients with severe disease who cannot tolerate allopurinol.

No new urate-lowering treatments have been approved for gout since 1964, but the advisory panel of the Food and Drug Administration voted 12-0, with 1 abstention, in favor of approval for this nonpurine selective xanthine oxidase inhibitor. Although the FDA is not required to follow the recommendations of its advisory panel, it usually does so.



Febuxostat is structurally distinct from allopurinol, another xanthine oxidase inhibitor that also exerts inhibitory activity on other enzymes involved in purine and pyrimidine metabolism, according to Dr. Robert L. Wortmann, professor of medicine, Dartmouth-Hitchcock Medical Center, Lebanon, N.H.

Experience to date with febuxostat in more than 4,000 patients has shown that, unlike with allopurinol, there appears to be no need for dose adjustment in patients with mild to moderate renal dysfunction. Dosage concerns exist for patients with renal insufficiency taking allopurinol, because of the possible occurrence of toxic epidermal necrolysis.

There also have been no reports of hypersensitivity reactions, even among patients who previously had such reactions to allopurinol, most likely because of the two drugs' differences in structure, Dr. Wortmann said at a meeting sponsored by RHEUMATOLOGY NEWS and Skin Disease Education Foundation.

In a phase III clinical trial, 81% of patients receiving 80 mg febuxostat per day had serum urate levels below 6 mg/dL after 52 weeks of therapy, compared with 39% of patients receiving 300 mg allopurinol per day (N.

Engl. J. Med. 2005;353:2450-61).

"It seems to be a very effective drug," said Dr. Wortmann, who is a consultant to Takeda Pharmaceutical Co., the manufacturer of febuxostat.

Although not all patients can tolerate allopurinol, that drug also is effective. However, it often is not prescribed in sufficiently high doses, with 97% of prescriptions in this country being for 300 mg/day or less, according to Dr. Wortmann. The drug is approved for doses up to 800 mg/day.

**'In trials [uricase] has knocked the devil out of urate levels very rapidly.'**

DR. WORTMANN

Regardless of what urate-lowering agent is chosen, the lowest dose that brings the serum urate below the target of 6 mg/dL should be used.

Another agent being investigated for gout is uricase, which converts uric acid to the more soluble allantoin. A commercially available formulation, rasburicase, is used for the treatment of tumor lysis syndrome. Although that drug is very effective for lowering serum urate levels, it carries a black box warning regarding anaphylaxis, Dr. Wortmann said.

Accordingly, two companies have been working on developing pegylated formulations, based on the principle that the polyethylene glycol would make uricase less antigenic and increase the half-life. Dr. Wortmann disclosed that he is also a consultant to Savient Pharmaceuticals Inc., the manufacturer of one of these formulations, Puricase.

"In trials this agent has knocked the devil out of urate levels very rapidly," he said. However, the number of dropouts has been high in these trials, primarily because of allergic and infusion reactions.

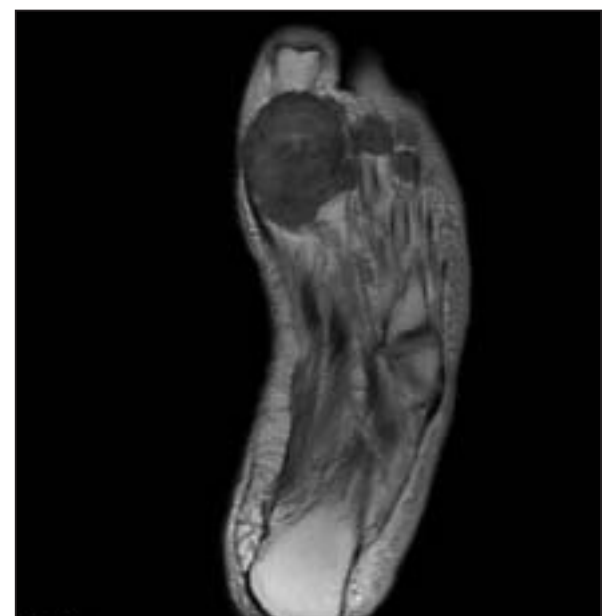
"Whether that can be alleviated by giving a more dilute form of the drug or giving it over longer periods of time, I'm not sure," he said.

There also have been a number of deaths during trials of uricase, although apparently none of these deaths could be attributed to the drug. For example, one patient who died was a 92-year-old man with severe tophaceous gout who had had three bypass surgeries and a stroke previously, and who succumbed to heart disease.

"I think the investigators were not as selective as they could have been in patient selection, which is unfortunate because this to me would be an exciting alternative for patients with severe tophaceous gout. Uricase could be given for a few doses to get the urate really low and mobilize the crystals as much as possible, and then the patient could be maintained on another agent once it's under control," he said.

SDEF and this news organization are owned by Elsevier.

For a related video with Dr. Wortmann, go to [www.youtube.com/InternalMedicineNews](http://www.youtube.com/InternalMedicineNews) (search for 63552).



A proton density image of the foot of a gout patient shows the low- to intermediate-signal tophi.