

MASTER CLASS

Know the Fetus



E. ALBERT
REECE, M.D.,
PH.D., M.B.A.

The driving force in contemporary times behind the need to evaluate the fetus is the desire of parents to know the most about their fetus as early as possible. Medical indications also may dictate when fetal evaluation is conducted and fetal development assessed.

Prior to the development of ultrasound, such assessment was not possible. However, with the advent of ultrasound technology and other developments that

have progressively increased its sophistication, ultrasound imaging has become a reality and an increasingly useful tool. It has been advancing at such a rapid rate that fetal imaging has moved from the third trimester to the second, and even to the first. Not only is fetal growth assessed, but some of the intricacies of fetal development are evaluated as well.

The invasive method of fetal evaluation has taken a similar pathway, expanding from amniocentesis to embryofetoscopy to chorionic-villus sampling to analyte markers in maternal blood. The desire to know more continues to drive the field.

Parents and their physicians call for the greatest possible degree of accuracy and

information on the developing fetus.

Fetal MRI technology is an additional tool that is fast evolving in fetal medicine to meet this desire.

At the same time, many have appreciated the limitations of ultrasound technology, which are based upon maternal obesity, fetal position, gestational age, and developmental status of the fetus.

Because of its unique technology, MRI is able to provide added value and new information that was not heretofore possible using current ultrasound technology.

It is in this light that we believe that a Master Class addressing this newest evolving technology is in order.

We have invited Dr. Ray Bahado-Singh, a professor of maternal-fetal medicine at Wayne State University in Detroit and an expert in genetics and prenatal diagnosis, to discuss fetal MRI in detail and to highlight how this new technology may further advance the diagnosis of fetal anomalies. ■

DR. REECE, who specializes in maternal-fetal medicine, is vice president for medical affairs at the University of Maryland, as well as the John Z. and Akiko K. Bowers Distinguished Professor and dean of its school of medicine. He is chair of the Association of American Medical Colleges National Colleges of Deans for 2008-2009. He is the medical editor of this column.



BY RAY BAHADO-
SINGH, M.D.

Fetal MRI's Leading Indications, Limitations

There is a widespread consensus that ultrasound is the clinical standard for the diagnosis of fetal anomalies, and a constellation of factors will ensure its central role into the foreseeable future.

Most importantly, both ultrasound technology and the expertise to perform and interpret it are now widely available. The technology also remains relatively inexpensive, compared with other modalities; its safety has been well established through both study and long-term experience; and it provides real-time visualization, as opposed to images acquired at a particular point in time. Overall, ultrasound should be the first technology employed in the evaluation of the fetal anomaly.

Still, there are well-recognized limitations to sonographic evaluation. The ability to visualize structures—and thus, the accuracy of a diagnosis—is significantly compromised, for instance, in women who are obese. This is far from a trivial concern today, as the rate of obesity in the United States is high and climbing.

Sonographic evaluation also may be limited by fetal position. Even in an average-size woman, for instance, suboptimal fetal positioning can impair proper visualization of structures.

Another common limitation is the descent of the fetal head into the maternal pelvis. Transvaginal ultrasound is an alternative approach, but the physics of the transvaginal transducer often prevents us from seeing in as many planes as would normally be desirable.

Ultrasound tends to be optimal during midpregnancy. Beyond this point, calcification of the fetal bone structure intensifies. Cranial ossification, for example, can substantially obscure the visualization of intracranial structures.

Finally, effective ultrasound evaluation requires fluid around the fetus. With oligohydramnios, the quality of the sonographic images is significantly compromised.

All told, these limitations are not infrequent or inconsequential. Clinicians commonly encounter such situations during the course of their work.

Finally, effective ultrasound evaluation requires fluid around the fetus. With oligohydramnios, the quality of the sonographic images is significantly compromised.

All told, these limitations are not infrequent or inconsequential. Clinicians commonly encounter such situations during the course of their work.

MRI Technique and Safety

Fetal magnetic resonance imaging provides excellent tissue contrast and is not limited by maternal obesity, skull calcification, or fetal position. It can image the fetus in multiple planes and accomplish this with a large field of view.

MRI can therefore play a valuable role when the findings from ultrasound are unclear or incomplete, or when there is potential for other anomalies that cannot be sufficiently visualized with ultrasound.

MRI relies on the presence of the high water content of tissues, and on the magnetic qualities of the constituent hydrogen nuclei. When tissue is placed in the strong magnetic field of an MRI machine, the hydrogen nuclei or protons move into particular alignments with the applied magnetic field.

Once the protons are lined up, radio frequency pulses are applied, causing the protons to absorb additional energy and spin on their axes of alignment. When the radio frequency pulses are discontinued, the additional energy that the protons had previously absorbed is released. It is this released energy that is transformed into an image. The quantity of energy released will vary depending on the tissue characteristics, such as the relative water and fat content.

Unlike x-ray and CT scans, MRI does not use ionizing radiation. Numerous studies and reports, including studies of MRI technicians who become pregnant, have demonstrated the safety of MRI and the lack of adverse clinical effects. The American College of Radiology published a series of white papers from 1993 to 2004 outlining MRI's safety. Thus, although the safety of MRI continues to be studied, there is no evidence to date that MRI produces harmful effects on human embryos or fetuses.

To be exceedingly cautious, most authorities and practitioners of MRI advise that it not be done in the first trimester.

Even without this extra caution, however, MRI would likely be discouraged in the first trimester because the increased noise-to-signal ratio from imaging such a small structure limits its benefit. It isn't until later in the second trimester, with increased fetal size and fat content, that the quality and resolution of the images achieve a threshold that conveys clinical benefit.

MRI's Leading Indications

MRI is indicated when there is potential for significant change in diagnosis or in patient management beyond the initial ultrasound.

Several studies from both the United States and Europe have demonstrated the clear capability of MRI to significantly modify or alter diagnosis, patient counseling, and management.

In one study of 124 fetuses with central nervous system anomalies detected initially by ultrasound, Dr. Deborah Levine of Harvard Medical School and her colleagues showed that fetal MRI led to 49 major changes in diagnosis and 27 clear changes in management,

Key Points

- ▶ MRI is a rapidly developing technology for fetal diagnosis, and maternal-fetal medicine specialists should develop expertise and collaboration with radiologists.
- ▶ Substantial clinical and research data demonstrate improvement of CNS diagnoses when MRI is performed after targeted ultrasound.
- ▶ Emerging data suggest improvement in diagnosis when MRI is used for neck and thoracic abnormalities, excluding the heart.

compared with prior ultrasound.

Suspected central nervous system anomalies—particularly brain anomalies—are, in fact, the most common indication for fetal MRI. There is some literature to support benefits of fetal MRI for other anatomical defects, but the literature provides the strongest evidence of MRI's additional benefit for CNS anomalies. Beyond the CNS, the other two main clinical indications for fetal MRI are for evaluation of the fetal neck and chest.

Among the anomalies and conditions best evaluated by fetal MRI are the following:

▶ **Ventriculomegaly.** Dilatation of the cerebral ventricles is a relatively common finding by prenatal diagnosis. Although it is usually well visualized with ultrasound, ventriculomegaly may be accompanied by other associated abnormalities that may remain undetected with sonographic evaluation.

When ventriculomegaly is isolated with no other accompanying anatomical defects, the long-term prognosis is excellent. If there are associated abnormalities, however, the prognosis is significantly compromised, with much worse neurodevelopmental outcomes.

Fetal MRI can help identify those additional abnormalities. Studies from Europe and in the United States have documented significant percentages of cases in which apparently isolated ventriculomegaly was identified on the ultrasound, but was then found to be associated with additional anomalies on the follow-up MRI.

Even in cases with borderline ventricular dilatation, subtle but significant developmental abnormalities are frequently overlooked by ultrasound. MRI diagnosis can facilitate better counseling and prognostication regarding outcome, and can aid in the timely development of management strategies.

Continued on following page

Continued from previous page

► **Other brain anomalies.** MRI can be advantageous for precisely visualizing deep structures of the brain, especially as gestational age advances and the skull becomes calcified. Sometimes, MRI enables visualization of deeper structures—such as the optic chiasma, pituitary stalk, and the pituitary—that are not visible on ultrasound.

Fetal MRI is also advantageous for visualizing subtle lesions of the brain, such as parenchymal infarcts and hemorrhage, and other abnormalities of cortical development. Such subtle anomalies can nevertheless be very consequential to long-term neurologic performance.

In our institution, we order an MRI whenever we see an anomaly of the brain. A persistently and significantly small fetal head with normal-appearing sonographic anatomy may, for example, reveal a lissencephaly syndrome on MRI exam. In patients with a significant family history of brain abnormalities, a confirmatory MRI of the fetal brain, despite a normal sonographic appearance, may be justifiable.

► **Masses in the neck.** MRI is thought to be particularly useful in assessing masses of the fetal neck and the potential for airway obstruction. Limitations of tissue differentiation on ultrasound may preclude a determination of the extent of infiltration of a neck mass. The panoramic view and tissue differentiation of the MRI may overcome this limitation.

These qualities are used to good advantage in determining whether a neck mass is infiltrating or obstructing the fetal airway, and whether it has the potential to prevent spontaneous breathing at delivery. Should such a situation be confirmed prenatally, an EXIT (ex utero intrapartum treatment) procedure can be planned. In this procedure, the fetus's head and shoulders are delivered and the placenta is left attached (maintaining umbilical circulation and fetal oxy-

genation) while a surgical intubation or tracheoscopy procedure is performed.

► **Diaphragmatic hernia.** Congenital diaphragmatic hernia is among the most common congenital thoracic lesions. Herniation of the abdominal viscus and organs into the chest can lead to compression of the lungs and lung hypoplasia at birth, precluding normal respiration. When the liver is also herniated into the chest, the chances of survival are sharply reduced.

Although possible, it can be difficult to determine herniation of the liver into the chest with ultra-

and expertise in fetal MRI also are significantly restricted, compared with ultrasound. Furthermore, MRI technology is significantly more costly than ultrasound at this time.

None of these limitations is immutable. All will likely be addressed or at least attenuated with the passage of time.

Just as important will be the development of a team approach to the use of MRI for fetal anomaly detection. Such an approach would involve embracing the expertise of the obstetrician in fetal anatomy and fetal

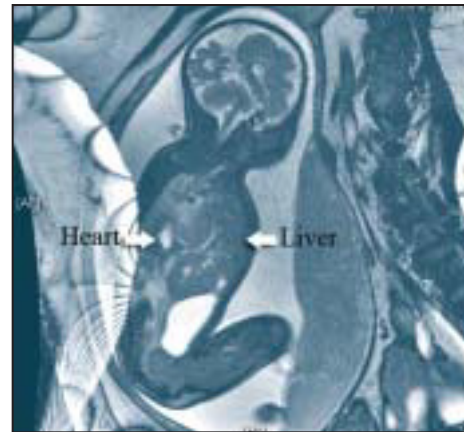
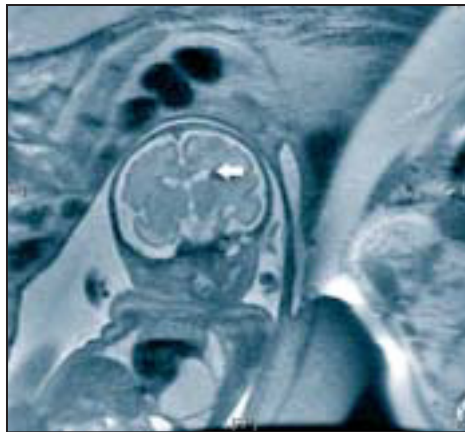
anomalies in general. The interpretation of fetal MRI images should involve not only radiologists and pediatric subspecialists, such as pediatric neurologists, but also fetal medicine specialists working together.

The greatest promise of fetal MRI lies with further advances in so-called functional MRI. This has the potential to provide information not only about structural features of the anatomy, but about the function of various tissues as well. MRI studies could capitalize, for instance, on the fact that tissue that is injured or developmentally abnormal will have differences in metabolism, compared with normal tissue.

For example, animal studies have shown that the MRI signal of oxygenated hemoglobin is different from the MRI signal of deoxygenated hemoglobin. Utilizing such differences in fetal MRI imaging could enable us to identify oxygen deprivation in fetal and placental tissues.

Advances with MRI spectroscopy, moreover, could provide us with further detailed information on tissue metabolism. Collectively, such advances in MRI could revolutionize research and ultimately clinical assessment of the fetus. ■

DR. BAHADO-SINGH stated he had no conflict of interest relevant to this article.



The fetal MRI at left shows a subependymal tuber consistent with tuberous sclerosis. At right is a congenital diaphragmatic hernia with liver herniation into the chest.

sound. MRI easily identifies thoracic displacement of the liver and therefore has prognostic value in congenital diaphragmatic hernia.

Limitations, Future Promise

Prenatal MRI does, however, have limitations. Because the technique is based on contrast between water and fat/lipids, it generally does not provide good quality images before about 24 weeks of gestation—a time period in which neurons, for instance, have not yet undergone significant myelination. Ultrasound, in contrast, tends to be quite effective earlier in pregnancy, which is a distinct advantage.

Availability of MRI technology and specific interest

Prepregnancy Obesity: Risk Factor for Postpartum Depression

BY DOUG BRUNK

SAN DIEGO — Prepregnancy obesity is an independent risk factor for postpartum depression, a large analysis demonstrates.

Common pregnancy stressors such as divorce or separation or being involved in a physical fight also were found to increase the risk.

“While I advocate that we should screen all women for depression, I think there are subsets of women whose risk is so high that we should either be identifying ways to prevent depression in this group or carry out early targeted surveillance and treatment,” Dr. D. Yvette LaCoursiere said in an interview during a poster session at the annual meeting of the Society for Maternal-Fetal Medicine.

“So if a woman comes to pregnancy with a BMI of greater than 35 kg/m² who has psychosocial stressors, she may have a risk of postpartum depression of 40%-60%. Perhaps that population should be targeted, both for research and for clinical purposes,” she said.

Previous research has shown that women with a history of depression are at increased risk of developing postpartum depression, but the possible association between prepregnancy obesity and

subsequent postpartum depression has not been sufficiently studied, said Dr. LaCoursiere of the department of obstetrics and gynecology at the University of California at San Diego.

She and her associate, Dr. Michael W. Varner of the division of maternal-fetal medicine at the University of Utah, Salt Lake City, followed 1,053 women who were delivered of a term, singleton, live-born infant at one of four hospitals in Utah between 2005 and 2007.

At intake, the researchers obtained demographic and anthropomorphic information and pregnancy stressors, in addition to a psychiatric, medical, obstetric, and family history. Participants were also asked to complete the Pregnancy Risk Assessment Monitoring System (PRAMS).

Self-reported prepregnancy body mass index was stratified by the World Health Organization classification system for underweight (less than 18.5 kg/m²), normal weight (18.5-24.9 kg/m²), preobese (25-29.9 kg/m²), obese class I (30-34.9 kg/m²), obese class II (35-39.9 kg/m²), and obese class III (40 kg/m² or greater).

At 6-8 weeks after delivery, the women were asked to complete the Edinburgh Postnatal Depression Scale. Postpartum depression was defined as a score of 12 or more.

Dr. LaCoursiere reported that the rate of postpartum depression was directly related to the extremes of body mass index. For example, the rates of postpartum depression among those in the underweight, normal weight, and preobese groups were 18%, 14%, and 19%, respectively, while the rates among those

The rate of postpartum depression was directly related to the extremes of body mass index: The rates in the underweight, normal weight, and preobese groups were 18%, 14%, and 19%.

in the obese class I, class II, and class III groups were 19%, 32%, and 40%, respectively.

After the researchers controlled for demographic, psychological, medical, and obstetrical risk factors, the overall adjusted odds ratio of postpartum depression was 2.87 for obese class II women and 3.94 for obese class III women.

In the PRAMS stressors component of the study, Dr. LaCoursiere and Dr. Varner found that common pregnancy stressors increase the risk of postpartum de-

pression. For example, the adjusted odds ratio for postpartum depression among women who reported partner-associated stressors such as divorce or arguing more than usual was 2.61, while the adjusted odds ratio for those who reported traumatic stressors such as being homeless or being involved in a physical fight was 1.66.

The adjusted odds ratio for those who reported both types of stressors was 8.48.

Fewer than half of the study participants (44%) reported that their clinician asked about their mood during pregnancy, while 54% reported that they were asked about their mood during the postpartum period.

Dr. LaCoursiere acknowledged certain limitations of the study, including the self-reported height and weight data and the fact that while women who were being actively treated for depression were excluded, the questionnaire was not administered antepartum or immediately post partum. Therefore, she said, “this cohort may represent women who were depressed antenatally and continued to have antenatal depression into the postpartum period.”

Dr. LaCoursiere reported that she had no conflicts to disclose. ■