

Brevoxyl®-4 Creamy Wash (benzoyl peroxide 4%)

Brevoxyl®-8 Creamy Wash (benzoyl peroxide 8%)

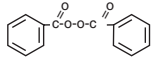
ACNE WASH FOR TOPICAL USE

Rx only

Rx only

DESCRIPTION

Brevoxyl-4 Creamy Wash and Brevoxyl-8 Creamy Wash are topical preparations containing benzoyl peroxide as the active ingredient. Brevoxyl-4 Creamy Wash and Brevoxyl-8 Creamy Wash contain: 4% and 8% Benzoyl Peroxide, respectively, in a lathering cream vehicle containing Cetostearyl Alcohol, Cocamidopropyl Betaine, Corn Starch, Dimethyl Isosorbide, Glycerin, Glycolic Acid, Hydrogenated Castor Oil, Imidurea, Methylparaben, Mineral Oil, PEG-14M, Purified Water, Sodium Hydroxide, Sodium PCA, Sodium Potassium Lauryl Sulfate, Titanium Dioxide. The structural formula of benzoyl peroxide is:



CLINICAL PHARMACOLOGY

The exact method of action of benzoyl peroxide in acne vulgaris is not known. Benzoyl peroxide is an antibacterial agent with demonstrated activity against *Propionibacterium acnes*. This action, combined with the mild keratolytic effect of benzoyl peroxide is believed to be responsible for its usefulness in acne. Benzoyl peroxide is absorbed by the skin where it is metabolized to benzoic acid and excreted as benzoate in the urine.

INDICATIONS AND USAGE

Brevoxyl-4 Creamy Wash and Brevoxyl-8 Creamy Wash are indicated for use in the topical treatment of mild to moderate acne vulgaris. Brevoxyl-4 Creamy Wash and Brevoxyl-8 Creamy Wash may be used as an adjunct in acne treatment regimens including antibiotics, retinoic acid products, and sulfur/salicylic acid containing preparations.

CONTRAINDICATIONS

Brevoxyl-4 Creamy Wash and Brevoxyl-8 Creamy Wash should not be used in patients who have shown hypersensitivity to benzoyl peroxide or to any of the other ingredients in the product.

PRECAUTIONS

General — For external use only. Avoid contact with eyes and mucous membranes.

AVOID CONTACT WITH HAIR, FABRICS OR CARPETING AS BENZOYL PEROXIDE WILL CAUSE BLEACHING.

Carcinogenesis, Mutagenesis, Impairment of Fertility — Based upon all available evidence, benzoyl peroxide is not considered to be a carcinogen. However, data from a study using mice known to be highly susceptible to cancer suggest that benzoyl peroxide acts as a tumor promoter. The clinical significance of the findings is not known.

Pregnancy: Category C — Animal reproduction studies have not been conducted with benzoyl peroxide. It is also not known whether benzoyl peroxide can cause fetal harm when administered to a pregnant woman or can affect reproduction capacity. Benzoyl peroxide should be used by a pregnant woman only if clearly needed.

Nursing Mothers — It is not known whether this drug is excreted in human milk. Because many drugs are excreted in human milk, caution should be exercised when benzoyl peroxide is administered to a nursing woman.

Pediatric Use — Safety and effectiveness in children below the age of 12 have not been established.

ADVERSE REACTIONS

Contact sensitization reactions are associated with the use of topical benzoyl peroxide products and may be expected to occur in 10 to 25 of 1000 patients. The most frequent adverse reactions associated with benzoyl peroxide use are excessive erythema and peeling which may be expected to occur in 5 of 100 patients. Excessive erythema and peeling most frequently appear during the initial phase of drug use and may normally be controlled by reducing frequency of use.

DOSAGE AND ADMINISTRATION

Shake well before using. Wash the affected areas once a day during the first week, and twice a day thereafter as tolerated. Wet skin areas to be treated; apply Brevoxyl-4 Creamy Wash or Brevoxyl-8 Creamy Wash, work to a full lather, rinse thoroughly and pat dry. Frequency of use should be adjusted to obtain the desired clinical response. Clinically visible improvement will normally occur by the third week of therapy. Maximum lesion reduction may be expected after approximately eight to twelve weeks of drug use. Continuing use of the drug is normally required to maintain a satisfactory clinical response.

HOW SUPPLIED

Brevoxyl-4 Creamy Wash is supplied in 170.1 g (6.0 oz) tubes NDC 0145-2474-06.
Brevoxyl-8 Creamy Wash is supplied in 170.1 g (6.0 oz) tubes NDC 0145-2484-06.

Store at controlled room temperature, 15°-30°C (59°-86°F).

US Patent No. 6,433,024.
87384 Rev. 0904



Stiefel Laboratories, Inc.
Coral Gables, FL 33134

References:

1. IMS/September 2006 — Single Agent BPOs Only.
2. Whitbeck N, Fraser J, Thompson C. An *In Vitro* Kill Rate study against *P. acnes* comparing three benzoyl peroxide wash products. Presented at: 64th Annual Meeting of the American Academy of Dermatology; March 2006; San Francisco, Calif. Poster 107.
3. Data on file, [In Vitro Kill Rate study against *P. acnes*, April 2005], August C. Stiefel Research Institute, Inc.
4. Del Rosso JQ, Bikowski JB, Desai A, Hawkes S. Management of truncal acne vulgaris: a double-blind, randomized trial evaluating the clinical efficacy and tolerability of benzoyl peroxide 8% wash used as monotherapy or in combination with topical clindamycin 1% foam or oral doxycycline monohydrate. Presented at: 64th Annual Meeting of the American Academy of Dermatology; March 2006; San Francisco, Calif.

Brevoxyl is a registered trademark of Stiefel Laboratories, Inc., and Research in Dermatology is also a trademark of Stiefel Laboratories, Inc. Triaz is a registered trademark of Medicis Pharmaceutical Corporation.

Less-Painful Tests May Suffice in First UTIs

BY PATRICE WENDLING

Chicago Bureau

Dimercaptosuccinic acid renal scanning and high serum procalcitonin accurately predict vesicoureteral reflux in children with a first febrile urinary tract infection, according to data from two new studies appearing in the January issue of the *Journal of Pediatrics*.

An accurate predictor of vesicoureteral reflux (VUR) in children with a first febrile urinary tract infection (UTI) could help avoid unnecessary voiding cystourethrograms (VCUGs). Although a VCUG is routinely recommended for all children with a first febrile UTI, it exposes them to radiation, is painful and expensive, has been associated with a risk of iatrogenic UTI, and is often refused by parents.

“Neither [study] can be considered definitive, yet both are exciting work which may well change practice in the future,” Dr. Thomas Welch, chair of pediatrics at the State University of New York, Syracuse, said in an accompanying editorial (*J. Pediatr.* 2007;150:A3).

The first study was a 10-year retrospective review of 142 children under age 2 years who presented with an initial UTI and underwent both a VCUG and technetium-99m-labeled dimercaptosuccinic acid (DMSA) renal scan at a tertiary care general hospital. There were 77 boys and 65 girls.

Of these, 139 (98%) children had either positive leukocyte esterase or microscopic evidence of pyuria and 3 (2%) did not have pyuria but were positive for nitrite (*J. Pediatr.* 2007;150:96-9).

Results of DMSA scanning obtained within 2 days after diagnosis indicated that 99 (70%) had findings compatible with acute pyelonephritis and 2 (1.4%) had evidence of previous renal scarring.

VCUG performed 1 month after diagnosis showed evidence of VUR in 42

(29.6%) children. A total of 63 renal units exhibited reflux on VCUG, including 45 with grade I, II, or III reflux, and 18 with grade IV or V.

The sensitivity and specificity of abnormalities on DMSA renal scan for detecting the presence of VUR on VCUG were 88% and 36%, Dr. Min-Hua Tseng and colleagues from the department of pediatrics, Tri-Service General Hospital, National Defense Medical Center, in Taipei, Taiwan, reported. Positive and negative predictive values were 37% and 88%, respectively.

The authors acknowledge the limitations of a retrospective study, including the possibility of selection bias that might have resulted in the extraordinarily high rate of high-grade reflux.

“Nonetheless, we believe that the data indicating that a normal DMSA renal scan [eliminates] the need for VCUG in evaluating young children after first UTI is so striking that it is likely real,” they wrote.

The second study was a secondary analysis of prospective hospital-based cohort studies of 398 patients, aged 1 month to 4 years, with a first febrile UTI conducted at eight centers in seven European countries.

Procalcitonin (PCT), a recently identified early marker of bacterial infection, was prospectively measured in serum at admission with the LUMItest PCT immunoluminometric assay or the BRAHMS PCT-Q semiquantitative rapid test (*J. Pediatr.* 2007;150:89-95).

Their mean age was 13 months. VUR was diagnosed in 101 (25%) children, and it was grade 3 or higher in 46 (12%). The median serum concentration was significantly higher in children with VUR than

it was in those without (1.6 ng/mL vs. 0.7 ng/mL) and increased significantly with the VUR grade, Dr. Sandrine Leroy of Saint-Vincent de Paul Hospital and Université Paris Descartes in Paris and associates reported.

High PCT, defined as 0.5 ng/mL or greater, was significantly associated with VUR (odds ratio 2.3). The association remained significant (OR 2.5) in a logistic regression analysis of 368 patients, even after adjusting for such cofactors as family history of uropathy, male gender, young age, urinary tract dilation on ultrasonography, high serum C-reactive protein at admission, and urine collection technique.

A high PCT level predicted VUR with high sensitivity: 75% for all-grade VUR and 100% for grade 4 or 5 VUR. Specificity was 43% regardless of VUR grade.

Even though high PCT did not offer 100% sensitivity for the prediction of all grades of VUR, the authors propose that the current systematic screening strategy for VUR be replaced with a PCT-based selective approach.

“One way to deal with this lack of [PCT] sensitivity is to accept that VUR will remain undiagnosed for some patients after a first febrile UTI. The potential adverse consequences of this practice should be balanced against the debatable efficacy of treatments (secondary antibiotic prophylaxis and surgery) for children with VUR and the possibility that low-grade VUR and even high-grade VUR can spontaneously disappear,” the authors said.

Additionally, a PCT-based approach would reduce overall costs by 30% by averting 38% of routine VCUGs, which cost about \$150 per test, compared with about \$15 per PCT, the authors concluded. ■

DMSA Scans Challenged as Pyelonephritis Dx

BY DOUG BRUNK

San Diego Bureau

LAS VEGAS — Although renal cortical scintigraphy remains the accepted standard for diagnosing pyelonephritis—with a sensitivity of 92% and a specificity of 100%—it’s far from perfect, Dr. Melvin O. Senac Jr., said at a meeting sponsored by the American Academy of Pediatrics’ California Chapters 1, 2, 3, and 4 and the AAP.

First, it’s difficult to tell scars from pyelonephritis on renal cortical scintigraphy using dimercaptosuccinic acid (DMSA).

It’s also expensive, around \$700 per scan. Finally, because renal damage is already done, the scan may not change the approach to managing these patients.

“The jury’s still out on DMSA [scans],” said Dr. Senac, medical director and chief of radiology at Children’s Hospital San Diego. “I wouldn’t recommend it routinely.”

He went on to note that ultrasounds in children with clinical evidence of pyelonephritis are usually normal, and vesicoureteral reflux occurs 35%-40% of the time.

One episode of pyelonephritis produces a 10% chance of renal scarring, while four episodes result in a 58% chance of renal scarring.

In a study of 111 children with clinical findings of pyelonephritis, DMSA scans detected positive renal changes indicative of pyelonephritis in 67% of patients. The rest (33%) were normal (*J. Pediatr.* 1994;124:17-20). In addition, 64% of the patients had scarring at 1-year follow-up, and 39% had vesicoureteral reflux.

In light of the findings, the researchers recommended that all children with clinical signs of pyelonephritis undergo DMSA scans. However, Dr. Senac said that current medical evidence does not warrant such a practice.

“If I had data to support it, maybe I could recommend following this protocol,

but as of 2006, I just can’t,” Dr. Senac commented.

An “overlooked” way to diagnose pyelonephritis is by CT scan. “It’s just as good as a DMSA renal scan,” he said. “I’m not advocating that, but it’s easy when we have a child with right abdominal pain.”

He acknowledged that many questions exist about the best way to diagnose pyelonephritis and other urinary tract infections in infants.

“Is ultrasound necessary in the imaging workup? That really needs to be addressed once and for all,” said Dr. Senac, also of the department of radiology at the University of California, San Diego.

“Even more important, is there evidence-based value of prophylaxis in reducing reinfections and preventing renal scarring?” he asked. “That is a critical question. It needs to be a well-designed study with placebo control to see if prophylaxis is truly helping. We think it does, but there is not good evidence-based medicine on that.” ■