

NEUROSCIENCE TODAY, NEUROLOGY TOMORROW

Postnatal Gene Therapy Found Effective in SMA Mouse

Spinal muscular atrophy, a disease for which there is currently no effective treatment, might one day yield to gene replacement therapy. Two recent studies offer some intriguing insights into possible future directions of work in this field.

Early postnatal delivery of the gene for survival motor neuron 1 protein substantially increased survival rates and motor function in mice that were bred to display the spinal muscular atrophy.

Previous attempts to improve the long-term survival of mice that lack functional copies of the survival motor neuron 1 (SMN) gene have been unsuccessful, increasing survival only a few days to several weeks beyond the 15-day median life span of the mouse model of spinal muscular atrophy (SMA). But in two new studies, researchers increased the life span of the mice to beyond 250 days.

Both research groups used self-complementary adeno-associated virus vectors constructed with SMN (scAAV-SMN) to transduce lumbar spinal motor neurons and increase SMN protein levels in the brain and spinal cord, and—in the setting of intravenous administration—the muscles and vascular endothelium.

SMA in humans is caused by autosomal recessive inheritance of mutated SMN. “Although SMA children are often asymptomatic at birth, newborn screening that can detect SMA has been developed, supporting the feasibility of delivering SMN-scAAV9 to affected children,” Kevin D. Foust, Ph.D., of the Research Institute at Nationwide Children’s Hospital, Columbus, Ohio, and his colleagues wrote in their report (Nat.

Biotechnol. 2010 Feb. 28 [doi:10.1038/nbt.1610]).

They found that a single intravenous injection of scAAV9-SMN into 1-day-old SMA mice significantly improved their motor function and locomotive abilities. It also significantly improved their weight, but only to half that of control mice, likely because of incomplete transduction of all cells, wrote the researchers. Their work

was funded with support from the Miracles for Madison Fund and the National Institute for Neurological Disorders and Stroke.

Aside from the mice that were euthanized for further analyses or died from an incidental cause, all lived beyond 250 days. By days 90-99, mice treated with scAAV9-SMN had fully restored neuromuscular transmission at neuromuscular junctions and a marked reduction in the accumulation of neurofilament at the junctions. If treatment was withheld until postnatal day 2, there was no difference in therapeutic effect, but if treatment was administered on postnatal

day 5, survival was limited to 30 days. SMA mice that received treatment on postnatal day 10 were indistinguishable from those that did not receive scAAV9-SMN.

In a second study, Marco A. Passini, Ph.D., and his colleagues at the Genzyme Corp., Framingham, Mass., injected a similar SMN-integrated scAAV vector, scAAV8-SMN, into the cerebral lateral ventricles and the upper lumbar spinal cord of newborn SMA mice. They survived to a median of 157 days, gained weight, and were ambulatory throughout life (J. Clin. Invest. 2010 [doi:10.1172/JCI41615]).

At the age of 16 days, SMA mice treated with scAAV8-SMN expressed SMN at levels about 60%-90% of those seen in wild-type mice. At ages 58-66 and 120-220 days, the mice had SMN levels in the lumbar and thoracic segments that met or exceeded the levels in wild-type mice. At all time points, SMN

levels were relatively low in the cervical spinal cord.

Improvements in the number of collapsed neuromuscular junctions were seen at 16 days of age in the quadriceps and intercostal muscles of SMA mice treated with scAAV8-SMN, but the number of these non-functional junctions later increased in mice that lived to 216-269 days.

Previous studies attempting treatment of SMA in mice have reported necrosis of the extremities and internal tissues. Dr. Passini and his colleagues observed a “very mild” necrosis of the distal hind legs after treatment that did not require euthanasia. Most (60%) mice in that study were sacrificed because of a sudden appearance of respiratory distress.

Dr. Foust and his coauthors reported only vascular necrosis of the pinna after treatment with scAAV9-SMN.

Dr. Smith’s comment: Gene replacement therapy is the holy grail of a number of life-threatening inherited neurological diseases. Inroads on new treatments have been made for Duchenne’s muscular dystrophy and Pompe’s disease, but not for hereditary anterior horn cell diseases such as the autosomal recessive SMAs.

Attempts to improve muscle function and increase the expression of survival motor neuron 1 (SMN1) using inhibitors of histone deacetylase have yielded only modest results in human subjects with SMA types III or IV. However, in the current studies, researchers were able to increase motor function and survival rates substantially.

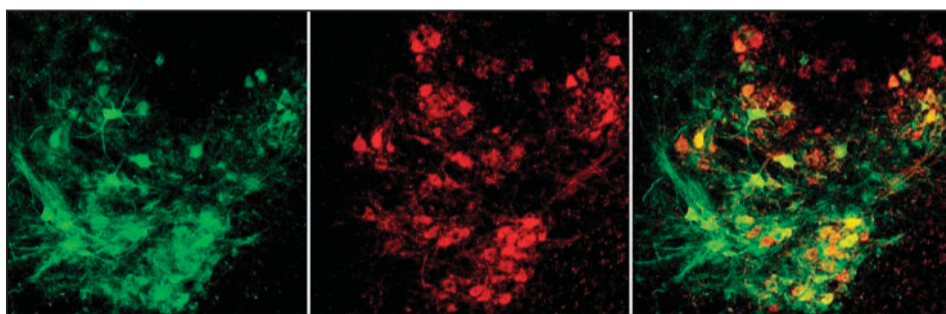
The promising results obtained by Dr. Foust’s and Dr. Passini’s research teams are an early step in the long road of seeking to establish gene replacement therapy as a viable treatment in patients with SMA. Even so, they are a ray of hope on what has been a very dark horizon for families and their loved ones diagnosed with one of these serious disorders. The field anxiously awaits (with appropriately cautious optimism) publication of additional efforts to take gene replacement therapy of SMA (and perhaps in time other inherited motor neuronopathies) closer to the goal of efficacious treatment. ■

Clinical perspective by Dr. Smith, associate professor of neurology, director of the sensory laboratory, and course director for clinical neurophysiology at Mayo Clinic, Arizona

Research report by Jeff Evans, Managing Editor



BY BENN E. SMITH, M.D.



A monkey’s motor neurons (middle, red) were successfully transduced (left, green; right, merged) 25 days after an intravenous injection of scAAV9 vector on the day of birth.

COURTESY KEVIN D. FOUST, PH.D.

Using Autoantibody Data to Classify Myopathies Aids Therapy

BY SHARON WORCESTER

Identifying myositis-specific and myositis-associated antibodies is important for determining subclasses of idiopathic inflammatory myopathies so that appropriate and timely therapy can be initiated, judging from findings from a retrospective study of 169 patients.

Researchers examined the sera from 130 patients who had been initially classified as having primary myositis, and from another 39 patients who had been classified as having overlap myositis (systemic sclerosis [13], rheumatoid arthritis [12], systemic lupus erythematosus [5] and Sjögren’s syndrome [9]).

The initial classifications were made using original Bohan and Peter criteria, which are commonly used for classifying idiopathic inflammatory myopathy patients, but which don’t take into consideration the presence of myositis-specific and myositis-associated antibodies.

Reevaluation of these patients based on the presence of myositis-specific and -associated antibodies led to 11 (8.5%) of the patients in the primary myositis group being reclassified as having overlap myositis. That classification means that the patients also fulfilled revised American College of Rheumatology criteria for systemic lupus erythematosus, rheumatic arthritis, systemic sclerosis, or Sjögren’s syndrome, said Dr. Andrea Vánca of the University of Debrecen Medical and Health Science Center (Hungary) and colleagues.

In addition to determining the prevalence of various myositis-specific and myositis-associated antibodies, the investigators also identified the clinical characteristics, disease course, and response to therapy associated with the antibodies. Myositis-specific antibodies included anti-Jo-1, -PL-7, -PL-12, -Mi-2, and -SRP. Myositis-associated antibodies included anti-SS-A, -SS-B, -U1snRNP, -Pm/Scl,

and -Ku. The investigators characterized the patients into different clinicoserologic groups based on whether myositis-specific and myositis-associated antibodies were present, and further classified the patients as having polymyositis or dermatomyositis (Joint Bone Spine 2010 Feb. 24 [doi:10.1016/j.jbspin.2009.0.008]).

The researchers found that polymyositis was the most common myositis in overlap disease, occurring in 87% of patients in that group. Scleroderma was the most common overlapping disease, occurring in a third of patients in that group.

Antinuclear antibodies (ANA) were present in about 62% of overlap patients, compared with 25% of the primary myositis patients. ANA positivity was associated with an increased risk of associated connective tissue disease (odds ratio, 6.47), the investigators found.

Overall, nearly 40% of the myositis patients had autoantibodies, with anti-Jo-1 occurring most often and in similar fre-

quency in both primary and overlap patients (in 18% and 19%, respectively). The presence of anti-Jo-1 was predominantly associated with polymyositis (in 84% of patients), vs. dermatomyositis, they noted.

Improving the classification of myositis patients using information about myositis-specific and -associated antibodies is important. Clinicians have to consider a variety of these overlap syndromes when treating myositis because the initial treatment provides the best chance of effectively controlling the disease and preventing long-term organ damage.

For example, the researchers found that interstitial lung disease, fever, arthritis, and mechanic’s hand were all significantly positively associated with anti-Jo-1 autoantibody positivity in the patients in this study, and that anti-Jo-1 positivity was associated with a need for second-line treatment in primary myositis (OR, 1.95), but not in overlap disease (OR, 0.8). ■