

MRIs After Osteomyelitis Intervention Are Valuable

BY DIANA MAHONEY

Residual soft tissue and bone edema associated with diagnostic or surgical intervention for suspected osteomyelitis or septic arthritis does not diminish the value of subsequent magnetic resonance imaging in children with persistent signs of infection, a study has shown.

The issue under investigation was whether iatrogenic injury to soft tissue or marrow before an MRI study interferes with the clinician's ability to exclude infection or diagnose alternative causes for symptoms that remain despite a negative result after intervention.

Dr. J. Herman Kan of Vanderbilt Children's Hospital, Nashville, Tenn., and his colleagues conducted a retrospective case-control study using data from patients who underwent emergent contrast-enhanced MRI examinations that were performed for suspected osteomyelitis or septic arthritis at the hospital from March 2002 through September 2007.

Of the initial 136 MRI examinations, the analysis included only the 34 performed within 10 days after an initial diagnostic or surgical intervention, such as joint, marrow, or soft-tissue aspiration; arthrotomy; or incision and drainage of bone or soft tissue. The study control group consisted of 96 patients who underwent MRI for suspected osteomyelitis or septic arthritis during the same period but who did not have a prior intervention.

Pediatric radiologists with additional training in pediatric musculoskeletal radiology performed consensus reviews of the images to assess whether objective MRI criteria could still be applied to those patients who had undergone recent intervention. They also evaluat-

ed the presence or absence of specific MRI features of osteomyelitis that could neither be attributed to the recent intervention nor were suggestive of a noninfectious alternative diagnosis. Such features included intraosseous abscess, cortical breach, subperiosteal abscess, and soft-tissue or bone edema, the authors wrote.

The reviewing radiologists had knowledge of the location of the prior intervention and the final discharge diagnosis, they noted (*Am. J. Roentgenol.* 2008; 191:1595-600).

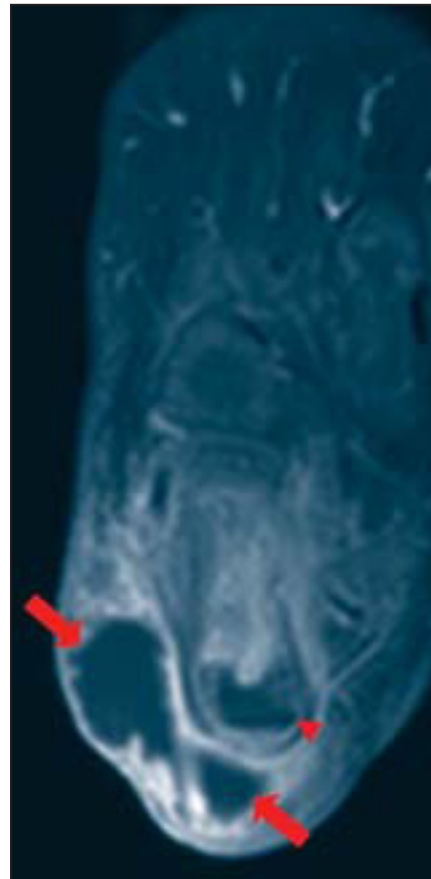In 10 of the 34 study group patients (29%), the MRI findings led to a need for additional intervention, which was similar to the control group, in which the MRI findings pointed to further intervention for 26 of the 96 control group patients (27%), Dr. Kan and his associates reported.

The groups did not differ significantly in the number of patients with a final diagnosis of osteomyelitis, osteomyelitis or septic arthritis, cellulitis or pyomyositis, and noninfectious conditions, they stated.

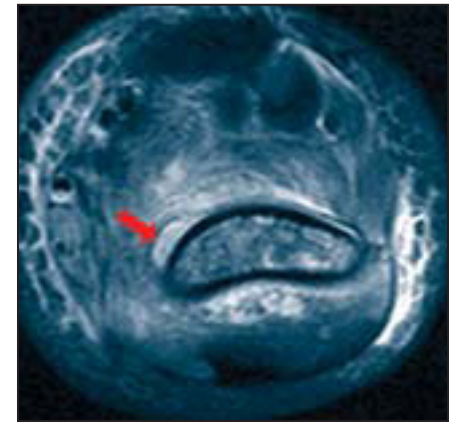
A total of nine patients in the study population had a final diagnosis of osteomyelitis, and "objective MRI criteria were present in all nine patients," the authors said, while none of the remaining 25 patients had characteristic imaging features of osteomyelitis.

Among the patients with an osteomyelitis diagnosis, "eight of nine had one or more imaging criteria of osteomyelitis, including intraosseous abscess, cortical breach, or subperiosteal abscess," Dr. Kan and his associates said.

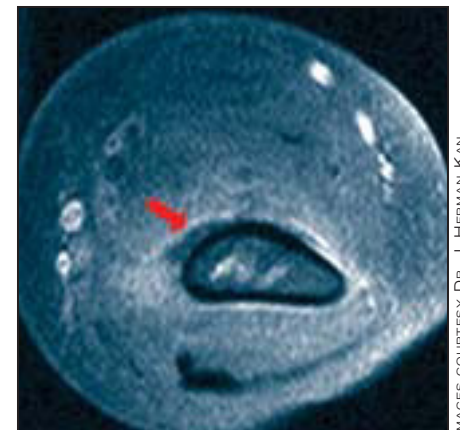The ninth subject was diagnosed with acetabular osteomyelitis based on evidence of marrow and soft-tissue edema



Right foot after administration of IV gadolinium shows large soft tissue abscess (arrows) and intraosseous calcaneal abscess (arrowhead).



T2-weighted distal humerus is shown with intramedullary abscess.



Corresponding T1-weighted image of humerus shows subperiosteal abscess.

IMAGES COURTESY DR. J. HERMAN KAN

in the obturator internus muscle, away from the intervention site.

The findings suggest that musculoskeletal MRI "plays an important role in the management of these patients because of its ability to evaluate underlying osteomyelitis despite recent intervention," according to the authors.

With correct clinical and surgical history, they wrote, "patterns of soft tissue and marrow edema can be explained."

Although intervention-related iatrogenic changes do not affect the diagnostic efficacy of MRI in children with suspected osteomyelitis or septic arthritis, "performing MRI before intervention adds efficacy to patient management, guides the surgical procedure, and prevents additional surgery in children with suspected pelvic or appendicular osteomyelitis or septic arthritis," Dr. Kan and his associates concluded. ■

Heliox and Epinephrine Boost Response in Bronchiolitis

BY MICHELE G. SULLIVAN

NASHVILLE, TENN. — Heliox may have a beneficial effect when used to deliver racemic epinephrine to young children with bronchiolitis, suggest the results of a randomized controlled trial.

Investigators found that children treated with epinephrine and heliox improved significantly more than those treated with epinephrine and oxygen, Dr. In Kim reported in a poster presented at the annual congress of the Society of Critical Care Medicine.

"The mixture of helium and oxygen delivers nebulization deeper and faster into the lungs and has been shown to ease the work of breathing in adults," Dr. Kim, a pediatric emergency physician at Kosair Children's Hospital in Louisville, Ky., said in an interview. "This would also be very important for these little ones, in whom more work of breathing can lead to fatigue and even respiratory failure."

The study involved 69 children aged 2-12 months, all of whom still had a Mod-

ified Wood's Clinical Asthma Score of at least 3 after an initial treatment of nebulized albuterol. The patients were randomized to nebulized racemic epinephrine delivered either by heliox (70% helium/30% oxygen) or 100% oxygen using a face mask. After the nebulization, all patients continued receiving their randomized treatment via a nasal cannula, which Dr. Kim said is more tolerable than a face mask for young children.

After 60 minutes of treatment, children whose bronchiolitis scores were 2 or higher received another dose of the nebulized racemic epinephrine, followed by continued inhalation via nasal cannula.

By 60 minutes, children receiving the drug via heliox had improved significantly more than those receiving the drug by oxygen. "The difference was significant early on and continued to grow," said Dr. Kim. By 240 minutes or at ED discharge, the mean change in the bronchiolitis score was 1.84 for the heliox group and 0.31 for the oxygen group—a highly statistically significant finding.

The findings almost exactly mirror those of a similar trial conducted in Spain in 2002. "We did not have a difference in length of stay, as the Spanish study did, but it also included sicker patients than ours. This supports the theory that the sicker the patient is, the greater the benefit of heliox," Dr. Kim said.

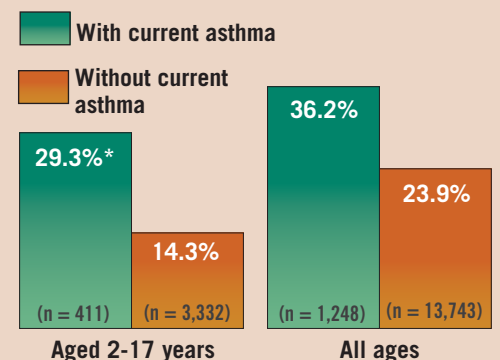
The Spanish study included 38 young children and infants aged 1-24 months who were admitted to the pediatric intensive care unit with respiratory syncytial virus bronchiolitis (*Pediatrics* 2002;109:68-73). Those randomized to nebulizer and inhalation therapy with heliox had a significantly larger mean decrease in bronchiolitis scores since the beginning of the study (4.2 points), than did children in the oxygen group (2.5 points). Pediatric intensive care unit length of stay was significantly

shorter in the heliox group than in the oxygen group (3.5 days vs. 5 days).

Dr. Kim did not disclose any financial conflicts. ■

DATA WATCH

Influenza Vaccination Utilization Is Higher for People With Asthma



*Statistically significant compared with children who do not currently have asthma.

Source: 2005-2006 data, Centers for Disease Control and Prevention

ELSEVIER GLOBAL MEDICAL NEWS