

# Hybrid Aortic Repair Is More Effective, Costlier

BY BRUCE JANCIN  
Denver Bureau

COLORADO SPRINGS — Combined aortic debranching and thoracoabdominal aortic endovascular repair is a less invasive alternative to open surgical repair of complex aortic aneurysms that provides better outcomes even in older, sicker patients.

That's the good news about the innovative hybrid procedure. The bad news is that the direct hospital costs are higher, and reimbursement is lower than for conventional open surgery. As a result, the hospital takes a 34% net loss on each patient who undergoes the hybrid procedure, Dr. Erin H. Murphy said at the annual meeting of the Western Surgical Association.

In contrast, open surgical repair provides the hospital with a net 6% profit, added Dr. Murphy of the University of Texas Southwestern Medical Center, Dallas.

Multiple small series, the largest involving 15-30 patients,

have demonstrated that the hybrid procedure entails attractively low rates of operative mortality, spinal cord ischemia, and perioperative morbidity. In contrast, open repair is associated with 10%-20% operative mortality rates, renal failure in 15%-30% of cases, pulmonary complications in 20%-40%, and spinal cord ischemia in up to 15%. However, there had been no prior hospital cost analyses.

To remedy this, Dr. Murphy reviewed the records of 27 Southwestern patients with aortic pathology involving branch vessels. Of those, 15 underwent hybrid repair because they were at high risk for open repair and had anatomy unsuited for endografting alone. The other 12 underwent conventional open repair. The two patient groups were similar in terms of location of aortic pathology.



**The hybrid procedure has low rates of operative mortality, spinal cord ischemia, and perioperative morbidity.**

DR. MURPHY

arch with branch vessel involvement. Aortic debranching and placement of an elephant graft are performed surgically through a sternotomy. Aneurysm exclusion is then completed by means of thoracoabdominal endovascular repair via peripheral access of instruments and devices. The endovascular completion spares high-risk patients a left lateral thoracotomy, aortic cross-clamping, and extensive exposure.

The patients who had hybrid repair averaged 73 years of age, versus 58 years for the open-repair group. Six patients in the hybrid-repair group were known to have significant coronary artery disease, as was one in the open-repair group. Nonetheless, the hybrid-repair group had significantly less intraoperative blood loss, fewer transfusions, lower rates of major in-hospital complications, fewer days on the mechanical ventilator, and less time in the ICU (see box).

Cost data supplied by the hospital finance department showed that the average total direct and indirect in-hospital cost of a hybrid repair was just under \$82,000, compared with \$76,000 for open repair. But reimbursement by both Medicare and private insurers was markedly less for hybrid repair, with a resultant negative 34% mean cost margin.

"The Gore TAG endoprostheses cost about \$10,000 apiece. If you put in one, you're kind of ahead of the game. With two you've got a small loss, and with three you're clearly at a negative. We're all hoping the cost of grafts will come down," Dr. Murphy continued.

Discussant Dr. Bruce L. Gewertz cited the hybrid procedure as yet another impressive example of the evolution of vascular surgery. ■

## Hybrid Aortic Repair Outcomes Superior to Open Surgery

	Hybrid repair (n = 15)	Open surgery (n = 12)
Patients with 1 or more major postop complications	47%	100%
Mortality	7%	17%
Renal failure	0%	42%
Pulmonary failure	20%	67%
Intraoperative blood loss	2.0 L	4.8 L
Time in ICU	5.5 days	14.0 days

Note: Based on in-hospital data.  
Source: Dr. Murphy

ELSEVIER GLOBAL MEDICAL NEWS

The hybrid repair was performed in a single session, although at some other centers it is done as a two-stage procedure. The procedure is used as an alternative to two-stage open surgery in patients with complex aneurysms of the proximal descending thoracic aorta and/or distal aortic

# Safety of Carotid Stenting Lags Behind Endarterectomy

BY MICHELE G. SULLIVAN  
Mid-Atlantic Bureau

Carotid artery stenting is associated with twice the incidence of postoperative stroke and in-hospital mortality seen with carotid endarterectomy, Dr. James T. McPhee and colleagues reported.

The disparity in outcomes is even greater among patients with symptomatic stenosis, who faced a fourfold increase in stroke and a sevenfold increase in mortality after stenting, compared with endarterectomy (*J. Vasc. Surg.* 2007;46:1112-8).

These conclusions suggest that carotid artery stenting is not ready for wide application, wrote Dr. McPhee of the University of Massachusetts, Worcester, and his coauthors. "Further randomized controlled studies with homogenous symptomatic and asymptomatic cohorts should be performed to determine what role carotid artery stenting will play in the treatment of patients with carotid stenosis."

The investigators drew their information from the Healthcare Cost and Utilization Project's 2003 and 2004 Nationwide Inpatient Sample database. During those two years, 259,000 carotid revascularization procedures were performed in the United States. Most (95%) were endarterectomy; the rest were stenting procedures. Almost all of the patients (92%) had asymptomatic stenoses. The patients' mean age was 71 years; however, the 8% of patients with symptomatic stenoses were significantly older (75 years).

The postoperative stroke rate for all pa-

tients was 1.8% after stenting and 0.9% after endarterectomy. A multivariate analysis identified stenting as an independent risk factor for both stroke (odds ratio 2.5) and in-hospital mortality (OR 2.4).

When the investigators examined symptomatic patients only, they found even more profound differences. Among these patients, the postoperative stroke rate after stenting was four times higher than it was after endarterectomy (4% vs. 1%). Symptomatic patients were seven times more likely to die in the hospital after stenting than after endarterectomy (7.5% vs. 1%).

The study adds to the already conflicted body of data on the safety of carotid artery stenting, Dr. McPhee and his coauthors wrote. While several independent studies have found an increased risk of stroke and death with carotid stenting, industry-sponsored registries have concluded that the technique is non-inferior to endarterectomy. "[These studies] have been criticized by others because of their methodology ... the power of the study, and the validity of a noninferiority study on nonrandomized data using a historical control for the surgical arm," the authors wrote.

The study provides a valuable insight into this confusing picture, said Dr. Wesley S. Moore, professor and chief emeritus of vascular surgery

at the University of California, Los Angeles. "This analysis represents actual, everyday practice data in contrast to very selective clinical trials and registries, most of which are industry sponsored, suffer from design flaws, and are open to criticism for lack of objectivity because the industrial sponsor has control of the data and is unlikely to publish unfavorable results," Dr. Moore said in an interview.

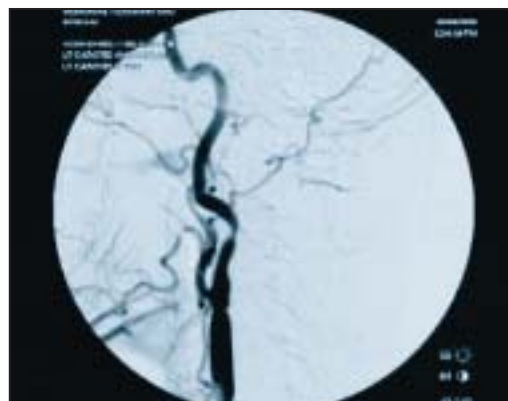Critics of the McPhee study may note that carotid stenting is an evolving technique, and that newer safety data will probably be better than those seen in 2003 and 2004, Dr. Moore said. "While this may be true, it is also important to point out that two prospective randomized controlled European studies—not industry supported—have reported similar results in favor of endarterectomy."

Indeed, he said, because carotid stenting is still a relatively new procedure, "It should

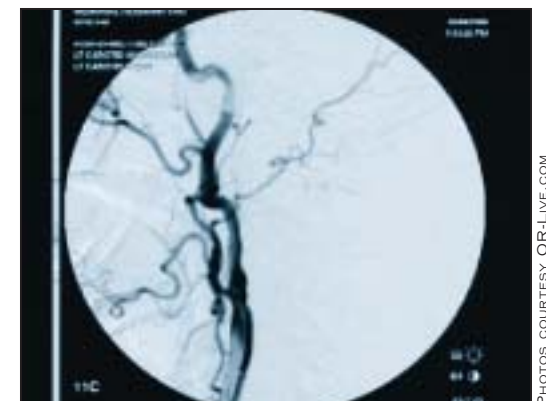
only be used in well-designed, objective clinical trials that will yield meaningful data, as opposed to so-called clinical registries, which only serve to skirt federal regulations and permit the unmonitored use of a yet-to-be proven procedure."

Finally, Dr. Moore said, data have yet to emerge regarding the comparative durability of the two techniques. "We currently have a large prospective randomized controlled study, supported by the National Institutes of Health [CREST or the Carotid Revascularization Endarterectomy vs. Stenting Trial], which is nearing completion of patient acquisition. Once that trial is complete, with 5-year follow-up, we should then have a final word as to the relative safety and benefit of the two procedures."

Dr. McPhee and his associates stated that they have no financial conflicts of interest. ■



Angiogram shows a narrowing of the internal carotid artery (near the center of the image).



A completion angiogram, taken after stenting, shows that the stenosis has been treated.

PHOTOS COURTESY OR-LIVE.COM