

# Joint Plan for Continence and Prolapse?

BY JANE SALODOF MACNEIL  
Southwest Bureau

SAN FRANCISCO — Risk-benefit ratios, the possibility of voiding dysfunction, the choice of prolapse procedure, and the woman's own priorities are among the factors that need to be considered when deciding whether to combine continence and prolapse procedures, Dr. Linda Brubaker said at a conference sponsored by the Society of Gynecologic Surgeons.

Dr. Brubaker was principal investigator in the Colpopexy and Urinary Reduction Efforts (CARE) trial. The results showed that combining the Burch colposuspension procedure with abdominal sacrocolpopexy significantly reduced the incidence of stress incontinence (*N. Engl. J. Med.* 2006;354:1557-66).

The trial randomized 157 women to both procedures and 165 to sacrocolpopexy alone. Three months after surgery, stress urinary incontinence was diagnosed in 44% of women who did not have the Burch procedure vs. 24% of women who did. Urge incontinence and serious adverse events were also reduced in the Burch group, but the difference did not reach statistical significance.

Dr. Brubaker, director of the division of female pelvic medicine and reconstructive

surgery at Loyola University Medical Center in Maywood, Ill., emphasized that the trial does not apply to all patients. It enrolled only women who were asymptomatic at baseline.

"If you don't put a Burch in, at least a third of your women are going to have stress incontinence, but people who leak are going to leak regardless of the Burch," commented Dr. Brubaker, professor of obstetrics and gynecology and of urogynecology and urology.

About 75% of all women with advanced prolapse have stress incontinence, you will learn if you carefully question, she said. The accuracy of diagnostic tests is limited, however, and she dismissed as largely ineffective most methods of predicting which patients will develop a problem after surgery.

Widely used terminology can be problematic as well, according to Dr. Brubaker. Patients can be said to have "potential stress incontinence" prior to surgery if they have no symptoms. Once they undergo urodynamic testing, however, either they have urodynamic stress incontinence or they do not. "The terms are

not used in the same way," she emphasized.

Another consideration is that the precise relationship between prolapse and symptoms is not clear, she said, warning that the chance of surgeon error increases with the extent of the prolapse. Overtreatment could lead to retention, she warned, and undertreatment could lead to incontinence.

**About 75% of all women with advanced prolapse have stress incontinence.**



DR. BRUBAKER

procedure in a frail, elderly patient scheduled for colpopexy. "It is better to err on the incontinence side. When both are present, undertreat the incontinence."

Dr. Brubaker recommended doing a continence assessment that includes a preoperative evaluation of urinary symptoms, sexual function, and constipation in all patients. The assessment should also entail a discussion of each person's goals and expectations going into surgery. Sometimes you have to make a trade-off with patients who have prolapse, she said, so understanding goals is important. ■

# Tampon Buttress Mimics Pessary in Active Women

Even very young women—and certainly many older women who lead physically active lives—may leak urine during vigorous exercise, but that does not mean they all need pessaries or surgery to get them on the court or the playing field, Dr. Michael Moen said at a meeting on women's health sponsored by OB.GYN. NEWS.

"For any woman who has stopped exercising due to leaking, the tampon trick is great," he said.

He instructs such women to use the largest tampon they can comfortably accommodate using lubrication to act as a buttress supporting the urethra, just as a pessary would.

The tampon trick should only be used during the period of time when a woman knows she will be engaged in doing vigorous activity.

"There's nothing wrong with using a tampon and wearing a pad and getting some biker shorts that have some support," he emphasized.

The point is to work with women until a way is found for them to engage in activities they enjoy, using whatever works for them, he said.

—Betsy Bates

# 3D MRI Can Show Urinary Tract in Unprecedented Detail

BY MITCHEL L. ZOLER  
Philadelphia Bureau

CHICAGO — Truly three-dimensional magnetic resonance imaging of the urinary tract was performed in pediatric patients using newly developed software and imaging protocols, Dr. Paul Kokorowski said at the annual clinical congress of the American College of Surgeons.

Because the 3D MRI information was collected as slabs of data (volume pixels, or voxels) rather than as slices, it contained unprecedented anatomical detail. The scan was complete in about 10 minutes, and the 3D image was available almost immediately, with no need for time-consuming postprocessing, Dr. Kokorowski said.

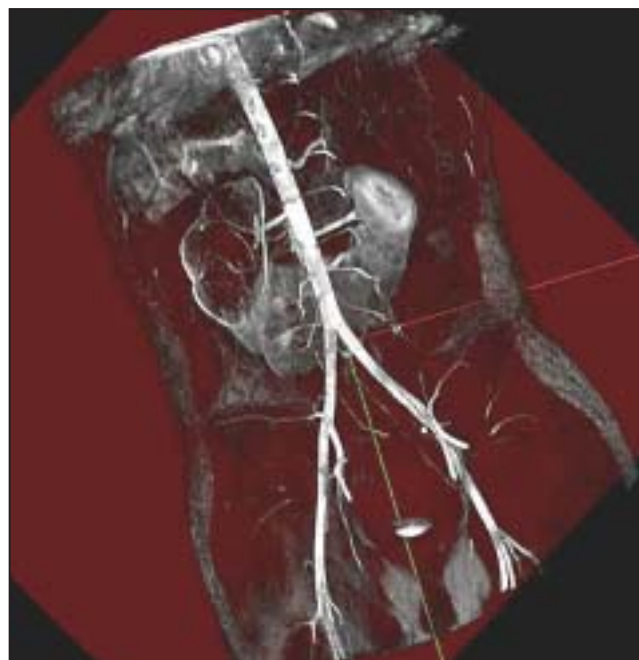
"The program takes the MR information that is acquired every day and packages it as you'd want to use it. You can look through the anatomy before doing surgery," said Dr. Kokorowski, a urologist at the University of Southern California and Childrens Hospital Los Angeles.

Dr. Kokorowski and his associates at Childrens Hospital worked with MRI experts to create the protocols for 3D MR urography.

At the meeting, they presented their results for six pediatric patients. The 3D images of the urinary tract aided the researchers' ability to evaluate and treat the children for various conditions, including ureterocele, an ectopic ureter, a duplex kidney, and a ureteropelvic junction obstruction.

The new protocols provided "a completely different way to look at patients preoperatively," said Dr. Roger E. De Filippo of Childrens Hospital, the senior urologist who collaborated on the project.

Dr. Anthony Atala, a meeting attendee who is a professor and chairman of urology at Wake Forest University in Winston-Salem, N.C., commented that "this truly represents a whole new area of imaging, because



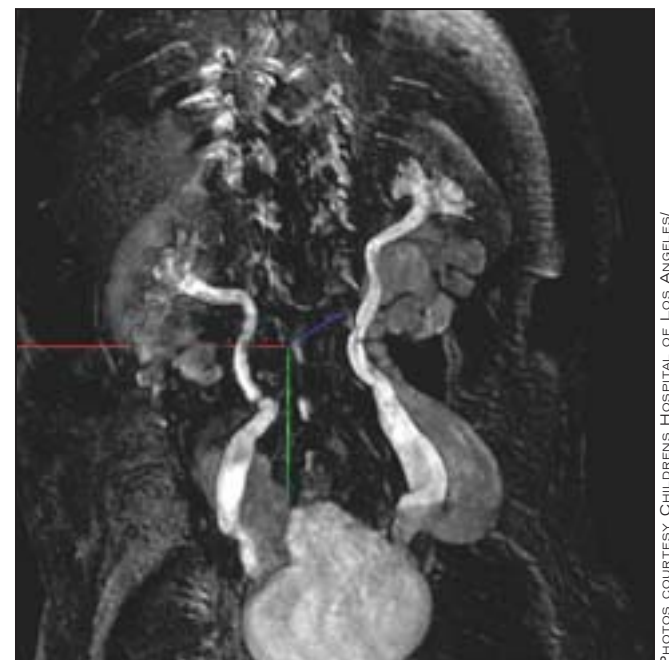
**A 3D magnetic resonance image shows a horseshoe kidney (red line) with the vasculature highlighted.**

you image volume instead of reprocessing sagittal data." Voxel MRI, known commercially as Volumap, was developed by Lee Schiel, president of Early Response Imaging in San Bernadino, Calif.

The method was introduced about 10 years ago in a project with the National Aeronautics and Space Administration to visualize structures that appeared to be bacteria on rocks collected on Mars.

In addition to developing urology protocols with the Childrens Hospital group, Mr. Schiel has worked with other clinical groups to develop ways to image the spine, the knee, and cardiac structures including heart valves.

The protocols developed so far are available commercially and can be used on any MRI scanner.



**Another 3D MRI shows bilateral duplicated kidneys (red, blue lines) and ureters down to the bladder (green line).**

Because data acquisition is faster than in conventional MRI, cutting imaging time down to about 10 minutes, the increased patient throughput allows the cost per scan to remain about what it has been, Mr. Schiel said.

3D MRI eliminates the many pages of conventional MR slice-images that a physician needs to sort through to assess three-dimensional anatomy in a patient, said Dr. Kokorowski.

The fast acquisition time eliminates motion artifacts and the need to sedate patients during scanning. It also allows imaging of dynamic processes, such as blood leaking through a faulty heart valve. Dr. Kokorowski is hopeful that the images will provide a new way to measure glomerular flow rate. ■