

# For Best Results, Consider Combining DMARDs

BY DIANA MAHONEY  
New England Bureau

Combination therapy with disease-modifying antirheumatic drugs in early rheumatoid arthritis is more effective than monotherapy in producing sustained remission, which in turn is associated with better radiographic outcomes, a Finnish study has found.

In a comparison of the rates of achieved and sustained remission and good treatment response among a cohort of early rheumatoid arthritis (RA) patients receiving either combination or single DMARD therapy, patients randomized to combination therapy were more than twice as likely to meet modified American College of Rheumatology (ACR) remission criteria at 2 years and were more than four times as likely to demonstrate sustained remission at each visit, compared with patients on monotherapy, reported Dr. Heidi Makinen of Jyväskylä Central Hospital (Finland) and colleagues in the Finnish RA Combination Therapy Trial (FIN-RACo).

The trial included 169 patients out of 195 included in the original FIN-RACo study for whom complete data were available. Patients were aged 18-65 years and had recent-onset RA, defined as less than 2 years' duration of active disease with 3 or more swollen joints and three of the following: erythrocyte sedimentation rate (ESR) of at least 28 mm/hr or C-reactive protein (CRP) greater than 19 mg/L; morning stiffness lasting a minimum of 29 minutes; more than 5 swollen joints; or more than 10 tender joints.

The 79 patients randomized to combi-

nation therapy initially received 500 mg of sulfasalazine twice daily, 7.5 mg methotrexate per week, 300 mg of hydroxychloroquine daily, and 5 mg of prednisolone daily. Dose adjustments were made for patients who did not achieve at least 50% improvement in two of the following three criteria: swollen joint count, tender joint count, and ESR or CRP, and drug replacements were made (auranofin for sulfasalazine or hydroxychloroquine, and azathioprine for methotrexate) if the original agents were discontinued for lack of efficacy or adverse events.

The 90 patients randomized to monotherapy initially received 2 g of sulfasalazine daily, which could be increased up to 3 g per day and, at the discretion of the treating rheumatologist, up to 10 mg of prednisolone daily. In the case of adverse events or lack of efficacy, sulfasalazine could be replaced with methotrexate or another single DMARD. Intra-articular glucocorticoid injections were allowed in all patients at the treating physicians' discretion.

Patient evaluations at baseline, 6, 12, and 24 months included assessments of tender joint count, swollen joint count, duration of morning stiffness, physician and patient overall assessment and pain on visual analog scales, physical function on patient self-report Health Assessment Questionnaire, ESR, and CRP. Radiographs of hands and feet were obtained at 6 and 24 months and were scored by radiologists blinded to the treatments according to the Larsen method.

Remission was defined based on modified ACR criteria, including no joint swelling or soft tissue swelling of tendon sheaths, no joint tenderness or pain on mo-

tion, normal ESR, and morning stiffness lasting no longer than 15 minutes. Remission based on Disease Activity Score 28 (DAS28) was defined as a DAS28 score of less than 2.6. Sustained remission was defined as the presence of remission at 6, 12, and 24 months. Good treatment response was defined according to the European League Against Rheumatism (EULAR) treatment response criteria as a DAS28 score less than 3.2 and a decreased DAS28 score of more than 1.2 from baseline.

Of the full study population, 62% were female, 70% were rheumatoid-factor positive, and 48% had evidence of erosions on baseline hand and/or foot radiographs.

Based on the modified ACR criteria, 20 of the combination-therapy patients and 11 of the single-therapy patients were in remission at 6 months. At 12 months, 13 of the combination patients and 3 of the single-therapy patients were still in remission, and at 24 months, 11 of the combination patients and 3 of the single-therapy patients remained in remission. The odds ratio for sustained remission in the combination versus single-therapy group, adjusted for baseline DAS28 values, was 4.61, the authors reported (*J. Rheumatol.* 2007;34:1-6).

With respect to the duration of DAS28 remission, 52 of the combination patients were in DAS28 remission at 6 months, and 45 and 40 were still in DAS28 remission at 12 and 24 months, respectively. In the single-therapy group, 33 patients were in DAS28 remission at 6 months, and 21 and 14 remained in DAS28 remission at months 12 and 24, respectively. As such, the odds ratio for sustained DAS28 remission in the combination-therapy group,

compared with the single-therapy group was 5.58, the authors wrote.

Treatment responses were good based on the EULAR criteria in 59 of the combination patients and 47 of the single-therapy patients at 6 months. Approximately 67% of the combination patients and 27% of the single-therapy patients demonstrated sustained good responses at 24 months, they stated.

A review of the association between radiographic progression and the sustained remission and good treatment response showed markedly less deterioration in Larson score among patients in sustained remission, compared with those who achieved remission at the 6-month visit but did not sustain it, according to the investigators. Because sustained remissions were more common in the combination-therapy patients, it follows that such treatment would be associated with better radiographic outcomes, they said.

While the study was limited by its assessment of remission only at the 6-, 12-, and 24-month time points—leaving open the possibility that patients in remission at those time points could have experienced active disease flares between visits—previous studies have shown that such flares are often linked to discontinuation of therapy while in remission. “In our study, combination therapy was continued successfully for 2 years, and half the patients remained in sustained DAS28 remission,” the authors wrote.

The findings of this study suggest that sustained remission, rather than remission, should be the goal of DMARD therapy, the authors concluded. ■

## IMAGE OF THE MONTH

The patient's twin brother and one sister had been diagnosed with rheumatoid arthritis (RA). On the basis of these findings and the physical evaluation, the primary care physician had diagnosed the man with RA and initiated treatment with nonsteroidal anti-inflammatory agents and prednisone. However, the symptoms did not lessen with treatment.

Physical examination demonstrated dorsal soft-tissue thickening of the bilateral index- and long-finger proximal interphalangeal (PIP) joints, said Dr. Graciela S. Alarcón, the Jane Knight Lowe Chair of Medicine in Rheumatology, in the division of clinical immunology and rheumatology at the University of Alabama, Birmingham. In addition, the patient had severe flexion contractures in the palmar fascia

or flexor tendons of both hands—a finding consistent with Dupuytren's contractures. This would explain the man's inability to extend his fingers. Another test for rheumatoid factor was negative and his erythrocyte sedimentation rate was 19 mm/hr.

The presumptive diagnosis included Dupuytren's contracture, a benign, slowly progressive fibroproliferative disease of the palmar fascia that has no clear etiology or pathogenesis, and knuckle

pads. The term “knuckle pad” is most often used to describe benign cutaneous lesions of the extensor surfaces of the fingers. However, the lesions most commonly affect the PIP joints rather than the entire extensor surface. These discrete round skin nodules are usually soft and free moving.

Many physicians are unfamiliar with this diagnostic condition; ultrasound examination confirmed the absence of synovitis and the presence of periarticular soft-tissue fullness in this case and several others reported by Dr. Alarcón and her colleagues (*Skeletal Radiol.* 2006;35:823-7). This may be important to reassure patients and physicians that they are not dealing with RA.

Knuckle pads are commonly associated with palmar and plantar fibromatosis, occurring in up to 20% of patients with Dupuytren's contracture. Less well-defined or softer knuckle pads may be confused with more common causes of soft-tissue swelling, such as inflammatory arthritis. The presence of knuckle pads may lessen the accuracy of the physical exam when assessing the presence of underlying synovitis.

The radiograph shows periarticular soft-tissue fullness, which can sometimes be seen in RA, leaving the diagnosis unclear, said Dr. Robert Lopez, a radiologist at the University of Alabama, Birmingham, who specializes in musculoskeletal imaging.

Ultrasound is demonstrably better than standard clinical joint assessment for synovitis and is more sensitive

than radiography in identifying erosive disease in inflammatory arthritis. Another advantage of ultrasound is that it allows physicians to quickly see in the office what the likely causes are, said Dr. Lopez.

In their small series of patients, Dr. Alarcón and Dr. Lopez noted a difference in the sonographic appearance of knuckle pads in patients with and without Dupuytren's in a small series. These two patients showed diffuse areas of lower echo signal and skin thickening overlying the dorsum of the

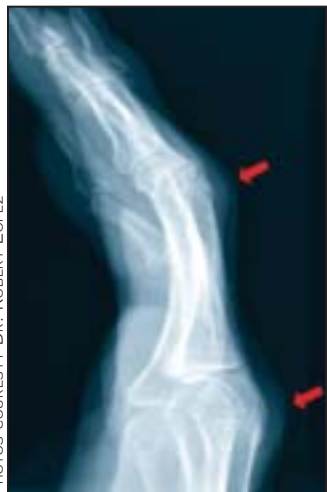affected PIP joints with a linear hypoechoic band paralleling the epidermis layer. Focal subcutaneous areas of lower echo signal are more suggestive of rheumatoid nodules and neurofibromas.

No sonographic evidence of synovitis was identified in this patient, but there were clear subcutaneous areas of lower echo signal. With arthritis, the joint capsule would appear distended and the cortical surface would be irregular, while the soft tissue would appear normal.

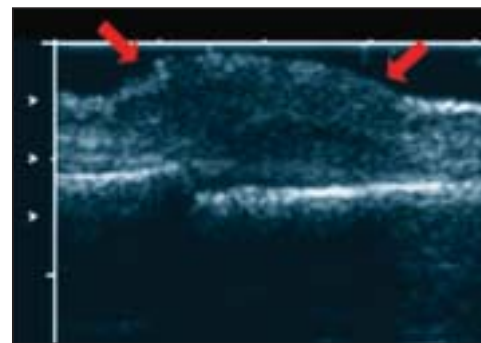
This image shows that “the joint is fine. This person does not have an inflammatory arthritis. What he has is this condition that infiltrates the skin,” said Dr. Lopez.

The patient was reassured that he did not have rheumatoid arthritis, to his relief. He was advised to continue using anti-inflammatories on an as-needed basis but was strongly encouraged not to take them routinely. He was not referred for surgery, because the pads were not causing significant functional impairment and if removed, they are likely to return.

—Kerri Wachter



Periarticular soft-tissue fullness is visible on x-ray.



Longitudinal ultrasound of the fourth PIP shows diffuse areas of low echo signal.