

# Grading Dysplastic Nevi: Easy as Present or Not

BY DOUG BRUNK  
San Diego Bureau

SAN DIEGO — There's no need to grade the level of architectural disorder when assessing dysplastic nevi. Just acknowledge if it's present or not.

"It doesn't matter how much architectural disorder is there; it only matters that it's present or absent," Dr. Terry L. Barrett said at an update on melanoma sponsored by the Scripps Clinic. "It's like being pregnant. Every single person in the world can be divided into one of two categories: You're either pregnant or you're not."

His minimal criterion for defining the presence of architectural disorder in a lesion is a well-defined junctional nevus with nests at the base of the rete and lentiginous proliferation. Concentric eosinophilic fibroplasia and lamellar fibroplasia are commonly seen.

In addition to architectural disorder, dysplastic nevi may or may not have cytologic atypia, which may include large nuclei with variation of nuclear size; irregular nuclear membrane; variably staining chromatin; large eosinophilic nucleoli; and fine dusty melanin pigment in cytoplasm.

Some experts recommend that cytologic atypia be graded as mild, moderate, or severe, but Dr. Barrett does not use the term moderate. "If there's none there's none, but if there's some cytologic atypia it's either mild or severe," said Dr. Barrett of the departments of pathology and dermatology at the University of Texas, Dallas.

He favors a modified version of Dr. Arthur R. Rhodes' atypia grading system (Mod. Pathol. 1989;2:306-19). Cytologic atypia is considered mild if the size of the nucleus of the melanocyte is 1.5-2 times the size of the nucleus of the keratinocyte and if nucleoli are not present; if they are present, there should be no more than one per cell, he explained.

"I can tell that in 2 microseconds," Dr. Barrett said. "It's very easy."

Cytologic atypia is severe if there are multiple nucleoli per cell, or if the nucleus is more than two times the size of the basal keratinocyte nucleus, or if there is chromatin clumping or nuclear membrane notching.

"I can tell that very quickly," said Dr. Barrett, who also directs an outpatient pathology group in Dallas.

"More importantly, it's reproducible. I'll grant you that it's arbitrary. But the important thing is, no matter which one of the dermatopathologists who works with me signs this case out, it's going to be the same. For the dermatologist who gets the report, it's always going to be the same. If they ask me to review the case later because they want to know what I think, it's going to be the same because it's easy to do and it's reproducible."

Common acquired nevi begin to appear in childhood and increase in number from approximately 6 months of age until the third decade. At that point, they begin to decline in number. "They usually stabilize at 3-5 mm and rarely develop in patients over age 40," said Dr. Barrett, who had no relevant conflicts of interest to disclose.

In contrast, dysplastic nevi begin to appear near puberty and continue to develop throughout adulthood. "If you do serial photography of these lesions, they will increase and decrease in atypicality," he said. "They are usually greater than 5 mm."

Dysplastic nevi were originally classified as familial dysplastic nevi syndrome and sporadic nevus syndrome. Current concepts include the familial atypical mole/melanoma syndrome, which came out of the 1992 National Institutes of Health consensus statement on the diagnosis and treatment of early melanoma, and the abnormal mole phenotype. The latter definition was developed by researchers who proposed a spectrum approach that considers both the number and atypicality of nevi (West. J. Med. 1994;160:343-50). Melanoma risk increases along this continuum.

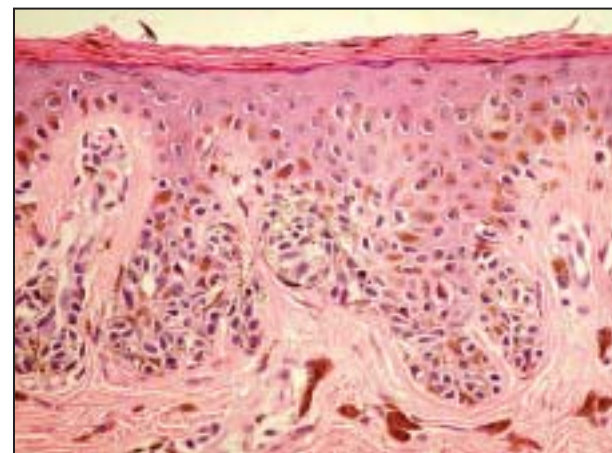
Initially, that theory "went nowhere because people didn't believe that you could have large numbers of common acquired nevi and no dysplastic nevi, and you [would nevertheless be] at increased risk for melanoma. But we now know that is absolutely true, and a number of studies have shown that patients who have large numbers of common acquired nevi have an increased risk of developing melanoma," Dr. Barrett said.

Melanoma risk also appears to increase in the presence of dysplastic nevi. A significant factor is the presence or absence of family history of either condition.

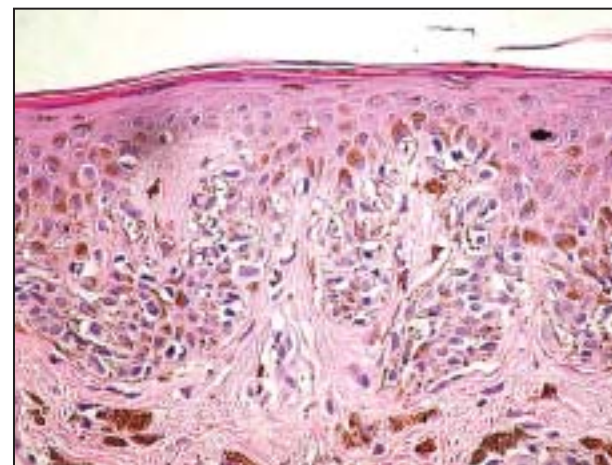
Intermittent sun exposure correlates with the risk of developing malignant melanoma and with the risk of developing multiple nevi. "Whether melanoma arises from nevi or not is unclear, but it appears that the stimulus for formation of both is the same," he said.

The risk of melanoma in a patient who has "one dysplastic nevus and nothing else" is the about the same as someone who has red or blond hair. "Not everybody with red or blond hair is going to get melanoma, but they are at an increased risk," he said.

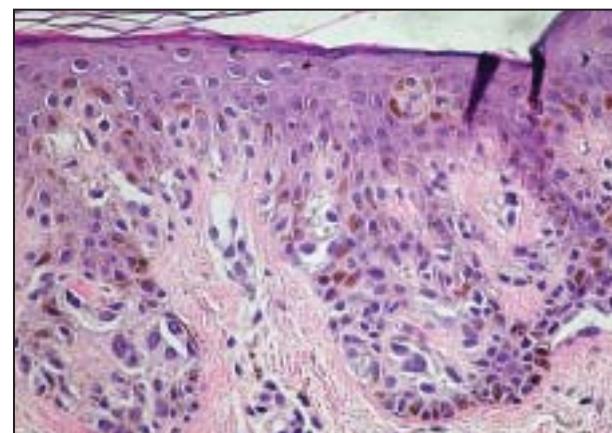
Dr. Barrett likened dysplastic lesions to amoebae. These lesions "go through quiescent phases and they go through active phases," he said. "If we do serial photographs, we can document this change. If the lesion is quiescent and you biopsy it, you see no atypia because there is minimal cellular activity. If you biopsy it in an active phase, it's going to have some degree of atypia. That doesn't mean that atypia equates with dysplasia or premalignancy. That's what I think is happening." ■



No cytologic atypia can be seen in this slide from a patient with dysplastic nevi, per Dr. Terry L. Barrett.



The atypia seen above is considered mild according to Dr. Barrett's modified dysplastic nevi grading system.



This patient has severe cytologic atypia. Dr. Barrett avoids the term moderate when assessing atypia.

PHOTOS COURTESY DR. TERRY L. BARRETT

## Topical 5% Imiquimod Effectively Treats Bowen's Disease

BY SHARON WORCESTER  
Southeast Bureau

ORLANDO — Topical 5% imiquimod is an effective treatment for squamous cell carcinoma in situ and should be considered as an option for this disease, Dr. Theodore Rosen reported at the annual meeting of the Florida Society of Dermatologic Surgeons.

Imiquimod (Aldara) is approved for the treatment of superficial basal cell carcinomas, and although it has been used for Bowen's disease, data are lacking on its efficacy for this use, said Dr. Rosen, who is professor of dermatology at Baylor College of Medicine in Houston.

A review of 49 of his patients with Bowen's disease who were compliant with their treatment showed that nearly 90% had a complete response at an average follow-up of 2 years. About one-third of the cleared cases were verified on biopsy.

Importantly, five patients who were believed to be compliant had no response whatsoever. This supports the premise that about 1% of the population will fail to respond to imiquimod, Dr. Rosen noted.

An alternative approach to treatment should be used in such patients, he said.

In general, though, the response rate with imiquimod is

reasonable. Findings from the three best studies of this treatment suggest that the overall response rate is about 85%, which is enough to warrant its consideration by physicians, Dr. Rosen said.

In his study, patients ranged in age from 48 to 85 years, and 96% were male.

The lesion was located on the extremities in 30% of patients, on the face in 25%, on the trunk or neck in 18%, on the genitalia in 11%, on the scalp in 9%, on the ears in 5%, and on the lips in 2%, he reported.

Lesions on the genitalia had a significantly greater risk of progressing to invasive disease (10%

vs. 3% for other areas), yet all of the genital lesions in this study cleared with imiquimod treatment, he noted (Dermatol. Surg. 2007;33:427-31).

Patients were treated daily for 6-16 weeks (every other day for patients with genital lesions) until the target area was heavily crusted and eroded.

"I tend to push it a little bit," Dr. Rosen said of the therapy, adding that it is important to monitor patients.

There have been a few case reports of Bowen's disease ostensibly being cleared with imiquimod, only to have a subsequent invasive lesion develop, he noted. ■

Patients who undergo treatment with imiquimod for Bowen's disease are at high risk and "shouldn't be out of your grasp," Dr. Rosen said.

Although some cases of invasive squamous cell carcinoma have been treated with imiquimod and the overall treatment success rate appears to be about 70%, it is not his treatment of choice for invasive disease, as it is for Bowen's disease, he said.

Dr. Rosen disclosed that he has served on the speakers bureau for Graceway Pharmaceuticals, the maker of Aldara, and has received honoraria from the company. ■