

MASTER CLASS

Revisiting Symptomatic Rectocele Repair



BY CHARLES E. MILLER, M.D.

Concerns have been raised about the use of mesh and subsequent erosion in rectocele repair via posterior colporrhaphy, although many still advocate the use of mesh. Furthermore, it has been noted in several studies that vaginal surgery augmented by mesh did not result in significantly less recurrent prolapse than traditional colporrhaphy. Given this issue, it is pertinent to revisit posterior colporrhaphy and perineorrhaphy for rectocele repair without mesh augmentation.

Approximately 200,000 women undergo surgery for

pelvic prolapse each year in the United States. According to the Department of Health and Human Services' Administration on Aging, three-quarters of women with prolapse have a rectocele. It has now been nearly a century since approaches to the posterior compartment to treat symptomatic rectoceles were first described. Through much of this time period, posterior colporrhaphy and perineorrhaphy have proven to be the gold standard. By plicating the posterior vaginal muscularis or medial aspect of the levator ani muscles in the midline, and when prudent performing a perineorrhaphy, cure rates of 76%-96% have been noted.

In this Master Class in Gynecologic Surgery, I have asked Dr. Dee E. Fenner, Harold A. Furlong Professor of Women's Health and director of gynecology at the University of Michigan, Ann Arbor, to discuss the tech-

nique of posterior colporrhaphy and perineorrhaphy. Dr. Fenner's current research includes mechanisms of vaginal wall support failure; she is a nationally known expert in urogynecology and travels throughout the country as an invited lecturer. It is an honor to have Dr. Fenner's recommendations on this very pertinent topic. ■

DR. MILLER is clinical associate professor at the University of Chicago and the University of Illinois at Chicago, immediate past president of the AAGL (www.aagl.org), and vice president of the International Society for Gynecologic Endoscopy. He is a reproductive endocrinologist in private practice in Schaumburg, Ill., and Naperville, Ill.; the director of minimally invasive gynecologic surgery at Lutheran General Hospital in Park Ridge, Ill.; and the medical editor of this column.

Managing Posterior Vaginal Wall Prolapse

Patients with pelvic organ prolapse present with a variety of symptoms and anatomical findings. In the case of posterior vaginal wall prolapse, one must first determine what part of the patient's support mechanism has failed. It is important to decide in the clinical examination whether her prolapse is related to a loss of apical support, a weakness in the distal vaginal wall, a separation or weakness in the perineal body, or some combination of these support failures.

Like anterior wall prolapse, loss of apical support can lead to prolapse of the upper and mid vagina. Elevating the top of the vagina with a ring forceps or Kelly clamp to a more physiologically normal position in the office or operating room can determine the role of apical failure in the posterior wall prolapse. Once that determination is made, the surgeon then can decide on the type of repair the patient requires.

Occasionally, if the clinical examination does not match the patient's symptoms, radiologic studies such as a defecography can help identify the support defects.

If the prolapse stems predominantly from a loss of apical support, treatment can be addressed through one of several procedures, from a sacral colpopexy to a uterosacral suspension or a sacrospinous vaginal vault suspension. If the prolapse involves a more traditional type of rectocele, where there is loss of support in the distal vaginal wall, one must decide what type of repair—site specific or standard posterior colporrhaphy—will result in the best anatomic and functional outcomes.

Finally, weakness in the perineal body or perineocele is determined by palpating the thickness and integrity of the perineal body on rectal exam.

Equally important to the anatomic considerations and prior to any surgery, the patient's symptoms as well as her current and future sexual function

should be addressed. Women with posterior compartment prolapse frequently have symptoms related to bowel dysfunction, including straining, incomplete bowel emptying, painful bowel movements, and fecal incontinence. The extent or severity of symptoms is not necessarily related to the severity of prolapse, and frequently her bowel function is most dependent on upper GI function and the type and frequency of her stool.

Studies have generally shown that most bowel symptoms—particularly straining and incomplete emptying—are resolved or improved with posterior wall repair. In some cases, surgical treatment may not necessarily correct bowel dysfunction, and occasionally it may contribute to bowel dysfunction.

Before surgical therapy, it is critical to understand which symptoms are bothering the patient, if they are related to the physical findings, and if surgical correction of the anatomy will improve her symptoms. Each patient should be appropriately counseled about the possible impact of prolapse surgery on both bowel and sexual function. Depending on the aggressiveness of the repair, approximately 15% of patients may experience some discomfort with intercourse after a colpoperineorrhaphy. Not plicating the levators can decrease but not totally alleviate this risk (*Obstet. Gynecol.* 2004;104:1403-21).

Traditional Repair Yields Best Outcomes

The approach to rectocele repair has evolved over the years, but the literature still suggests that a more traditional type of repair, with side-to-side plication and the use of delayed absorbable suture yields the best results with the least morbidity.

This surgical technique generally involves a two-layer repair, with minimal trimming of some of the vaginal wall and closure of the vaginal mucosa with an in-

terrupted or running polyglactin suture.

Authors of a 2007 Cochrane Review of the Surgical Management of Pelvic Organ Prolapse in Women reported that for posterior vaginal wall prolapse, the vaginal approach was associated with a lower rate of recurrent rectocele and/or enterocele compared with the transanal approach (relative risk 0.24), a type of rectocele repair performed commonly performed by colorectal surgeons. However, data on the effect of surgery on bowel symptoms and the use of polyglactin mesh inlay or porcine small intestine graft inlay on the risk of recurrent rectocele were insufficient for meta-analysis. There also were no randomized trials using permanent mesh for rectocele repairs, either as an inlay or as a "suspension kit" (*Cochrane Database Syst. Rev.* 2007;3:CD004014).

In one well-conducted, randomized controlled study, the traditional posterior colporrhaphy was found to have a lower failure rate compared with the site-specific repair alone, or a site-specific repair with the addition of a porcine small intestine submucosa graft for rectoceles. Symptomatically, if the anatomical repair was successful, there were no significant differences between the posterior colporrhaphy, site-specific repair, or site-specific repair augmented with porcine small intestine submucosa in terms of perioperative and postoperative morbidity, functional outcomes, quality of life, and bowel and sexual function (*Am. J. Obstet. Gynecol.* 2006;195:1762-71).

Currently there is little evidence to support the use of absorbable or permanent mesh in the posterior wall. Case series of mesh inlays or mesh kits without native tissue controls are still needed to determine the risks and benefits of these procedures. The caution is to not consider the posterior vaginal wall as a mirror image of the anterior vaginal wall. While one type of graft may improve the surgical cure for cystoceles, it may not add any benefit for rectocele repairs.

Additionally, stiffness in the posterior vaginal wall can lead to dyspareunia and

defecation disorders, primarily fecal urgency and fecal incontinence. If the rectum is not expandable because the posterior vaginal wall is stiff and nonpliable, the patient feels a constant urge to defecate, and if she has poor anal sphincter function, a noncompliant rectal reservoir can lead to fecal or flatal loss.

In my practice, when a patient complains of splinting or incomplete evacuation, I suspect a distal rectocele and a deficient perineal body. Perineal body defects are often found in patients who have an enlarged vaginal introitus or a history of straining or prior episiotomy, for instance, and addressing these defects is a key part of posterior wall repair that is too often neglected.

When a perineorrhaphy is performed, the bulbocavernosus muscles must be identified and plicated in the midline with care so as not to narrow the introitus so significantly that coital activity would be impaired. Caudad to the bulbocavernosus muscles, mobilization of the lateral tissues will enable plication of the medial portions of the puboperineus muscles. This compensatory repair will help bulk and strengthen the perineal body.

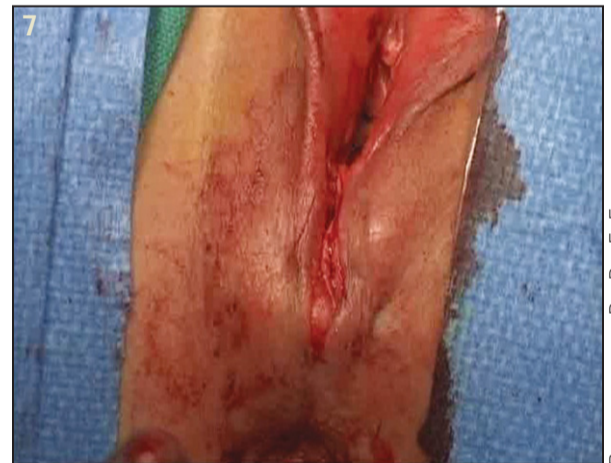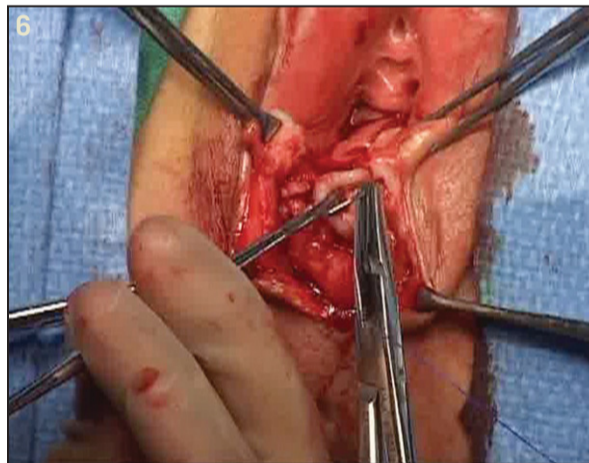
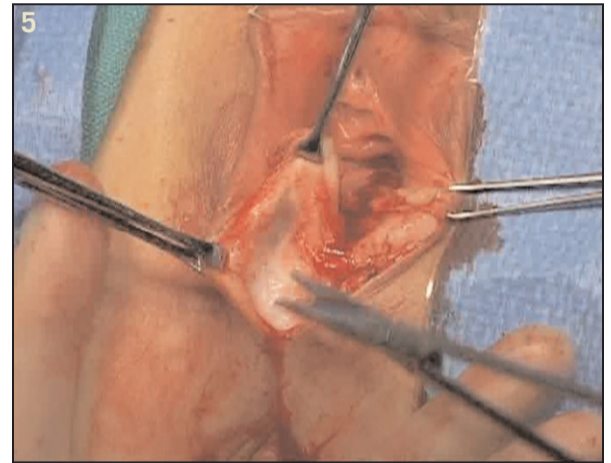
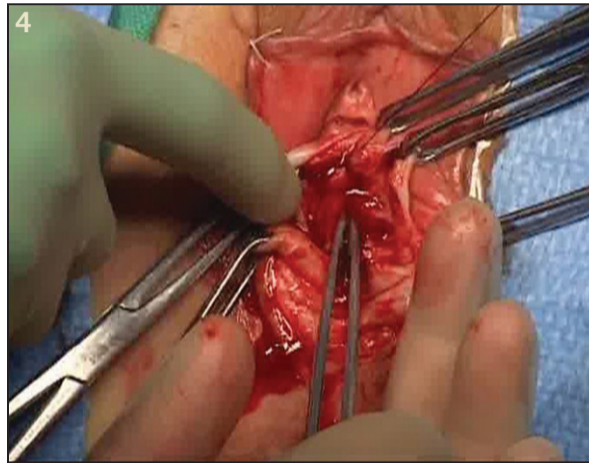
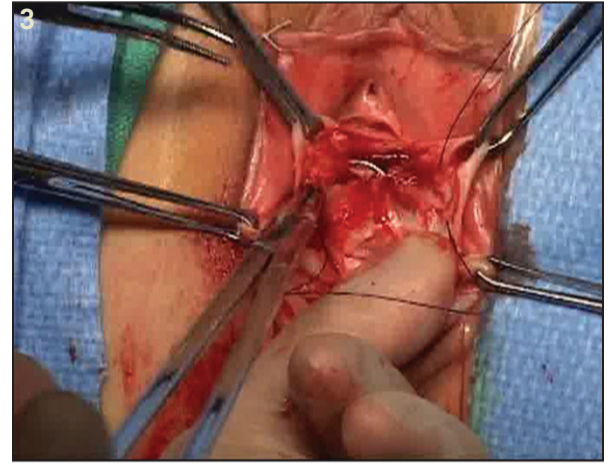
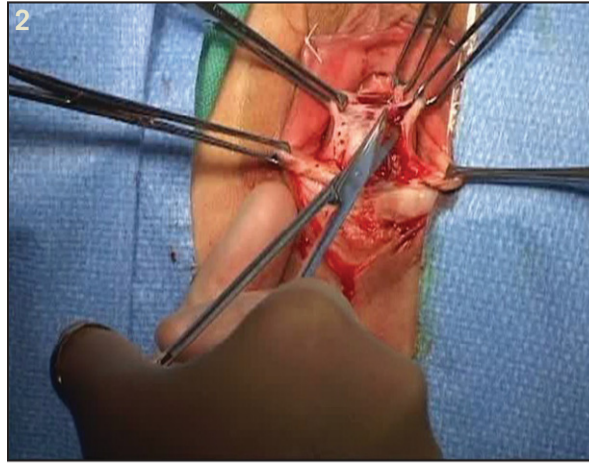
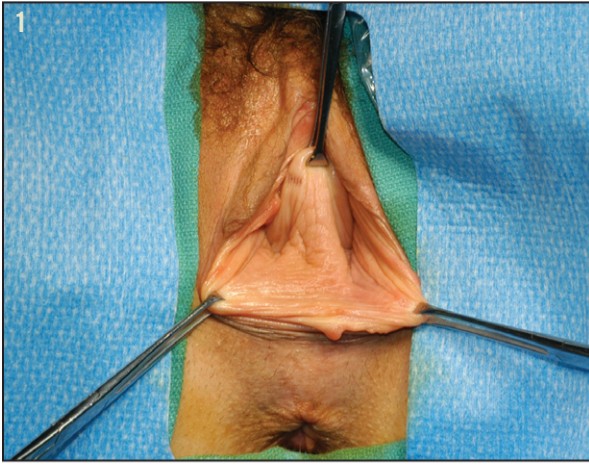
I use 3-0 prolonged, delayed, absorbable sutures, in one or two layers. This step increases the length and thickness of the perineal body and can also increase the functional length of the posterior vaginal wall.

Technique for Traditional Colporrhaphy

As described by Dr. B.H. Goff and later Dr. David Nichols, the traditional posterior colporrhaphy involves opening the posterior vaginal wall epithelium in the midline and dissecting laterally and superiorly, then plicating the posterior vaginal wall muscularis—or rectovaginal septum, as the endopelvic fascia is termed—in the midline. The excess of the epithelium is then trimmed and brought back together in the midline.

With the Goff method, the rectovaginal septum is not dissected "off" the posterior vaginal wall. In contrast, with

Continued on following page



Continued from previous page

the Bullard modification, the rectovaginal septum is dissected off the posterior vaginal wall. This mobilizes the connective tissue layer to the lateral sidewalls and allows a separate layer to be plicated between the vagina and rectum.

I prefer this technique for two reasons. First, it allows one to decrease the size of a dilated rectal ampulla by inverting the dilated rectal wall into the rectal lumen similar to a transrectal rectocele repair. Also with this method, any "ridge" created is directed posterior for less dyspareunia. The levator muscles should never be plicated, unless an obliterative procedure is being performed, because of the impact on sexual function.

To begin, two Allis clamps are placed on the hymen at approximately the 5 o'clock and 7 o'clock positions. The position of these clamps should be modified, however, depending on the size of the genital hiatus, so that three finger breaths can be easily admitted to ensure enough room for sexual intercourse. As patients age, this becomes increasingly important as the incidence of erectile dysfunction in male partners precludes penetration in a very narrow genital hiatus.

Since rectocele repair is usually done after other apical or anterior wall compartment defects are corrected (rectoceles are rarely isolated problems, and high rectoceles are usually associated with apical defects or enteroceles), it is important to appreciate that the introitus may tighten during the healing process.

Once the Allis clamps are placed on the hymenal ring, with a finger placed in the rectum, the surgeon must identify the extent of the weakness in the vaginal wall. This is accomplished by a thorough examination of the vagina with palpation between the finger and thumb. For example, with a finger in the rectum, palpate transrectally the thickness of the perineal body. This will enable you to determine if the bulbocavernosus muscles are separated or retracted, generally from childbirth or chronic straining or constipation, and will give you an assessment of the perineal body integrity.

Further, by elevating the vaginal wall rectally, the point of weakness and placement of the apical limit of the repair can be determined. At that point, another Allis clamp is then placed accordingly in the vagina to mark the top of the repair.

Once you have determined the size of your dissection, use a dilute vasopressin solution to infiltrate underneath the posterior vaginal wall along the dissection margins (we use vasopressin 20 U in 50 cc of normal saline). An incision along those margins is made with a knife through the mucosa. Metzenbaum scissors or a knife can then be used to excise the vaginal mucosa.

I prefer to keep a finger in the rectum at all times. This helps prevent inadvertent placement of a stitch in the rectum. I generally grasp the edges of the incision with Allis clamps and mobilize the "rectovaginal septum" off the posterior vaginal wall.

Prolonged delayed absorbable sutures are used to plicate the fibromuscularis tissue in the midline in a side-to-side fashion. I generally use a 2-0 polydioxanone (PDS) absorbable suture on a CT-2 needle, placed in

Figure 1: Allis clamps are placed on the hymen at approximately the 5 o'clock and 7 o'clock positions. Clamps are adjusted to desired introital size. Figure 2: Mobilize the "rectovaginal septum" off the posterior vaginal wall. Figure 3: Plicate the fibromuscularis tissue in the midline in a side-to-side fashion. Figure 4: A tonsil clamp is used to invert the enlarged rectal ampulla as the dense connective tissue is plicated. Figure 5: Mobilize and dissect the mucosa of the perineal body to identify or at least attempt to palpate the ends of the retracted bulbocavernosus muscles. Figure 6: Grasp the retracted bulbocavernosus muscles, and place a horizontal mattress stitch. Figure 7: Close the repair with Vicryl suture that was placed above and held, with a deep layer down and a subcuticular layer back up, with the knot just inside of the hymenal ring.

interrupted horizontal mattress stitches to the level of the hymen. I try to create a ridge of tissue that is directed posterior toward the rectum.

If the rectal ampulla is enlarged, it will often invert as the dense connective tissue is plicated, thus reducing the size of the rectum. Depending on the size of the rectocele and how high I have gone with the rectocele repair, I place two to eight stitches.

Generally, before placing those sutures, I will place a stitch using a 3-0 Vicryl suture at the apex of the incision so that once I finish the deep layer I can easily run a 3-0 Vicryl suture interlocking with about every third stitch to the level of the hymen. I have found interlocking every few stitches prevents shortening of the wall.

When applicable, the perineal body must be addressed next. With the extent of the deficiency taken into account, I mobilize and dissect the mucosa with Metzenbaum scissors so that I can identify or at least attempt to palpate the ends of the retracted bulbocavernosus muscles.

I will grasp these muscles with an Allis clamp and place a horizontal mattress of stitch using a 2-0 PDS suture on a CT-2 needle. The assistant frequently will assist by grabbing the needle with a tonsil clamp. A fin-

ger in the rectum can also help stabilize the needle.

Depending on the tissue, I will place one or two layers at this point. I will then close with the 3-0 Vicryl suture that I'd placed above and held, with a deep layer down and a subcuticular layer back up, with the knot just inside of the hymenal ring, similar to an episiotomy closure.

Although not glamorous, repair of a posterior wall defect can often be life changing for a patient. The ability to have bowel movements without manual manipulation, wear a tampon, or just regain confidence as a consequence of improved body image is invaluable.

Often, at the end of a long reconstructive case, the relative importance of a good colpoperineorrhaphy can be hard to appreciate. Yet, for the completion of pelvic floor function and anatomical outcomes, it is often a necessity.

Seventy-five to 95% of women will have good anatomical outcomes with this type of repair with similar improvements in splinting for defecation. ■

Dr. Fenner said she had no disclosures to report that are relevant to this article. E-mail her at obnews@elsevier.com.