

# Antigen Level May Reflect CNS Vasculitis Activity

BY KATE JOHNSON

QUEBEC CITY — Levels of von Willebrand's factor antigen have the potential to provide a sensitive, noninvasive way to monitor disease activity in children with vasculitis involving the central nervous system, Dr. Tania Cellucci and colleagues reported at the annual meeting of the Canadian Rheumatology Association.

Knowing that CNS vasculitis is an autoimmune condition that affects the blood vessel walls, Dr. Cellucci and her colleagues at Toronto's Hospital for Sick Children reasoned that it might impact the release of von Willebrand's factor (vWF) antigen. So they set out to explore vWF levels in 31 consecutive pediatric CNS vasculitis patients from diagnosis through 24 months of follow-up.

The single-center cohort study ran between June 1989 and October 2008. The median age of the patients at diagnosis was 9 years, and 52% were female.

Demographic, clinical, laboratory, imaging, and histologic data were examined at diagnosis and at regular intervals throughout follow-up. Disease activity was measured at diagnosis and every 3 months thereafter using the physician global assessment visual analog scale, and levels of vWF were also measured at these intervals.

Only 10% of the cohort had secondary CNS vasculitis, whereas the remainder had childhood primary angiitis of the

CNS (cPACNS), the researchers reported in their poster. More than half of the cohort (58%) had angiography-negative cPACNS, indicating small-vessel disease, whereas 32% had angiography-positive (large-vessel) cPACNS, which was divided evenly between the progressive and nonprogressive form.

As expected, abnormal levels of C-reactive protein (greater than 8 mg/L) and erythrocyte sedimentation rate (greater than 10 mm/h) were not consistent across the cohort at diagnosis, occurring in 20% and 55%, respectively. Leukocytosis (WBC greater than  $10 \times 10^9/L$ ) was present in 52%. Opening pressure on lumbar puncture (greater than 20 cm

H<sub>2</sub>O) was increased in 62%, and elevated cerebrospinal fluid protein (greater than 0.4 g/L) and cerebrospinal fluid leukocytosis (greater than  $5 \times 10^6/L$ ) were present in 54% and 72%, respectively. Abnormal magnetic resonance imaging was the most consistent finding, occurring in 94% of the cohort, with vasculitis on brain biopsy present in 71% and abnormal CNS angiogram present in 42%, they reported.

Disease activity decreased significantly and consistently from diagnosis and treatment initiation throughout the course of the study ( $P$  less than .0001), reported the researchers, although patients with angiography-negative cPACNS had consistently higher disease activity over time.

At diagnosis, the mean physician global assessment score for all patients with cPACNS was 5.7 for those with angiography-negative disease, and 6.5 for those with positive angiography. By 6 months, the mean scores for the angiography-positive patients had dropped to 1.2, whereas the mean angiography-negative score was 3.3. At 12 months, the mean score for the angiography-negative group was 1.6 vs. 0.9 for the angiography-positive group. Finally, at 24 months, the mean score for the negative group was 2.1, and 0.03 for the positive group.

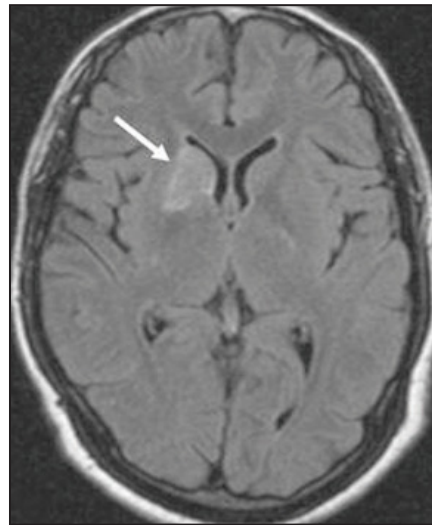
Mirroring disease activity scores, levels of vWF also decreased over time in all patients ( $P = .0084$ ) and mirrored disease activity scores, although they were

significantly different between subtypes of cPACNS ( $P = .0028$ ), reported Dr. Cellucci. The study demonstrates that vWF is a sensitive measure of disease activity, she said.

In the example of a stable patient who suddenly develops headaches or other symptoms, "a vWF level could help us figure out whether these new symptoms are due to active disease," said Dr. Cellucci, who is a fellow in pediatric rheumatology at the University of Toronto. "If vWF is now elevated—and the patient had a high vWF at diagnosis—then this is consistent with a disease flare and we would not need to repeat the invasive tests. If it is normal, then this suggests the new symptoms are not due to disease flare," she said. She did not define what an abnormal vWF might be, explaining that "all lab reports state the normal ranges for their lab and so the physician will be able to determine whether the level is abnormal or not."

Dr. Cellucci added that an elevated vWF level can also assist in the diagnosis of pediatric CNS vasculitis, but is not specific enough in isolation. Symptomatic patients would still need invasive diagnostic tests, but an elevated vWF would be consistent with CNS vasculitis, thus guiding the clinician in ordering the work-up, she said.

**Disclosures:** Dr. Cellucci had no conflicts of interest to report.



Hyperintensity (arrow) in a teen with CNS angiitis is shown on FLAIR image.

©2009 ELSEVIER INC.

## Rituximab Trial Is Underway in Juvenile Dermatomyositis

BY AMY ROTHMAN SCHONFELD

NEW YORK — Rituximab may offer an alternative treatment for children whose juvenile dermatomyositis does not respond to available therapies, depending on the outcome of an ongoing trial, Dr. B. Anne Eberhard said at a meeting sponsored by New York University.

There are no Food and Drug Administration–approved medications for juvenile dermatomyositis (JDM).

The RIM (Rituximab in Myositis) trial is a randomized, phase II, placebo-controlled, multicenter trial investigating the effect of rituximab on refractory dermatomyositis in children and adults. The study intended to enroll 50 children with JDM, and it will assess efficacy, safety, and determinants of treatment response and disease pathogenesis, including clinical, demographic, and immunopathologic factors.

The RIM trial results will be presented at the annual meeting of the American Academy of Rheumatology in November

2010, Dr. Chester V. Oddis said in an interview.

The study is sponsored by Genentech Inc., Biogen Idec Inc., and the National Institute of Arthritis and Musculoskeletal and Skin Diseases, according to Dr. Oddis, who is the principal investigator and a professor of rheumatology at the University of Pittsburgh.

Dr. Eberhard noted that prednisone and methotrexate are the mainstays of treatment, for now. However, outcomes can be unsatisfactory either because symptoms remain poorly controlled or because side effects occur.

JDM is a relatively rare idiopathic inflammatory myopathy that can be physically disabling, disfiguring, and life threatening if left unchecked.

To facilitate diagnosis of JDM, the Childhood Myositis Assessment Scale (CMAS) was recently developed to allow clinicians to assess children for JDM in the office without the need for specialized equipment. The

CMAS is a 14-activity, observational, performance-based assessment that measures physical function, strength, and endurance, explained Dr. Eberhard, who is a pediatric rheuma-

**Another recent advance in the care of youngsters with JDM is development of the Childhood Myositis Assessment Scale, which allows in-office evaluation of affected children.**

tologist at the Albert Einstein College of Medicine in New York. For instance, it can be used to compare, from one visit to another, how well a child can raise his head or leg, go from a supine to sitting position, rise from a chair, or step on a stool. An abbreviated 9-manuever test is also available.

Dr. Eberhard outlined other relatively simple ways to diagnose JDM in the office or at the bedside. The first is visual examination of the body, with a focus on skin changes, including the characteristic malar or but-

terfly rash on the bridge of the nose, cheeks and face; the classic reddish/purple heliotrope rash; and Gottron's papules on the extensor surfaces of the fingers. The rash typically appears on skin areas that are exposed to the sun, including elbows, knees, and ankles, so sunscreens and sun avoidance are advised for JDM patients. About 25% of patients present with subcutaneous calcinosis, which eventually affects 70% of patients.

To look for vasculopathy, examine the nail-bed capillaries with an ophthalmoscope, said Dr. Eberhard. In contrast to their normal, straight, "picket-fence" appearance, the capillaries in children with JDM show dilation and extensive branching; there may even be capillary loss. "You can quantify the disease and monitor improvement with treatment by examining nail-bed capillaries," she said.

Symmetrical proximal weakness is another hallmark of JDM. Dr. Eberhard said that she immediately thinks of JDM when she hears that a child is

having difficulty getting up the school bus stairs.

An urgent response is required if a child says that food is "sticking to his mouth." This suggests a bulbar muscle weakness of central origin, with impaired swallowing and the potential for aspiration. This may necessitate placing the child on a soft diet or even hospitalization, said Dr. Eberhard.

JDM can produce other serious sequelae, including pulmonary fibrosis and perforation of the esophagus or small bowel.

The original five diagnostic criteria that were first presented in 1975 did not change for the subsequent 35 years (*N. Engl. J. Med.* 1975;292:344-7). In addition to symmetrical proximal weakness and rash, the diagnostic criteria are raised serum muscle enzymes, electromyogram evidence of myositis, and histologic evidence of myositis. Diagnosis of JDM requires the presence of four of the five criteria, she said.

**Disclosures:** Dr. Eberhard had no relevant financial disclosures.