

## MASTER CLASS

## Cervical Cerclage



BY CHARLES E. MILLER, M.D.

Cervical cerclage involves the placement of sutures, wires, or synthetic tape to mechanically increase the tensile strength of the cervix. The procedure is done either electively or emergently (rescue) to reduce the risk of cervical insufficiency and the resultant second-trimester

recurrent pregnancy loss.

After reviewing the 2006 article in the *American Journal of Obstetrics and Gynecology* by Dr. Roberto Romero and his associates, the subsequent letter to the editors by Sietske M. Althuisius, Ph.D., and Pieter Hummel, Ph.D., and the author's reply, debate still lingers about whether credit should be given to Lazare Rivière, in his 1655 article published in Latin, for the first description of cervical insufficiency. By 1678, A. Cole, N. Culpepper, and W. Rowland described this entity in their book "Practice of Physick": "The second fault in women which hindered conception is when the seed is not retained or the orifice of the womb is so slack that it cannot rightly contract itself to keep in the seed; which is chiefly caused by abortion or hard labor and childbirth, whereby the fibers of the womb are broken in pieces one from another and the inner

orifice of the womb overmuch slackened."

Three hundred years later, in an 1865 letter to the editor of the *Lancet*, G.T. Gream described a patient who had previously undergone cervical surgery "as a cure for dysmenorrhea and sterility." Gream wrote: "She had arrived at about the fourth month of pregnancy; telling me—without, however, attributing her pregnancy to the operation—that the uterus had 6 years before been operated upon; and so complete had been the division of the cervix that the finger could readily be introduced into the uterine cavity, and the membranes of the ovum could be touched, as they can be sometimes during the last days of gestation. ... According to prognostications, abortion resulted but a few weeks afterwards, from the inability of the uterus to retain its contents."

V.N. Shirodkar, professor of midwifery and gynecology at Grant Medical College in Bombay, India, is credited with the introduction of cervical cerclage into modern obstetric practice in 1955. The need was based on his finding that "some women abort[ed] repeatedly between the fourth and seventh month and no amount of rest and treatment with hormones seemed to help them in retaining the product of conception." This was immediately followed by Ian McDonald's report from the Royal Melbourne Hospital on his cerclage experience in 70 patients in 1957.

In this edition of Master Class in Gynecologic

Surgery, I have asked Dr. Andrew I. Brill, director of minimally invasive gynecology, reparative pelvic surgery, and training at the California Pacific Medical Center, San Francisco, and former president of the AAGL, as well as Dr. Michael Katz, clinical professor of obstetrics, gynecology, and reproductive sciences, University of California, San Francisco, and chief of perinatal services at California Pacific Medical Center, to discuss interval cervicoisthmic cerclage, with an emphasis on a laparoscopic approach.

Dr. Brill coauthored the first report on a laparoscopic preconceptional cervicoisthmic cerclage in a woman with repeated midtrimester cervical cerclage failure for the *Journal of Minimally Invasive Gynecology*. Despite being an experienced vaginal surgeon and having extensive experience in classical transvaginal cervicoisthmic cerclage, upon observing Dr. Brill's laparoscopic technique, Dr. Katz became familiar with the benefits of this approach. It is our intent that after reading this edition of the Master Class in Gynecologic Surgery, you will, too. ■

DR. MILLER is clinical associate professor, University of Chicago and University of Illinois at Chicago, and president of the AAGL. He is a reproductive endocrinologist in private practice in Schaumburg, Ill., and Naperville, Ill., and the medical editor of this column.

## Interval Cervicoisthmic Cerclage: Its Time Has Come

For more than a decade, the capacity to perform cervicoisthmic cerclage by laparoscopy has provided a minimally invasive alternative for some women to the often-complicated traditional abdominal approach that was first reported in 1965.

With a laparoscopic cerclage performed by 12 weeks' gestation, patients for whom conventional vaginal cerclage has failed or is not possible have had successful deliveries without the extended midline incision, considerable hospital stays, or significant risks to the mother and fetus that are associated with the conventional abdominal approach.

Laparoscopic cerclage is a highly innovative procedure that has offered hope and delivered good outcomes. Still, one has to ask, are we really achieving all we can for our patients?

Does it not make sense to intervene earlier—before pregnancy—in certain high-risk women with anatomically altered or deficient cervixes and/or with previous failures of conventional vaginal cerclages for cervical incompetence?

The notion of "interval cerclage" as opposed to interventional or "rescue" cerclage is an idea whose time has come. There are significant numbers of women who would substantially benefit from the insertion of a cervicoisthmic cerclage in the nonpregnant state—when the surgeon is not constrained by the contents, size, or fragility of the gravid uterus or challenged by the marked pelvic vascularity and other physiological changes of pregnancy.

The pregnant women who have un-

dergone laparoscopic cervicoisthmic cerclage under our care have experienced failures of conventional vaginal cerclages, and many have suffered repeated second-trimester losses.

These high-stakes cases involving patients who are desperate for a successful pregnancy have led us to believe that one failure is enough—or, in the cases of patients who have other clear risk factors such as anatomically altered cervixes, that one failure is too many.

As we move further into the era of reproductive technology and extended reproductive years, pregnancies are increasingly high-stakes experiences with a limited number of assisted cycles. Women do not have time to spare and do not want to take risks. Older women seeking to have a child not only are more likely to have had in vitro fertilization and other fertility treatments, they also are more likely to have had a loop electrosurgical excision procedure (LEEP), cone biopsy, or other procedure that has been associated with cervical incompetence. Many of these women are possible candidates for interval cerclage.

This type of cerclage requires a new thought process—a new mind-set—as well as new and creative collaboration between skilled laparoscopic surgeons and the perinatologists who are following and counseling these patients.

By working in teams, with the perinatologist cultivating a relationship with an experienced laparoscopic surgeon, specialists can work together to bring the option of interval cerclage into discussions with patients who have poor obstetric his-

ories due to cervical incompetence or serious risk factors associated with poor pregnancy outcomes, and then see the procedure through when it is deemed worthwhile and desirable.

In our experience, once we met each other and became aware of each other's interests and expertise, it seemed only natural to collaborate and offer these patients interval laparoscopic cerclage.

## The Benefits

Ironically, we have shifted in the last 5-10 years from early-pregnancy cerclage based largely on history toward cerclage that is performed based on ultrasound measurement of cervical length during pregnancy. Cervical change rarely occurs before 12-14 weeks' gestation, which means that by the time of "discovery" of a short cervical length, cerclage is all the more difficult and risky to perform.

The advantages to an interval approach to cerclage are numerous: The surgeon does not have to contend with the burden of an intrauterine pregnancy associated with the increased pelvic vascularity of pregnancy (up to 25% of the maternal circulation moves through the pelvis at this time) or the increased uterine size, which can be constraining, particularly for a laparoscopic approach.

Beyond 12-14 weeks, in fact, it becomes almost impossible with a laparoscopic approach to gently manipulate the uterus to see both the front and back of the lower uterine segment. Avoiding interventions close to the gravid uterus, of course, is always desirable. And with an interval

cerclage, healing is typically completed by the time pregnancy occurs.

For a surgeon with advanced laparoscopic experience, the laparoscopic approach to a cervicoisthmic cerclage is generally much easier and safer than a "true" transvaginal cervicoisthmic cerclage.

Some experienced surgeons—though very few—have performed classical cervicoisthmic cerclage transvaginally during early pregnancy in the belief that a higher cerclage placement is more effective than a lower one. When the stitch is placed high at the level of the cervicoisthmic junction—or even higher—and above the level of the cardinal ligaments, the stitch is less likely to slip down along the cervix. It is supported from under-

neath by the cardinal ligaments. The normal cervix can be anatomically represented by the letter Y. Then imagine it becoming the letter V, and then the letter U. This is the type of change that an incompetent cervix undergoes. If we can prevent, as much as possible, the formation of the V, then these changes are less likely to occur.

Although there is no scientific evidence, per se, to support this "higher is better" belief, it makes intrinsic sense, and there are data to suggest better outcomes with this higher stitch placement. Our experience shows that the vast majority of patients with previous failed cerclages had the conventional vaginal procedure, a simple Mersilene purse-string stitch placed low in the cervical stroma, not approximating the internal os where deformities typically are.

Continued on following page



BY DR. ANDREW I. BRILL



BY DR. MICHAEL KATZ

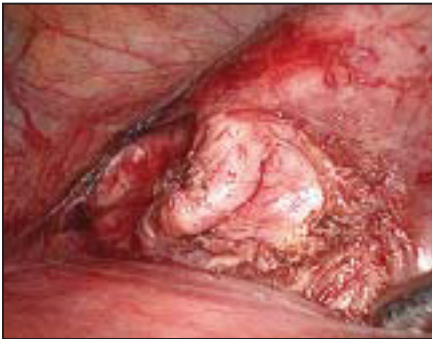

Continued from previous page

The problem is that transvaginal insertion of a cervical suture high at the level of the cervicoisthmic junction is complex and fraught with the risk of complications because the high stitch placement involves mobilizing and climbing up under the bladder, in close proximity to the vasculature of the uterus. Some surgeons have had success, but in general, what needs to be done exceeds the skills and experience of most.

In patients who are pregnant, traditional abdominal cervicoisthmic cerclage—the other alternative—has been associated with severe complications, such as hemorrhage and pregnancy loss. (Our sense is that few of these surgeries are performed because the stakes are so high and the risks so real.) Patients who are not pregnant still face an extended midline incision and a considerable hospital stay.

With laparoscopy, we can achieve the

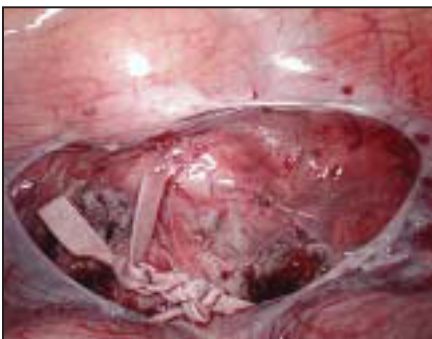

**Figure 1. Uterine artery is skeletonized at isthmus for medial stitch placement in an 11 weeks' gravid uterus.**

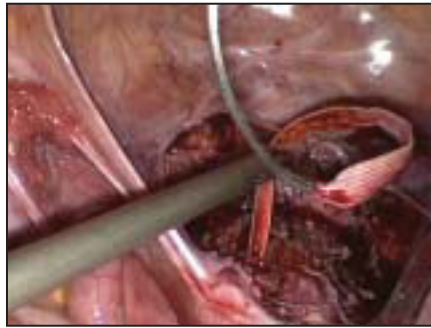
higher is better principle less invasively with more ease and superior precision. Compared with the vaginal or laparotomic approach, the laparoscopic method provides less trauma to the gravid uterus and unparalleled visual and mechanical access to the key anatomical structures either incorporated or potentially injured during cervicoisthmic cerclage. Placing the stitch precisely at the correct level is the most important element of this procedure.

Moreover, laparoscopic placement of the tape may reduce the recognized incidence of postoperative chorioamnionitis by removing the presence of a foreign body in the vagina. A first-trimester loss can usually be evacuated using conventional techniques, while elimination of more-advanced gestations can be simply facilitated by removing the stitch laparoscopically.

Whereas patients undergoing laparoscopic cervicoisthmic cerclage still must have a laparotomy at the end, because the



**Figure 2. Mersilene tape is tied extracorporeally upon clarified pubocervical fascia in a 12 weeks' gravid uterus.**



**Figure 3. Classical passage of Mersilene suture is shown during interval cervicoisthmic cerclage after prior trachelectomy.**

cerclage is a permanent suture and necessitates delivery by cesarean section, morbidity and mortality risks are cut in half compared with patients undergoing two traditional abdominal surgeries.

Success rates after cervical cerclage are high, up to 87%. The interpretation of outcome is complex, however, because of the conflicting indications for treatment and differing timing of the procedure (before or during pregnancy). Quality research comparing approaches in patients with high-risk indications has been difficult to conduct as well, in part because patients who have had recurrent pregnancy failures are reluctant to participate in such studies.

Much of the available data, moreover, is confounded by a multiplicity of high-risk factors and variables related to recurrent pregnancy loss.

#### Dr. Brill's Technique

Patients are placed in a modified dorsal lithotomy position, and a No. 12 Foley catheter is inserted for bladder drainage. When the patient is pregnant, I perform an assiduous pelvic exam to assess for advanced cervical dilation.

In gravid patients, the largest cervical cup from a disassembled KOH colpotomizer is used to laparoscopically delineate the vaginal fornices and atraumatically manipulate the cervix and lower uterine segment by using two ring forceps secured opposite one another to the outer ring.

Fetal heart tones are documented before the laparoscopic procedure is initiated. The risk of incidental trauma to the gravid uterus is minimized by using open laparoscopy to attain peritoneal access.

The intra-abdominal pressure is strictly limited to 12 mm Hg, and all patients are placed in a maximally tolerated Trendelenburg position. I then determine the feasibility of the procedure based on an assessment of anatomical access and ready mobility of the gravid uterus.

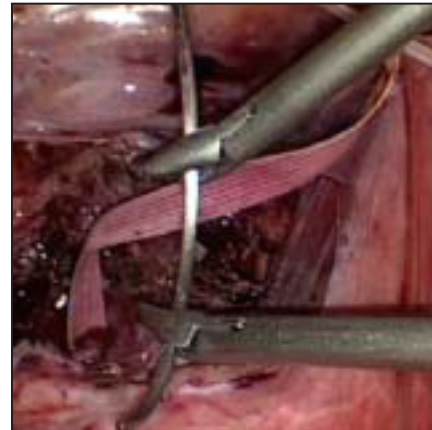Two 5-mm midquadrant ports are placed under direct vision, each lateral to the respective epigastric arteries and slightly below the level of the umbilicus. A 10-mm port is carefully introduced in the midline, one to two finger breadths above the pubic ramus.

The vesicouterine peritoneum is dissected transversely using either a monopolar spatula electrode or the 5-mm curved Harmonic shears. The uterus is mobilized using the pericervical cup and a 5-mm blunt probe.

The bladder is then minimally dissected off the lower uterine segment to reveal

native pubocervical fascia and the course of the uterine vessels. With a combination of blunt and sharp dissection, an adequate surgical window is created medial to each set of uterine vessels at the level of the isthmus (Figure 1).

A 5-mm Mersilene tape is prepared by removing the attached curved needles, and the suture is then introduced into the posterior pelvis through the 10-mm suprapubic port. A 10-mm right-angle forceps through the suprapubic port is used to grasp and position the ligature around the lower uterine segment at the level of the isthmus by first piercing through the surgical windows in an anterior-to-posterior direction to then grasp and withdraw each end of the su-



**Figure 4. Needle is positioned for completion of cervicoisthmic cerclage after prior trachelectomy.**

ture back into the vesicouterine space.

Care must be taken to confirm that the tape is flatly applied to the posterior lower uterine segment. The suture is then tied intracorporeally on the pubocervical fascia with at least five knots (Figure 2).

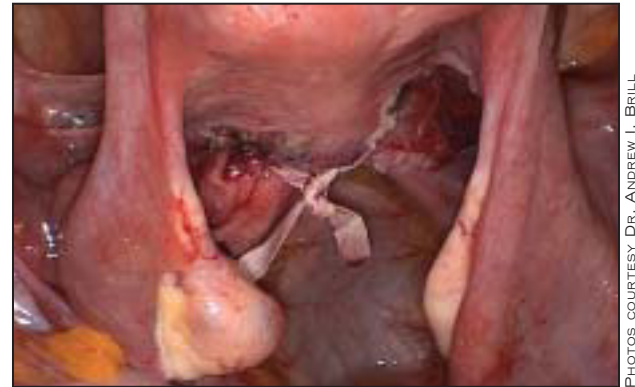Whenever possible the vesicouterine peritoneal defect is closed with a running suture and tied extracorporeally. A vaginal exam is then performed to ensure that the suture ligature is above the level of the vaginal fornices. Fetal heart tones are once again documented.

In nongravid patients, a conventional uterine elevator is used for uterine manipulation. Conventional closed laparoscopic techniques are used for peritoneal access. Lower-quadrant trocar sites are lateral to the inferior epigastric vessels and usually at the level of the anterior superior iliac spines.

Whereas I employ the same dissection and suture ligature techniques used during the early cases of interval cerclage, more recently I have employed the classical technique using the two attached 48-mm needles to direct the Mersilene tape through the broad ligament just medial to the uterine vessels at the level of the isthmus.

After dissection of the anterior lower uterine segment to mobilize the bladder and to expose the uterine vessels, the uterus is anteverted and windows are created in the posterior broad ligament to expose the course of the uterine vessels.

The large needles still attached to the tape are introduced into the abdomen



**Figure 5. Mersilene tape is tied extracorporeally during interval cervicoisthmic cerclage.**

through one of the exposed lateral trocar sites by successively grasping each end of the suture several centimeters from the swedge point and then directing the needles through the abdominal wall and then into the peritoneal cavity under direct vision. Using the uterine elevator to retroflex the uterus and then expose the anterior lower uterine segment, I drive each needle medial to the uterine vessels perpendicularly to exit posteriorly as the uterus is simultaneously anteflexed to expose the broad ligament windows (Figures 3 and 4).

Once tightened around the lower uterine segment at the level of the isthmus, the tape ends are cut to release the needles, which are then extracted through the open suprapubic port site by reversing the maneuver used for their introduction. Care must be taken to confirm that the tape is flatly applied to the anterior lower uterine segment. The ligature ends are then tied together posteriorly by intracorporeal knot tying and are not peritonealized (Figure 5). ■

Neither Dr. Brill nor Dr. Katz reported any disclosures that are relevant to this article.

## Dr. Brill's Experience

Over the last 5 years, I have performed laparoscopic cervicoisthmic cerclage under general anesthesia in 23 patients who had documented histories consistent with cervical incompetence.

There have been 18 successful deliveries (at a mean gestational age of 36.6 weeks) with a fetal salvage rate of 78% (18/23), compared with 7.3% (6/82) during all of the patients' previous intrauterine pregnancies. In 12 of the 23 cases (52%), the cerclage was performed preconceptionally as an interval procedure. In the remaining 11, cerclage was performed during early pregnancy (at a mean gestational age of 12 weeks). Three of the cases were ultimately completed laparotomically—two secondary to pelvic adhesions and the other secondary to bleeding. In the 11 pregnant patients, only two losses occurred intraoperatively—one secondary to advanced cervical dilation and one for undetermined reasons 10 days postoperatively.