

Use of Glycoprotein Inhibitor For Bypass PCI Linked to MIs

ARTICLES BY
MITCHEL L. ZOLER
Philadelphia Bureau

PONTE VEDRA BEACH, FLA. — Administration of an antiplatelet IIb/IIIa drug to patients undergoing percutaneous coronary intervention for bypass-graft stenosis significantly boosted the incidence of myocardial infarctions in a registry with more than 34,000 patients.

The study used data from the American College of Cardiology National Cardiovascular Data Registry, which included more than 448,000 percutaneous coronary interventions (PCIs) done during 2001-2003, reported Satish K. Surabhi, M.D., at the annual meeting of the Society for Cardiovascular Angiography and Interventions.

The registry included 34,720 patients who had PCI of a coronary artery bypass graft; 24,279 (70%) were treated with a glycoprotein IIb/IIIa inhibitor and 10,441 (30%) were not.

Following PCI, the in-hospital mortality rate was almost identical in the two subgroups: a 1.4% death rate in patients who received a IIb/IIIa inhibitor and a 1.3% rate in those who didn't get the drug.

In the first weeks following PCI, the incidence of MIs was significantly higher in patients treated with a IIb/IIIa inhibitor, 2.4% than in

those who did not, 1.4%. The MIs included all new ST-segment elevations, Q-wave events, left bundle branch blocks, and elevations in serum levels of creatine kinase that exceeded three times the upper limit of normal.

In a multivariate analysis that controlled for various baseline differences in demographic and clinical variables, use of a IIb/IIIa inhibitor was linked with a significant 63% increased rate in MIs following PCI, said Dr. Surabhi, a cardiologist in private practice in Greer, S.C.

Most patients in this registry were not treated with a distal protection device, which may have been the most important element of their management, he said. "Only 5% of these patients were treated with a distal protection device. The major factor [causing bad outcomes] seems to be distal embolization, not formation of a thrombus."

If a distal protection device or distal balloon occlusion is not used during a PCI of an aortocoronary bypass graft, then the patient should not receive a IIb/IIIa inhibitor, on the basis of the new findings, said Dr. Surabhi.

The study did not address whether it's useful to use a IIb/IIIa inhibitor to treat a patient who's undergoing a bypass graft PCI with distal protection, but Dr. Surabhi suggested that adding the drug may not help. ■

Critical Carotid Stenosis Boosts Poststenting Stroke

PONTE VEDRA BEACH, FLA. — Patients with critical carotid stenosis were more likely to have a stroke following carotid artery stenting than were those without critical stenosis in a study with 350 patients.

But this doesn't mean that stenting is not a good option for these patients. Although endarterectomy is also a "viable option" for patients with critical carotid stenosis, "these patients would be challenging for endarterectomy as well" because they are at high risk for stroke after any carotid intervention, David S. Lee, M.D., said at the annual meeting of the Society for Cardiovascular Angiography and Interventions.

In the study, critical carotid stenosis was defined as a stenosis of at least 90% that also required balloon predilation before it was possible to pass an embolic-protection device through the affected coronary artery. The need for predilation "was a marker for complex lesions and complex vessel morphology," said Dr. Lee, a cardiologist at the Cleveland Clinic Foundation. ■

The study involved the 350 patients in a registry of those who underwent carotid stenting with an embolic protection device during August 1999–October 2003 at the Cleveland Clinic, of whom 21 required balloon predilation of their affected coronary artery to allow passage of an embolic protection device. All 350 patients began treatment with both aspirin and a thienopyridine (either clopidogrel or ticlopidine) at least 24 hours before their carotid procedure, and with unfractionated heparin during procedure. After the procedure, aspirin and thienopyridine treatment was continued for at least 4 weeks.

The study's primary end point was the incidence of stroke within 30 days of stenting. Two strokes occurred among the 21 patients with critical carotid stenosis (9.5%), and seven occurred among the other 329 patients (2.1%), a significant difference. The two strokes in the patients with critical carotid stenosis were not secondary to the balloon predilation procedures, Dr. Lee said. ■

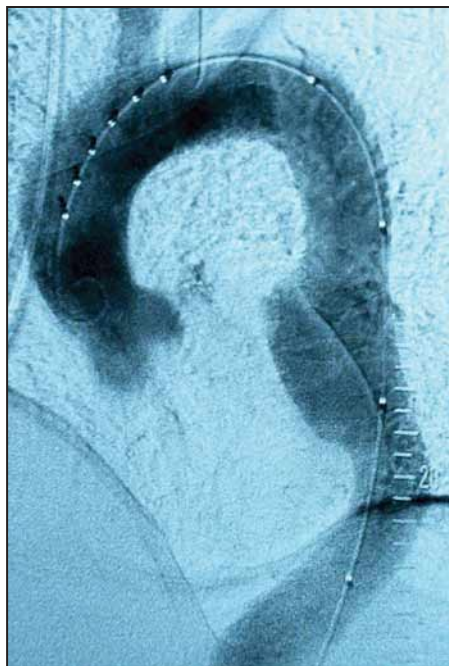
Thoracic-Aorta Endografts Expand Options for Aneurysms, Dissections

PONTE VEDRA BEACH, FLA. — Now that the first thoracic-aorta endograft is on the U.S. market, a revolution has begun in managing thoracic aorta aneurysms and dissections.

"This is a big deal. Dramatic changes are taking place in managing thoracic-aorta diseases," Alan B. Lumsden, M.D., said at the annual meeting of the Society for Cardiovascular Angiography and Interventions.

On March 23, the Food and Drug Administration approved the Gore TAG endoprosthesis for repair of aneurysms in the descending thoracic aorta. Several additional endoprostheses are in development, and the types of patients who are candidates for receiving these devices are expanding.

Thoracic-aorta aneurysms appear to be less prevalent than abdominal-aorta aneurysms, but thoracic defects also are underdiagnosed. Current prevalence numbers are 10.4/100,000 people. The risk factors for both abdominal and thoracic aneurysms largely overlap. The incidence of thoracic aneurysms increases markedly as people age, and the incidence also seems to be increasing overall in the United States, said Dr. Lumsden, chief of the division of vascular surgery



A descending thoracic-aorta aneurysm is repaired with an endovascular stent.

usually have not been done until the aneurysm reached about 6 cm in diameter because of the high rate of surgical complications. In patients without Marfan's syndrome, an ascending thoracic aneurysm usually has been repaired when it reached 5.5 cm in diameter, and a descending thoracic aneurysm has been repaired when it reached 6.5 cm. In patients with Marfan's syndrome, the thresholds for repair have usually been scaled back by 0.5 cm.

Endovascular repair is already the treatment of choice for symptomatic patients and those with a risk of an impending rupture. But increasingly,

more complicated aneurysm patients, as well as patients with uncomplicated aortic dissections, will be treated endovascularly.

Several recent reports have documented new types of surgical procedures that have "increased the landing zone" for endovascular stenting. "In the past, we were limited by the location of the celiac, subclavian, and carotid arteries, but now there are good ways to move those around," he said. ■

Lubricant Helps Slip Stents Into Tight Coronary Arteries

PONTE VEDRA BEACH, FLA. — When a coronary artery is too tight to accommodate a stent, it may be necessary to apply a little grease.

A lubricant suited to the job was an olive oil and egg yolk phospholipid-based emulsion sold commercially as Rotaglide, Mark Awar, M.D., and associates reported in a poster at the annual meeting of the Society for Cardiovascular Angiography and Interventions.

The 20 patients in the series they reported on were those who failed initial stent placement out of 813 consecutive patients who underwent a percutaneous coronary intervention at Jefferson Medical College in Philadelphia.

In these 20 cases stent delivery was unsuccessful despite predilation and several other steps: substitution of a moderate-to-stiff guidewire, reattempts with a new guiding catheter or a new stent, use of a buddy wire, and in one case use of rotational atherectomy. After failed delivery, the stents were removed from their guiding catheters, saturated with Rotaglide using a 20-cc syringe, and a second delivery was immediately attempted.

Application of Rotaglide led

to successful delivery for 17 of the 20 stents, reported Dr. Awar, a cardiologist at Jefferson. Angiography showed excellent anatomic results in all 17 patients. There were no major adverse coronary events or subacute stent thromboses.

All 20 patients had arteries with complex anatomy and unfavorable morphologic features: 17 (85%) had tortuous vessels, 13 (65%) had calcification, and 10 (50%) had diffuse disease (several patients had more than one feature). The target vessels included 10 left circumflex arteries, 8 right coronary arteries, and 2 left anterior descending arteries. Average patient age was 69 years, and 75% were men.

Use of Rotaglide to smooth the way for a stubborn stent had previously been reported in isolated case studies, but not in such a large series. Prior reports also have documented up to a 4% rate of failure in delivering stents to their target lesions (in this series the rate was 2.5%: 20 out of 813).

Rotaglide is sold by Boston Scientific to reduce catheter friction during rotational atherectomy.

The study was not sponsored by Boston Scientific. ■