

## Ubiquitous Nickel Is Named Contact Allergen of the Year

BY DOUG BRUNK  
San Diego Bureau

The American Contact Dermatitis Society has proclaimed nickel as its 2008 Allergen of the Year because of its rise as a cause of significant contact dermatitis in the United States, particularly among children.

"To dismiss nickel's importance and relevance to public health and skin disease, would be a mistake," said Dr. Kathryn A. Zug in an article scheduled for publication in the Jan./Feb. issue of *Dermatitis*.

The metal can be found in coins, jewel-

thought to have a nickel allergy of either current or past relevance.

"NACDG data [also] show that as in adult females, nickel sensitization in girls is on the rise," wrote Dr. Zug, the immediate past president of the American Contact Dermatitis Society, who cowrote the article with Rachel Kornik, a fourth-year medical student at Dartmouth.

The prevalence of nickel allergy in girls and women is probably mostly due to ear piercing and sensitization from some jewelry, Dr. Zug said in an interview. Sensitization is higher in men with pierced ears.

Health providers should also consider:

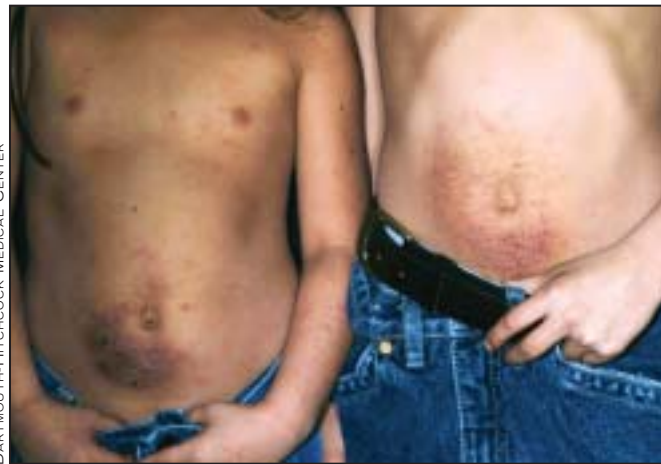► **Complications related to biomedical devices.**

Although reactions to medical-grade stainless steel is uncommon in nickel-sensitized patients, orthopedic surgeons and orthodontists still consult dermatologists about the safety of metal medical devices, the authors wrote. In addition, in patients who undergo endovascular stenting, evidence that nickel allergy is associated with stent restenosis

"remains in question."

► **Ingestion of dietary nickel.** Nickel is found in foods such as legumes, nuts, grains, chocolate, and fish, as well as medications and vitamins.

► **Prevention of contact allergy to nickel is challenging.** The best approach is to find ways to reduce sensitization. Regulation of nickel release from consumer goods "would be a challenging but potentially successful solution," wrote the authors, who reported no conflicts of interest. ■



The nickel allergy with autoeczematization in these siblings was probably caused by belt buckles or clothing snaps.

ry, buckles, pant snaps, tools, and other products, noted Dr. Zug of the department of dermatology at Dartmouth Hitchcock Medical Center, Lebanon, N.H.

Data from the North American Contact Dermatitis Group (NACDG) have shown that the number of patients who patch-tested positive for nickel grew from 11% in 1985-1990 to 19% in 2003-2004. Of 391 children who were patch-tested by the group from 2001 to 2004, 28% had a positive patch test to nickel, and 26% were

## CDC to Investigate Baffling Skin Condition Known as Morgellons

BY SHARON WORCESTER  
Southeast Bureau

The Centers for Disease Control and Prevention is launching a study to improve understanding of an unexplained and controversial dermatologic condition known as Morgellons, which is affecting an increasing number of individuals in the United States and abroad, the agency announced last month.

Little is known about the cause of the condition, which is characterized by a range of dermatologic symptoms, including rashes and sores that occur in association with abnormal crawling, biting, or stinging sensations. Patients often describe having threads, fibers, or foreign materials underneath or protruding from the skin in affected areas. Fatigue, mental confusion, memory loss, joint pain, and changes in vision have also been reported.

Some medical professionals consider Morgellons to be a manifestation of other medical or psychological conditions, including delusional parasitosis, but experts are divided on the topic.

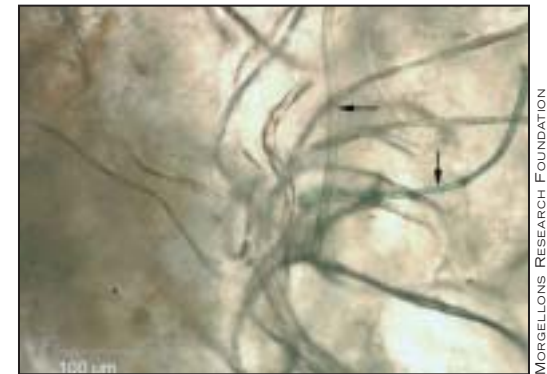
"What is clear is that those who suffer from this condition, as well as their family members and their physicians, have questions," Dr. Michele Pearson said during a press briefing held to announce the study's launch.

It is also clear that the symptoms and the suffering of patients are very real, said Dr. Pearson, principal investigator for the CDC, in response to questions from the media about whether Morgellons is a "real disease."

The study will be conducted in conjunction with Kaiser Permanente Northern California, because it has a large pop-

ulation of members and because of its research capabilities. In addition, northern California is one of the areas in which cases have been geographically concentrated, Dr. Joe Selby, director, division of research, Kaiser Permanente Northern California said during the briefing.

Cases have also been reported in Canada, Australia, and several European countries. The CDC has received about 1,200 inquiries about the disorder, and some estimates put the number of



Arrows point to fibers from a facial lesion that are similar to what some patients say are characteristic of Morgellons. Some physicians consider the condition a manifestation of medical or psychological conditions.

self-reported cases at about 10,000.

The researchers aim to determine the prevalence, as well as to identify epidemiological, clinical, and histopathologic features of the condition. Patient recruitment will begin immediately. Participants will undergo a detailed general, dermatologic, and mental health evaluation; skin biopsies; and blood tests.

"[Morgellons] is complicated, and it may involve multiple factors... but we believe this study will provide useful information to the medical community, and—most importantly—to those who suffer with this disorder," said Dr. Pearson. ■

## Get MRIs for All Dermoid Cysts, Except Some on Eyebrows

BY SHERRY BOSCHERT  
San Francisco Bureau

SAN FRANCISCO — Nearly half of congenital dermoid cysts on infant heads may have risky intracranial connections that link the brain to the outside world.

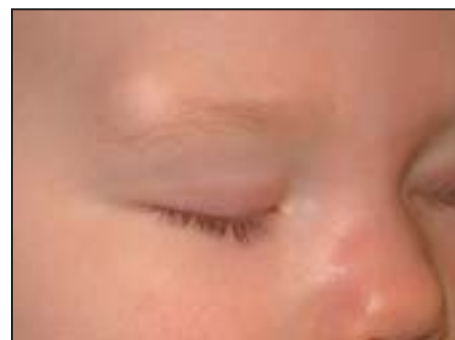Tracts that expose the brain put a child "at higher risk for meningitis and abscess formation," Dr. Brandie J. Metz said at a meeting sponsored by Skin Disease Education Foundation. Fortunately, dermoid cysts in the most common location—the lateral third of an eyebrow—have never been reported to contain intracranial connections.

Dermoid cysts also can occur on the midline nasal bridge, the scalp, the anterior or lateral neck, or postauricular areas, and may need imaging to check for intracranial connections, said Dr. Metz, chief of pediatric dermatology at the University of California, Irvine.

Congenital dermoid cysts are epithelial-lined cysts containing epidermal ap-

pendages such as hair, sebum, and sebaceous and apocrine glands. They are formed as the embryonic fusion lines of the skull close and structures get sequestered into the skin. In some reports, almost half are associated with intracranial connections.

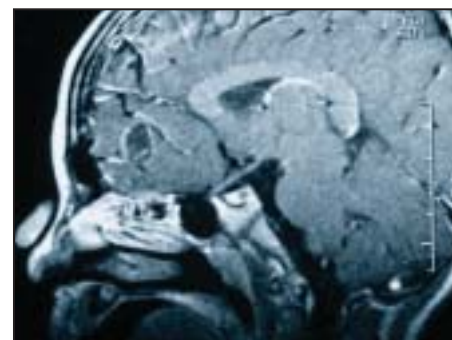
Dermoid cysts in the nasal or midline scalp regions are more likely to have intracranial extensions. Dr. Metz recommended getting MRI exams of all con-



Dermoid cysts at the lateral third of the eyebrow don't need radiologic imaging.

genital dermoid cysts on the scalp, especially if there's an overlying hair collar sign (longer, courser, darker hair surround the scalp nodule) or capillary stain, or if the cyst is in an atypical location. All midline dermoid cysts deserve imaging as well, especially if there are sinus pits or hairs projecting from the cyst, she said.

Most dermoid cysts appear at birth, and 70% are visible by age 5 years. They present



Here, an MRI of a midline nasal dermoid confirms an intracranial connection.

as soft, rubbery, mobile subcutaneous tumors. Dermoid cysts on the nose can appear anywhere from the glabella down to the tip of the nose, and may present with a subtle appearance—"just a kind of yellow broadening of the tip of the nose or the nasal bridge," Dr. Metz said. An MRI will show the extent and nature of the lesion and can rule out intracranial connection.

The one scenario in which a CT scan may be preferable is in an older child with a very long, thin lesion in a classic location. Dermoid cysts that have been present for a long time can cause bony erosions.

"[In] a teenager with a dermoid cyst in a very classic location, you're not looking for an intracranial connection but rather to determine if there's any bony defect, CT might be useful," she said. If it is found that there is intracranial connection, the patient should be referred to a neurosurgeon for surgical removal of the connection.

SDEF and this news organization are wholly owned subsidiaries of Elsevier. ■