

Endometrial Polyps: Transvaginal US Falls Short

Polyps 'confined to the lower uterine segment and midbody were much harder to detect.'

BY DOUG BRUNK

FROM THE ANNUAL MEETING OF THE AMERICAN INSTITUTE OF ULTRASOUND IN MEDICINE

SAN DIEGO — Almost half of endometrial polyps seen on sonohysterography were missed on transvaginal ultrasound, results from a large single-center study showed.

The factors associated with lack of detection on ultrasound included smaller polyp size, multiplicity, submucosal

fibroids, location of polyps, and blood flow to the polyps, Dr. Alex Hartman said at the meeting.

Between January and May of 2009, Dr. Hartman and his associates performed a blinded retrospective case study of 800 consecutive patients (mean age, 48 years) diagnosed with endometrial polyps on sonohysterography who also had preliminary transvaginal ultrasound within 48 hours of the sonohysterography.

The researchers assessed multiple factors, including patient age, size of the polyp, number of polyps, submucosal fibroids, intramural fibroids, adenomyosis, location of the polyp, and blood flow. Pearson's chi-square tests and t-tests were used to compare the two samples.

Dr. Hartman, medical director of True North Imaging in Thornhill, Ont., reported that 433 patients (54%) with polyps diagnosed on ultrasound had their polyps seen on transvaginal ultrasound.

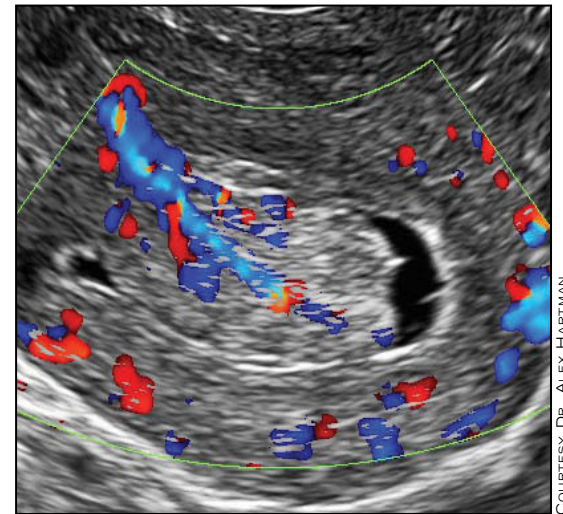
The factors significantly associated with detection of a polyp on preliminary transvaginal ultrasound included larger polyp size (in general, the larger, the more likely seen); the presence of multiple polyps; the absence of submucosal fibroids; fundal location of the polyp; and the presence of blood flow to the polyp.

"Over the years, we found that polyps that were located in the fundus were much easier to see," Dr. Hartman commented. "The ones that were confined to the lower uterine segment and midbody were much harder to detect."

He also noted that 39 of the 800 patients (5%) also had submucosal fibroids.

"Interestingly, only one-third of the polyps in these patients were diagnosed in the preliminary ultrasound study," Dr. Hartman said.

"So the presence of submucosal fibroids made it very difficult to see polyps



Sonohysterogram of a polyp: The blue and red represent blood flow. A large artery goes through the polyp's center.

COURTESY DR. ALEX HARTMAN

on regular ultrasound," he added.

Factors that were not significantly associated with the detection of a polyp on preliminary transvaginal ultrasound were age, endometrial thickness, adenomyosis, polycystic ovaries, abnormal bleeding, and fertility status. ■

VITALS **Major Finding:** Transvaginal ultrasound missed 46% of endometrial polyps that were seen on sonohysterography.

Data Source: A single-center, blinded retrospective case study of 800 women with endometrial polyps.

Disclosures: None was reported.

DMPA-IM, DMPA-SC: Few Side Effect Differences Seen

BY ROBERT FINN

FROM THE ANNUAL MEETING OF THE NORTH AMERICAN SOCIETY FOR PEDIATRIC AND ADOLESCENT GYNECOLOGY

LAS VEGAS — The intramuscular and subcutaneous formulations of depot medroxyprogesterone acetate seem to have similar side effect profiles in adolescents, according to a randomized crossover study.

Although the side effects of the two formulations (DMPA-IM and DMPA-SC) have been studied in adult women, this is the first study among adolescents, Dr. Rebekah L. Williams said at the meeting.

The randomized crossover study involved 55 young women aged 14-20 years, with a mean of 16.5 years. All participants were either initiating or restarting DMPA therapy.

Among the young women, 85% were African American and 20% said they had never had sex.

At baseline the participants completed surveys about their expectations regarding the side effects, and they were randomized to receive one of the two formulations.

At the end of 3 months, participants answered questions about side effects, and then they were given the other formulation.

At the end of another 3 months, the participants were again surveyed, after which they were permitted to choose which formulation they preferred for a third injection. Thirty-eight of the women completed surveys at all three visits.

The investigators found no significant differences between the two formulations in participants' expectations or experience of physical or sexual side effects.

In addition, the experience of side effects was not significantly related to expectations of side effects,

participants' level of general worry, or their level of general concern about birth control side effects.

Furthermore, with two exceptions, there was no difference in the expectation or experience of side effects between the participants' first and second injections, no matter in which order they received them.

The two exceptions were amenorrhea and irregular bleeding. During the first dose, 10.5% of the participants had amenorrhea, and this increased significantly to 31.6% at the second dose. In contrast, the proportion of women reporting irregular bleeding declined significantly from 26.3% at dose one to 7.9%

at dose two.

Dr. Williams of Indiana University, Indianapolis, noticed a mismatch between expectations and experience for sexual side effects.

"Over one-third of our sample experienced some change in sexual interest, and one-quarter experienced changes in lubrication during sex," she said.

"The striking difference between expectations between physical and sexual side effects may reflect our clinical practice, in that physical side effects are emphasized during contraceptive counseling but sexual side effects may be relatively neglected.

"Clinical counseling should include both physical and sexual side effects, both of which have the

VITALS **Major Finding:** No significant differences were found in physical or sexual side effects in adolescents taking DMPA-IM and DMPA-SC.

Data Source: Randomized crossover trial of 55 adolescents.

Disclosures: The study was supported by the National Institutes of Health, the Health Resources and Services Administration, and the Indiana Clinical and Translational Sciences Institute. Dr. Williams said she had no conflicts of interest.

potential to significantly impact young women's contraceptive use in the long run."

One difference between the intramuscular and subcutaneous formulations emerged when the women were allowed to choose which one they would receive at the third visit. Of the 38 women who made it to that visit, 26 chose a subcutaneous injection, 9 chose an intramuscular injection, and 3 chose to discontinue DMPA.

"I'm not 100% sure why we [saw] such a striking preference," Dr. Williams said, noting that there were no reported differences in injection pain during the injection, immediately after the injection, or 7 days later.

"I'm not sure if we're using the wrong pain measures, the wrong side effect measures, or if those just aren't the things that influence it," she said.

"All of our [intramuscular injections] were gluteal, and all of our [subcutaneous injections] were abdominal. Maybe there was a preference for just lifting your shirt up a little bit and getting your shot instead of yanking your pants down a little bit and getting your shot.

My research assistant is now probing our exit interviews at two different points in the study to see if we can pick up something more concrete," Dr. Williams said. ■

Ob.Gyn. News

THE LEADER
IN NEWS
AND
MEETING
COVERAGE

#1

Thanks For
Making Us

Source: Kantar Media, Focus® Medical/Surgical December 2009 Readership Summary; Obstetrics and Gynecology Section, Office-Based, Table 127 Projected Average Issue Readers