

Pre-Op Breast MRI May Aid Cancer Management

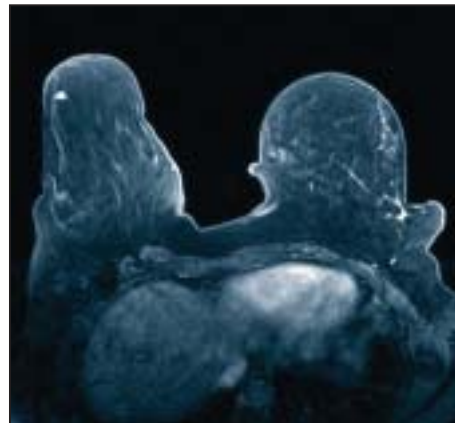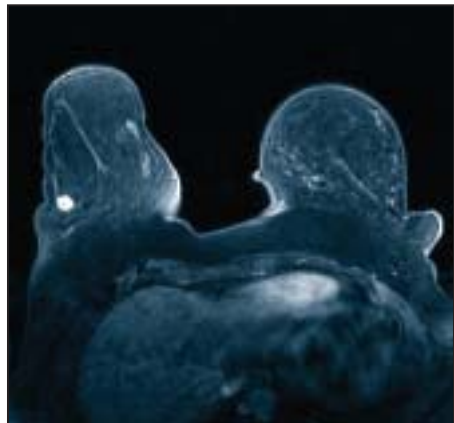
BY JEFF EVANS
Senior Writer

HOT SPRINGS, VA. — Routine use of bilateral breast MRI before surgery may change the management of nearly 20% of candidates for breast conservation, lowering reexcision rates to achieve clear surgical margins, according to a retrospective study.

The ability to perform MRI-directed biopsies is a “critical component” of a pro-

In all, breast-conserving therapy was possible for 60 of the 79 patients. Of 61 lumpectomies performed in those 60 patients, 6 patients (10%) required reexcision for close or positive margins. These results compare favorably with other series, Dr. Cance said.

Receipt of an MRI did not significantly delay treatment. A median of 2 days passed between the initial surgical consult and the receipt of a bilateral breast MRI, while a median of 8 days occurred be-



PHOTOS COURTESY DR. STEPHEN R. GROBMYER

Bilateral MRI in a patient with multicentric breast cancer detected a primary lesion (left, in white) that was also found by mammography; MRI detected another invasive lesion (right) that was not revealed by mammography.

gram that uses preoperative MRI to locate breast cancer lesions, said Dr. William G. Cance at the annual meeting of the Southern Surgical Association.

Dr. Cance and his coauthors evaluated the ability of preoperative MRI scans to improve the selection of candidates for breast-conserving therapy, plan multimodality treatments more precisely, and improve cancer-related outcomes by identifying occult sites of disease at an earlier stage.

They reviewed a series of 79 consecutive candidates for breast conservation who underwent preoperative MRI scanning. The median age of the women was 57 years. Each patient received a physical exam, mammogram, ultrasound, and MRI during an 18-month period in 2006-2007, said Dr. Cance, chairman of the surgery department at the University of Florida, Gainesville.

Patients who had lesions that were suspicious for cancer on an MRI and confirmed on an ultrasound had an ultrasound-guided core biopsy. The lesions that were detected by MRI but not by ultrasound were biopsied under MRI guidance.

The results obtained on the initial MRI scan prompted an additional 25 biopsies in 21 patients. Positive results for cancer or ductal carcinoma in situ were detected in 3 of 6 ultrasound-guided biopsies and in 8 of 19 MRI-guided biopsies. Changes in treatment plans were necessary for 15 (19%) of the 79 patients, because of multicentric disease (7 patients), greater extent of the primary tumor (6), or contralateral breast cancer (2).

Breast-conserving therapy was contraindicated in patients with multicentric tumors in multiple quadrants of the breast or solitary tumors that were large relative to breast size.

tween the initial surgical consult and an MRI-directed biopsy.

Dr. Cance speculated that MRI scanning may lower reexcision rates for close or positive margins by improving the selection of patients for neoadjuvant chemotherapy, the selection of patients for partial versus total mastectomy, and the planning of the extent of partial mastectomy.

Patient selection is crucial for the best oncologic outcomes and cosmesis with breast-conserving therapy, he said. But even after efforts are made to characterize the tumor, locate it radiographically, and then excise it with clear surgical margins, “reexcision rates to achieve clear margins still remain high,” he said.

“The only prognostic factor that we as surgeons can affect is margin status,” Dr. V. Suzanne Klimberg of the University of Arkansas, Little Rock, said in a scheduled discussion of the study. “This paper demonstrates that preoperative MRI may help us select out those patients in which we would be unlikely to obtain negative margins.”

Although the investigators did not evaluate the costs of MRI scanning, Dr. Stephen R. Grobmyer, Dr. Cance’s colleague at the University of Florida, suggested that the scans may save money in the long term by decreasing reexcision rates and recurrent disease. MRI scans and MRI-guided biopsies cost about \$1,500 at the University of Florida, according to Dr. Grobmyer.

The MRI-directed biopsy has been shown to improve the accuracy of preoperative staging. It may be used in conjunction with a second-look ultrasound to confirm the extent of the disease seen on MRI or prevent overtreatment in the event of an MRI scan that is negative for disease, said Dr. Cance.

Inflammatory Breast Cancer Gets Its Own Set of NCCN Guidelines

BY FRAN LOWRY
Orlando Bureau

HOLLYWOOD, FLA. — Inflammatory breast cancer, which used to be covered under the National Comprehensive Cancer Network’s recommendations for locally advanced breast cancer, now has separate guidelines of its own.

“Inflammatory breast cancer is a distinct pathologic entity, and it’s about time we formally recognized this,” Dr. Robert W. Carlson said, announcing the new category at the annual conference of the National Comprehensive Cancer Network.

Advocates have long criticized the inclusion of this very aggressive form of breast cancer in a general breast cancer treatment algorithm. “Giving it its own set of guidelines was the right thing to do. We should have done it with or without advocacy criticism,” said Dr. Carlson, professor of medicine at Stanford (California) University and chair of the NCCN breast cancer guidelines committee.

The classic criteria defining inflammatory breast cancer are dermal edema of a third or more of the breast, erythema of a third or more of the breast, and a palpable border to the erythema. These findings are usually, but not always, associated with dermal lymphatic involvement of the tumor, he said.

Historically, inflammatory breast cancer has carried a very unfavorable prognosis, Dr. Carlson said. He added that any cellulitis of the breast that occurs in a nonpregnant, nonlactating woman should be assumed to be inflammatory breast

cancer until a biopsy proves differently.

The new guidelines say initial staging should include a determination of estrogen-receptor (ER), progesterone-receptor (PR), and human epidermal growth factor-receptor 2 (HER2) status; a bilateral diagnostic mammogram; and ultrasound, bone scan, and computed tomography (CT) scan of the chest, abdomen, and pelvis. Once staging is completed, the guidelines suggest treatment with preoperative anthracycline-based chemotherapy with or without a taxane.

HER2 is frequently overexpressed or positive in inflammatory breast cancers. In such cases, trastuzumab (Herceptin) or a trastuzumab-containing regimen should be used, Dr. Carlson said.

If the woman responds to neoadjuvant chemotherapy (“as the vast majority do” said Dr. Carlson), the new guidelines call for a total mastectomy with level one and two axillary dissection plus radiation to the chest wall and supraclavicular regions. Delayed breast reconstruction may also be considered at this time.

After surgery and radiation, the guidelines suggest that chemotherapy be resumed, if it was not completed preoperatively. They also call for endocrine treatment for ER-positive disease. If the tumor is HER2 positive, the guidelines recommend 1 year of trastuzumab.

Dr. Carlson disclosed that he is a consultant to AstraZeneca Pharmaceuticals LP, Genomic Health, and Pfizer Inc., and that he receives grant and research support from AstraZeneca and Genentech Inc.

Meta-Analysis Weighs Aromatase Inhibitors’ Cardiovascular Risks

COLORADO SPRINGS — The cardiovascular disease risk profile of the third-generation aromatase inhibitors is a mixed bag, compared with that of the antiestrogen tamoxifen, Eric L. Ding, Sc.D., reported at a conference of the American Heart Association.

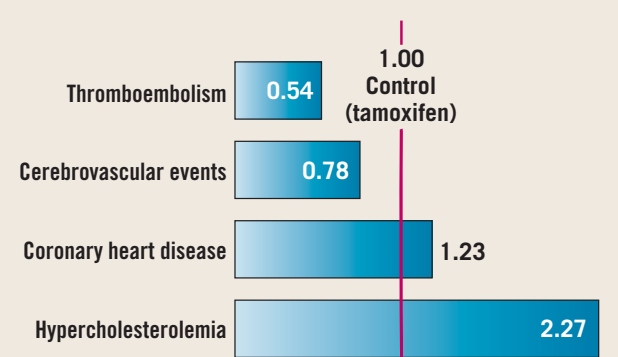
His meta-analysis demonstrated lower risks of thromboembolic and cerebrovascular events with anastrozole and letrozole, compared with tamoxifen, but higher rates of hypercholesterolemia and coronary heart disease (see chart). Anastrozole and letrozole are increasingly replacing tamoxifen for long-term secondary preventive therapy in breast cancer patients.

The meta-analysis included six randomized, tamoxifen-controlled trials of anastrozole and two of letrozole totalling

18,548 postmenopausal breast cancer patients. During follow-up there were 342 coronary events, 237 cerebrovascular events, and 432 cases of thromboembolism, said Dr. Ding of Harvard School of Public Health, Boston. Neither AI was tied to a significant rise in CHD or stroke in placebo-controlled studies, he noted.

—Bruce Jancin

Relative Risk for Cardiovascular Outcomes In Women on Aromatase Inhibitors



Note: Based on data from six randomized studies of 18,548 postmenopausal breast cancer patients.
Source: Dr. Ding