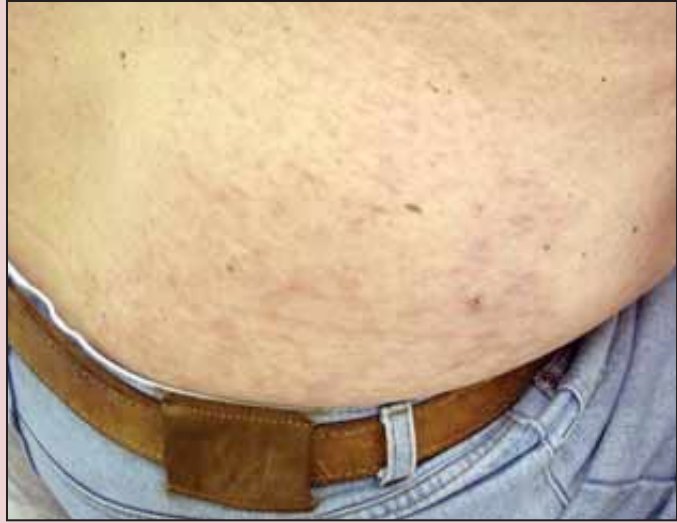

DERM DX

A 71-year-old white man with a history of skin cancer and hyperlipidemia presented with papules on his right knee and left anterior thigh and a patch of erythema and scaling on his left calf. Some improvement followed 3 weeks of triamcinolone 0.1% cream, but on reexamination he had dramatic livedo reticularis on his lower extremities as well as diffuse pink papules on background livedo of the lower trunk. He had noticed increasing fatigue, but otherwise felt well. What's your diagnosis?



A biopsy showed a superficial and deep, perivascular, atypical mononuclear cell infiltrate with CD68, CD43, and myeloperoxidase positivity. A complete blood count revealed leukocytosis with monocytosis and immature granulocytes. A bone marrow biopsy showed acute myelomonocytic leukemia.

The patient received aggressive multiagent chemotherapy. After a disease-free period of 8 months, he subsequently developed a transient erythematous, macular eruption that prompted a repeat work-up. He was diagnosed with a relapse of his leukemia and is currently undergoing treatments with the monoclonal antibody, gemtuzumab ozogamicin.

"Leukemia cutis occurs in a significant minority of patients who have been previously diagnosed with leukemia or in whom the work-up for systemic illness has already begun," said Adrian Guevara, M.D., who presented this case in a poster session at the annual meeting of the American Academy of Dermatology, "but

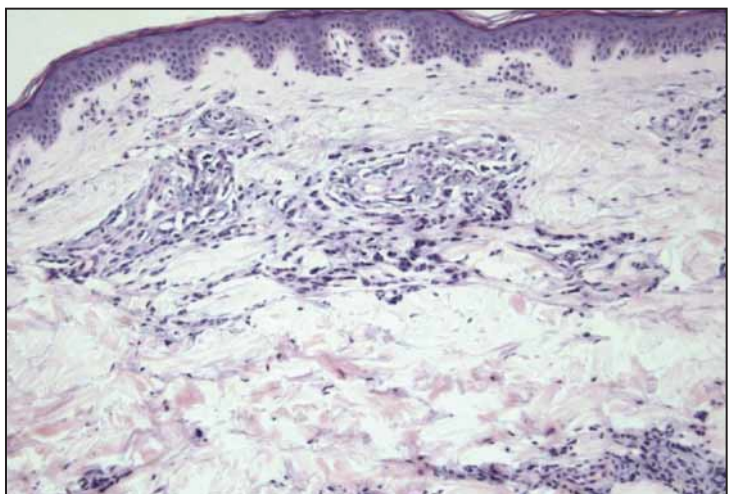
only rarely is it the presenting sign of a myeloproliferative or myelodysplastic state in an otherwise asymptomatic patient."

The lesions are the result of an infiltration of neoplastic cells into the epidermis and dermis; they occur in about 30% of leukemia patients. They most frequently appear as nonspecific, firm or rubbery papules, nodules, or plaques, which can range from flesh-colored to plum-colored. They can masquerade as other skin diseases including erythema nodosum, mycosis fungoides, erythema annulare centrifugum, urticaria, psoriasis, stasis dermatitis, and chilblains, said Dr. Guevara, a resident at the University of Oklahoma, Oklahoma City.

Early biopsy can provide critical information. For this patient, the skin biopsy was the first clue to underlying malignancy.

An early cutaneous manifestation such as this is usually a marker for advanced disease with involvement of other organs including meninges, Dr. Guevara noted.

—Michele G. Sullivan



PHOTOS COURTESY DR. ADRIAN GUEVARA, DR. A. NEIL, DR. R. HENNING, DR. LAWRENCE R. JOHNSON, DR. RAYMOND CORNELLISON

Extracutaneous Melanoma: Look Carefully Near Eyes, Vulva

BY DOUG BRUNK
San Diego Bureau

SAN DIEGO — Only 15% of melanomas are extracutaneous, but you can easily miss these lesions if you don't keep them in mind during routine skin exams, Terence O'Grady, M.D., said at a melanoma update sponsored by the Scripps Clinic.

The most commonly affected sites for extracutaneous melanoma include the ocular or juxta-cutaneous mucosal membranes. (See box.)

"It's easy to miss very small lesions in these places, especially if you don't have really good light in your office," said Dr. O'Grady, a dermatologist with the departments of medicine and pathology at the University of California, San Diego. "You need to take your time to look at least in these areas."

He begins routine skin exams by inspecting the patient's scalp and working his way down to the feet. Starting at the scalp "can be a problem in patients with really

thick hair, but if you pick through the hair like you're looking for nits, you can examine the entire scalp surface," he said. "A lot of times, atypical pigmented lesions are present on the scalp. In fact, it's probably more common to have atypical nevi there than to have common nevi."

Dr. O'Grady also makes it a point to examine the nail beds and the interdigital folds. "These are unusual places to find melanoma lesions, but you can find them," he said. "One thing I always try to do is have the patient take off their shoes and socks so I can look at the bottom of their feet. That's an important part of the exam."

Metastatic melanoma is more common in extracutaneous locations, so if you see a pigmented lesion in one of these sites, "consider it a primary melanoma only if you can rule out all possibility of metastasis," he said. "Sometimes this is difficult or impossible. For example, if a pigmented lesion was removed 10 years ago with no histologic exam, it's going to be hard to prove that this is not a metastasis but is, rather, a primary lesion."

Ocular lesions comprise about 80% of all extracutaneous melanoma. Pigmented lesions of

the eye are the most common. "These will be just like nevi you find in other places, so if you see a nevus on the eyelid, it may be just a nevus and nothing more," he noted. "If you see pigmentation on the conjunctiva or on the sclera, it may be just a normal melanosis, or it could be a junctional nevus, or it could be something more sinister."

Part of his routine skin exam involves folding the eyelids to look into the fornices of the conjunctiva, where pigmented lesions, are almost universally something bad. "Those definitely need to be biopsied." However, Dr. O'Grady added that an ophthalmologist might be referred to because most physicians are not trained to look at ocular lesions.

Another ocular lesion, primary acquired melanosis, can have anything from what looks

like melanoma in situ to something as innocuous as hyperpigmentation. "So it doesn't necessarily have to be melanocytic."

Primary acquired melanosis that involves the limbus is highly

suggestive of malignant melanoma. "What's interesting is that you can also see primary acquired melanosis on the conjunctiva that shows extension of lentigo maligna from eyelid skin," he added.

Poor prognostic indicators of ocular lesions include tumor thickness, pagetoid spread, and involvement of the cornea, episclera, palpebral conjunctiva, or fornix. Sometimes ophthalmologists can successfully treat affected eyes without surgical removal.

The vulva is the next most common site of extracutaneous melanoma, making up about 7% of all cases and typically occurs after menopause, usually discovered late, most commonly on the glabrous skin of the labia minora. Prognosis is grim, with a 5-year survival rate of 47%.

Many cases are amelanotic and resemble discharge or bleeding, "so many of these patients are treated for inflammatory conditions or infectious etiologies before a biopsy is performed," Dr. O'Grady said.

"What's interesting is that some cases have been diagnosed on Pap smear," he said. "They actually get the Pap smear back as melanoma cells." ■

Estimated Frequency

Eye (78.9%)	Gums and mouth (1.2%)
Vulva (7.2%)	GI tract (0.7%)
Soft tissues (2.5%)	Lung, lip, penis, genitourinary tract, nasopharynx (all less than 0.5%)
Anorectum (2.3%)	
Vagina (2.1%)	
Upper respiratory tract (1.6%)	

Source: Dr. O'Grady

Regressed Malignant Melanoma: Tough Dx

BOSTON — Physicians who rely on the histopathologic features of regression could mistake dysplastic nevi for regressed malignant melanoma, Ashraf Hassanein, M.D., reported in a poster presentation at the annual meeting of the American Society of Dermatopathology.

Dr. Hassanein and his associates in the departments of pathology and dermatology at the University of Florida, Gainesville, applied two sets of

criteria that are used to evaluate complete and partial regression in melanoma to 777 shave or punch biopsies of benign and dysplastic melanocytic nevi taken from the backs of patients between 2002-2004.

All subtypes of nevi on the back had evidence of focal regression-like changes. Histopathologic changes that mimicked partial regression occurred with increasing prevalence in 229 junctional dysplastic nevi according to

the degree of cytologic atypia they exhibited: mild atypia (10%); moderate atypia (19%); and severe atypia (39%).

"It may be possible that nevi with regression have been lumped into subtypes of melanoma regression studies in the past, hence, diluting the value of histologic regression as an independent prognostic or predictive variable in recurrence or metastases," Dr. Hassanein suggested.

—Jeff Evans