

IMAGE OF THE MONTH

Patellae that are positioned centrally in the trochlear groove and are not malaligned are thought to be less susceptible to the development of osteoarthritis. Patellae that are chronically poorly aligned can place excess stress on the articular surfaces of the patellofemoral (PF) joints and possibly promote knee degeneration.

Most studies of patellar malalignment have used x-rays of the knee in the lateral plane and skyline view. Few studies have taken advantage of the increased resolution and three-dimensional visualization afforded by magnetic resonance imaging. One reason is that although MRIs of the knee in flexion are more useful in evaluating PF alignment, clinical MRI of the knee is most commonly acquired with the knee extended in the supine position.

Dr. David J. Hunter, a rheumatologist, and his colleagues at Boston University recently compared a number of measures of patellofemoral (PF) malalignment with radiographic indices of osteoarthritis (OA)—the presence of joint space narrowing and osteophytes—in patients with symptomatic and radiographic knee OA (Arthritis Res. Ther. 2007;9:R26).

Study participants were part of the Boston Osteoarthritis of the Knee Study, a cross-sectional larger natural history study of symptomatic knee OA.

“Admittedly, identifying cause from a cross-sectional study is a little bit of a leap, but our belief is that patellar malalignment actually predisposes to these changes,” Dr. Hunter said in an interview.

Not only did the researchers find significant associations between PF malalignment and radiographic features of OA, they demonstrated that indices of patellar alignment can be measured easily on standard knee MRI.

Participants suspected of knee OA underwent a series of x-rays. Those with a definite osteophyte on any view in the symptomatic knee were eligible for the study. The researchers evaluated 213 patients—126 men (average age 68 years) and 87 women (average age 65 years).

MRI studies were performed with a 1.5-T magnet, and a positioning device was used to ensure uniformity of the extended knee position. The imaging protocol included sagittal spin-echo proton density-weighted and T_2 -weighted images and coronal and axial spin-echo fat-suppressed proton density-weighted and T_2 -weighted images.

Use of MRI allowed the researchers to evaluate several indices of patellofemoral alignment. “For some of the measures

that we wanted to take of patellofemoral alignment, we would not be able to get them from radiographic films alone,” said Dr. Hunter, an assistant professor of medicine at Boston University. “The resolution and the different planes that can be acquired on MRI do provide advantages over standard x-ray.”

The researchers measured patellar alignment in the sagittal and transverse (axial) planes. In the sagittal plane, they measured the patellar length ratio (PLR).

To do so, they used the slice with clearly recognizable patellar margins and in which patellar bone volume appeared to be maximal. PLR was calculated as the ratio of patellar length to patellar ligament length. Patellar length was measured from the upper to the lower point of the inner surface of the patella—excluding osteophytes. Patellar ligament length was measured from the lower inner point of the patella to the highest point of the tibial tuberosity.

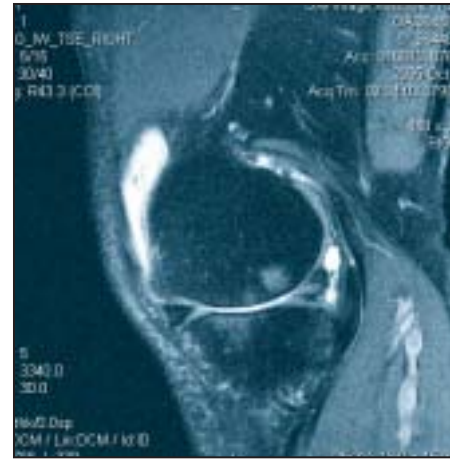
In the transverse plane, the researchers measured the trochlear depth (trochlear sulcus angle) and two indices describing patellar position (lateral patellar tilt angle and bisect offset of the patella). Sulcus angle (SA) is an indicator of femoral trochlear dysplasia, which is associated with PF OA and patellar instability. To measure SA, the researchers used the axial slice that referred to the proximal one-third of the femoral trochlear curve.

SA is the angle between two lines: one radiating from the lowest point of the trochlear sulcus along the lateral bony margin and the other from the lowest point of the trochlear sulcus along the medial bony margin.

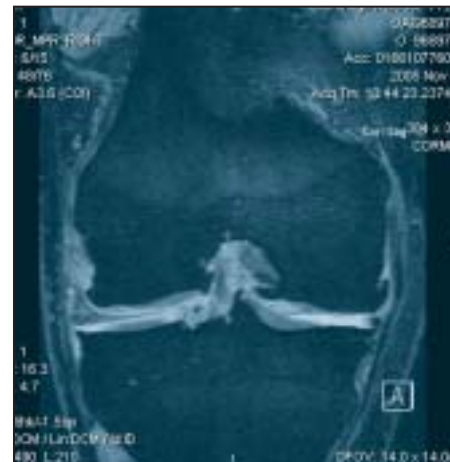For measurements of patellar alignment, the researchers used the axial slice that refers to the middle of the patella. The LPTA, which is the angle between the posterior condylar line and a line through the lateral interior bony margin of the patella, shows the angle of patellar inclination, which indicates the tightness or laxity of the lateral stabilizing mechanism of the patella.

Bisect offset (BO) indicates the lateral displacement of the patella in relation to the deepest part of the femoral sulcus. For the BO of the patella, the researchers used a line perpendicular to the posterior condylar line that runs through the lowest point of the femoral sulcus and up through the patella.

They then measured the distance between this line and the lateral border of the patella (a). They also measured the distance between this line and the medial border of the patella (b). BO was calculated as the formula: $100a/(a + b)$.



Cartilage loss and bone marrow lesions are shown on sagittal image of the knee.

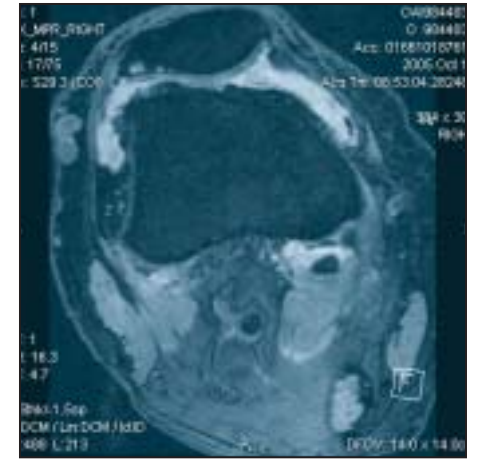


Cartilage loss with macerated remnants of medial meniscus on coronal image.

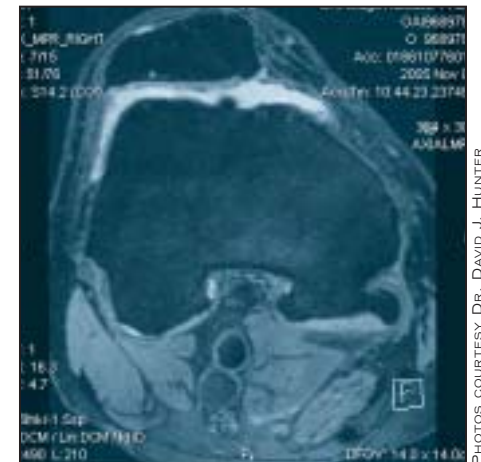
Participants had weight-bearing skyline radiography, and the x-rays were read by a rheumatologist who used a four-point scale to grade the presence of osteophytes in the medial and lateral parts of the patella and femur and the joint space narrowing in the medial and lateral parts of the PF joint.

There was a statistically significant association between PLR and both osteophytes and joint space narrowing in the lateral compartment. With increasing PLR, there was an increased risk of lateral joint space narrowing. A similar trend was found between increasing PLR and increasing lateral patellar osteophytosis. There was no significant association between PLR and indices of radiographic PF OA in the medial PF compartment.

SA showed a statistically significant association with medial joint space narrowing and lateral and medial patellar osteophytosis—with increasing SA, there was increased risk of medial joint space narrowing. LPTA showed a statistically significant association with joint space narrowing and osteophytosis of the lateral PF compartment. A more laterally displaced



Moderate effusion and medial and lateral patella osteophytes as seen on axial view.



Effusion, lateral patella osteophyte, and lateral patella displacement are seen.

patella was positively associated with increased lateral joint space narrowing and also with lateral patellar osteophytosis. In contrast, lateral patella displacement was negatively associated with medial joint space narrowing—increased medial displacement of the patella was associated with medial joint space narrowing.

The findings suggest that alignment of the patella may be an important factor influencing PF joint degeneration, due to the aberrant distribution of forces with activity. “I think that the important message for clinicians here is that to date, the majority of people really haven’t considered problems of malalignment of the patellofemoral joint as important features in patellofemoral osteoarthritis. This study suggests that they’re strongly associated,” said Dr. Hunter.

The fact that MRI was performed with the knee placed in a supine position likely means that the findings from this analysis are conservative for measures that could potentially change with weight bearing (LPTA and BO).

—Kerri Wachter

Careful Patient Selection Improves Knee Arthroplasty Results

BY KERRI WACHTER
Senior Writer

SNOWMASS, COLO. — Unicompartamental knee and total knee arthroplasties provide good results in carefully selected patients, said Dr. Thomas S. Thornhill, chairman of orthopedic surgery at Brigham and Women’s Hospital in Boston, at a symposium sponsored by the American College of Rheumatology.

UKA is indicated for degenerative arthritis in patients who are not good candidates for osteotomy or total knee replacement regardless of age. UKA might be the first option to consider in a younger patient because “it’s much easier to convert a [UKA] to a total [knee arthroplasty] than a total to another total,” he said.

He estimates that the revision rate for UKAs at his facility is about 1% per year. Most problems are related to wear and

progression of disease in the lateral compartment. UKA can be performed with a small incision, involves a shorter hospital stay, lower cost, and more rapid rehabilitation than does a total knee replacement.

In their defense, TKA procedures that are cruciate sparing have good to excellent results at 10-15 years. The major problems with failure of TKA still are related to wear, loosening, and infection. “I would submit to you that most of these failures

can be attributed to technical issues and patient selection,” said Dr. Thornhill.

The most common cause of failure is instability. Surgeons think they need to put the knee in loosely so it will bend and flex better. Instead the looseness creates shearing when the knee moves, he said.

Dr. Thornhill disclosed that he receives royalties from DePuy Inc. He also has received research grants from DePuy Inc., Biomet Inc., and Smith & Nephew. ■