

MR Image Atlas Maps Out Rheumatoid Arthritis Pathology

BY KERRI WACHTER
Senior Writer

The availability of a newly released set of standard magnetic resonance reference images may usher in even greater use of the technology in the evaluation of patients with rheumatoid arthritis.

The European League Against Rheumatism—Outcome Measures in Rheumatoid Arthritis Clinical Trials (EULAR-OMERACT) MRI reference image atlas published last month is intended to improve the performance and generalizability of the MRI scoring system previously developed by the group (*Ann. Rheum. Dis.* 2005;64 [suppl. 1]:i1-155). In 2002, OMERACT released the Rheumatoid Arthritis MRI Score (RAMRIS) for the evaluation of inflammatory and destructive changes in RA hands and wrists.

Intended for clinical researchers, but also translatable as an educational tool for practicing physicians, the atlas is composed of 1,002 representative images of synovitis, bone erosion, and edema in the metacarpophalangeal and wrist joints.

Selection of the images was decided by consensus among six readers from MRI centers in Auckland, New Zealand; Copenhagen; Leeds, Eng-

land; and Sydney, Australia. After the initial selection phase, all images were then reviewed to confirm the feature and grade allocated on scoring.

The document displays all severity grades of synovitis in the metacarpophalangeal joints and in each of the wrist joint areas. In addition, it maps out various severity grades of bone erosion and edema in the metacarpal head and phalangeal base and in five selected wrist joint bones (distal radius, scaphoid, lunate, capitate, and metacarpal base). For each individual grade, the atlas includes examples of both the “low” and “high” ends of the spectrum.

The collection of reference images provides a much-needed visual touchstone for MR assessment of RA, said Orrin M. Troum, M.D., of the University of Southern California, Los Angeles. “This is a positive step forward for rheumatologists. ... I think ultimately we may be able to do away with x-ray.”

A number of studies have demonstrated the superior sensitivity of MRI compared with conventional radiography, particularly in identifying early disease, which is crucial to improving outcomes for patients with aggressive disease. MRI has been shown to be two to nine times more sensitive than x-rays for the detection of bone erosion.

“It’s been well documented that people with RA, if identified and treated earlier, do better,” said Dr. Troum. MRI can make all the difference in the patient with aggressive RA because erosions can be visualized earlier, allowing treatment to be initiated and disease progression to be halted, which all leads to less disability later.

The advent of structure-modifying therapies gave rise to the necessity of MRI assessment in RA patients, said Charles Peterfy, M.D., a musculoskeletal radiologist and a coauthor of the atlas.

Before biologics, there was no real need to have such detailed information about joint structure because having it didn’t alter the course of clinical management. The availability of agents that halt disease progression changed everything, he said.

The challenge now is to identify those patients who will go on to develop aggressive disease before severe impairment sets in.

It’s estimated that “20%-40% of patients with early disease aren’t going to progress,” said Dr. Peterfy, who also is chief medical officer of Synarc, a San Francisco-based company that does MR imaging for clinical trials. Treating these patients empirically with biologics would be much too expensive and would entail an unacceptable level of unnecessary toxicity.

MRI can help identify those with aggressive disease because the technique allows direct visualization and assessment of synovitis and bone edema, which is a probable precursor of bone erosion.

“In early disease, MR identifies the aggressive phenotype much more sensitively than x-ray or any other test does so far,” Dr. Peterfy said.

The MRI atlas may help rheumatologists monitor treatment, adjust dosages, or change treatment regimens altogether. “That’s the way I could see MR being used in the clinic,” Dr. Peterfy said. ■

Core Set of Basic MRI Sequences

It is suggested that future MRI studies that intend to assess inflammatory as well as destructive changes in rheumatoid arthritis joints should include the following:

- ▶ Imaging in two planes* with T1 weighted images before and after intravenous gadolinium contrast.**
- ▶ A T2 weighted fat saturated sequence or, if the latter is not available, a STIR (short tau inversion recovery) sequence.

*Can be acquired by obtaining a two-dimensional sequence in two planes, or a three-dimensional sequence with isometric voxels in one plane allowing reconstruction in other planes.

**Intravenous gadolinium injection is probably not essential if only destructive changes (bone erosions) are considered important.

Source: *Ann. Rheum. Dis.* 2005;64 (suppl. 1):i8-10

Lyme Disease’s Rare Presentation May Not Be

SNOWMASS, COLO. — Lyme disease patients without erythema migrans were thought to be rare—until they showed up more frequently than expected in a large trial of the Lyme disease vaccine, Linda K. Bockenstedt, M.D., said at a symposium sponsored by the American College of Rheumatology.

In that trial, 269 cases of Lyme disease were detected by serum assay, of which 42, or about 16%, involved patients without erythema migrans. However, those patients did have flulike symptoms, such as malaise, fever, myalgia, migratory arthralgias, occipital headache, and neck stiffness. They did not have any upper respiratory symptoms, such as cough.

Additionally, Dr. Bockenstedt of the rheumatology sec-

tion at Yale University (New Haven) noted that there may soon be a way to monitor Lyme disease treatment.

A new enzyme-linked immunoabsorbent assay for Lyme disease, the C6 ELISA (Immunitics Inc.), tests for a single small peptide expressed by the *Borrelia burgdorferi* spirochete during active infection, instead of the whole organism. Research has shown that antibody titers to this antigen drop fourfold when an infected individual has been successfully treated. Dr. Bockenstedt added that forthcoming study results will confirm the ability of the assay to adequately detect a drop in the antigen level.

DR. BOCKENSTEDT

—Timothy F. Kirn



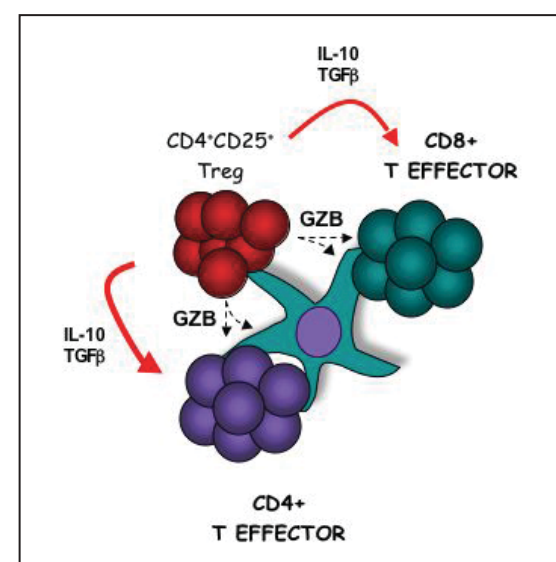
Next Biologics Will Harness Regulatory T Cells

BY TIMOTHY F. KIRN
Sacramento Bureau

SNOWMASS, COLO. — The next generation of biological agents will be therapies that capitalize on the ability of regulatory T cells to keep the immune system in check, Randy Noelle, Ph.D., predicted at a symposium sponsored by the American College of Rheumatology.

First discovered 30 years ago, regulatory T-cell research was largely sidelined until interest in the field was renewed about 5 years ago, said Dr. Noelle, a professor of immunology at the Dartmouth-Hitchcock Medical Center, Lebanon, N.H.

“Over the past year, effective strategies have been developed to grow human regulatory T cells in vitro, and I would imagine that within a year you



Regulatory T cells suppress the functions of both CD4+ and CD8+ T cells.

will see groups growing human regulatory T cells for reinfusion into patients for indications such as graft-versus-host disease,” he said.

“They will be the next wave of cell-based therapy that you will use to manage autoimmune disease,” Dr. Noelle told the audience of rheumatologists.

Regulatory T cells are the mechanism by which the body puts the brakes on the immune system functions of attack cells, or executor T cells, Dr. Noelle explained. Both regulatory T cells and executor T cells arise from CD4-positive cells. Research published last fall suggests that expression of the *Lag-3* gene in CD4 cells differentiates them into regulatory T cells, which then limit the intensity of the autoimmune response (*Immunity* 2004;21:503-13).

Regulatory T cells represent about 5%-12% of an individual’s CD4-positive T-cell population,

Although it is not known whether regulatory T cells suppress autoimmune activity directly or through cytokine expression, they have been shown to infiltrate tumors and attenuate the immune system response to them.

It has also been shown in mice that if mature, naive effector T cells are infused into immune-deficient mice, they develop inflammatory bowel disease. However, if regulatory T cells are infused at the same time, the mice remain healthy, Dr. Noelle said.

In addition, studies have demonstrated that T cells can prevent allergy and affect graft acceptance.

“I think they will have a resounding impact on our understanding of the development and pathogenesis of autoimmune diseases,” Dr. Noelle said. ■