

# Registry Shows Mortality Benefit With DES for MI

BY BRUCE JANCIN  
Denver Bureau

CHICAGO — Two-year mortality was significantly lower with drug-eluting stents than with bare metal stents in a registry including every patient in Massachusetts who underwent percutaneous coronary intervention with stenting for acute MI during an 18-month period.

“Although our aim was to detect whether there was any signal of harm, we actually observed lower mortality at 2 years in patients treated with drug-eluting stents,” Dr. Laura Mauri reported at the annual meeting of the American College of Cardiology.

The study was undertaken because the use of drug-eluting stents (DES) in acute MI is fraught with controversy. The trials that led to marketing approval of DES excluded patients with MI. Subsequent randomized trials looking at DES in MI have been small and a year or less in duration. There has been widespread concern that late events—especially late stent thrombosis—might offset the early therapeutic advantages of DES.

The Massachusetts registry is well suited to shed light on the controversy as it is the largest in the United States, with longer follow-up than in any of the ran-



**The 2-year mortality rate was 9.0% in patients who received a DES and 14.0% in those who got BMS.**

DR. MAURI

14.0% in those who got bare metal stents (BMS).

Because of selection bias—patients with more severe comorbidities were more likely to get BMS, while those with more complex coronary lesions tended to get DES—the investigators performed an analysis involving 2,629 pairs of stent-treated MI patients matched for clinical risk, hospital characteristics, and other factors. The 2-year risk-adjusted mortality rate was 10.6% in the DES recipients and 13.4% with BMS in the overall acute MI population, and 8.0% versus 11.7% for those with ST-segment elevation MI (STEMI). The target vessel revascularization

rate was also significantly lower in the DES group, at 15.5%, compared with 20.8% with BMS.

Importantly, there was no evidence of a late increase in adverse events in the DES-treated patients out to 2 years. The Massachusetts cohort will be followed longer term in future reports, according to Dr. Mauri.

Discussant Dr. Bruce R. Brodie said his own involvement in a smaller registry of stenting for MI has convinced him there is an inherent selection bias that just can't be eliminated by statistical adjustments. He cited as an example an increased likelihood of poor compliance with dual-antiplatelet therapy and other key medications among BMS recipients.

“Should we be putting in drug-eluting stents in most non-STEMI and STEMI patients? I don't think we're quite ready to make that jump,” declared Dr. Brodie of Moses H. Cone Memorial Hospital, Greensboro, N.C.

He said he is particularly concerned about the potential for late stent thrombosis with DES beyond the 2-year mark caused by stent malapposition. STEMI patients are inherently among the highest-risk groups for stent thrombosis because of a tendency for stents to be undersized and underdeployed because of vasoconstriction and thrombus burden. In one study, the late malapposition rate was 25% with DES versus 5% with BMS, he noted.

Dr. William D. Knopf, chief operating officer at Atlanta's Piedmont Heart Institute, called the Massachusetts data “very encouraging” and predicted a resultant increase in the use of DES in MI. ■

## Nickel Reaction Eyed For In-Stent Stenosis

KYOTO, JAPAN — Contact sensitivity to nickel may play an etiologic role in a subset of cases of in-stent restenosis involving bare metal coronary stents.

A positive reaction to nickel was documented in 10 of 78 patients who underwent patch testing to a series of metals, as well as clinically driven quantitative coronary angiography, a median of 9 months after placement of one or more bare metal stents, according to Dr. Golar Honari.

The patch test–positive group had a “modestly” but nonetheless significantly greater lumen loss in the stented segment than did the patch test–negative patients. The mean lumen loss in the 13 stented segments placed in nickel-sensitive patients was 1.1 mm, compared with 0.69 mm in 100 stented segments in patients who had negative reactions, Dr. Honari of the Cleveland Clinic Foundation reported at an international investigative dermatology meeting.

The association between lumen loss and a positive patch test to nickel remained significant in a multivariate linear regression analysis controlling for known risk factors for in-stent restenosis, including diabetes, smoking, and stent length.

Other metals included in the patch test series were chromium, cobalt, molybdenum, and manganese, all of which are commonly used in stents and other cardiovascular devices. No significant associations were found between lumen loss or other angiographic end points and positive reactions to these other metals.

The hypothesis is that contact sensitivity to the nickel present in a bare metal stent may increase the endovascular inflammatory response to the device, resulting in an increased risk of in-stent restenosis. Further investigation is warranted before researchers draw any definitive conclusions, Dr. Honari said at the meeting of the European Society for Dermatological Research, the Japanese Society for Investigative Dermatology, and the Society for Investigative Dermatology.

—Bruce Jancin

## Staples Help Refine Endovascular AAA Repair

BY DOUG BRUNK  
San Diego Bureau

SAN DIEGO — A new technology platform for treating abdominal aortic aneurysms that mimics a hand-sewn anastomosis appears safe and effective, results from a phase I multicenter trial showed.

The Aptus Endovascular AAA Repair System (Aptus Endosystems Inc.) is a three-piece modular device with an unsupported main body and two fully supported limbs in a 5.3-mm outside diameter (16 Fr) delivery system.

“This system represents a new endovascular capability: the ability to attach one object to another with a device independent of the objects being attached,” Dr. David H. Deaton reported at the Vascular Annual Meeting. “In our minds it's a faithful reproduction of transmural, interrupted suture and it gives the operator a new level of control.”

With this technology, helical staples with a 4-mm depth are delivered through an independent stapling system. The location and number of staples are controlled by the operator and provide for endograft fixation and sealing that can be customized to the anatomical challenges of each patient.

“This helical incorporation of tissue holds both graft to aorta and aorta to graft, which has the potential to eliminate neck dilation,” said Dr. Deaton, chief of endovascular surgery at Georgetown University Hospital, Washington, and one of the study investigators.

In a study conducted at five centers in the United States, Dr. Deaton and his associates enrolled 21 patients with a proximal aortic neck length of 12 mm and an iliac landing zone of 10 mm. He reported on 6-month safety and feasibility data in all patients and 1-year follow-up in 14 patients. Secondary end points included freedom from endoleaks, rupture, migration, and device integrity. The mean age of patients was 75 years and 95% were men. The mean diameter of their aneurysms was 56 mm.

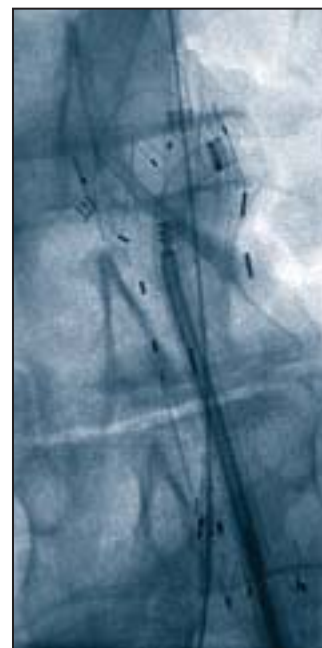
Dr. Deaton reported that the endograft was successfully deployed with the Aptus system in all patients without conversion. A median of 4 staples per patient was used, with a range of 2-10. Significant reduction of aneurysm size occurred in 43% of the patients at

6 months and 69% of patients at 1 year. No aneurysm enlargement was seen during either time period.

Two proximal cuffs and one limb extension were used as adjunctive devices at implantation, and three secondary interventions were performed in two patients for limb thrombosis. There were four type II endoleaks at 6 months and one type II endoleak at 1 year, but there were no type I, II, or IV endoleaks. There were no adverse events, device integrity failures, or migration.

“One of the real benefits of an independent fixation system is [that it allows] a significant reduction in the caliber of graft delivery catheters,” Dr. Deaton said. “It also allows you to reposition the proximal stent without an advanced delivery catheter.”

Dr. Deaton is a consultant to Aptus Endosystems Inc. and serves on the company's advisory board. ■



**A completed staple is shown on the right lateral border of the proximal sealing stent. The stapler was advanced up the EndoGuide (center).**



**The completed endograft has four transmural staples and two modular limbs that are deployed and locked into the main body.**

PHOTOS COURTESY DR. DAVID H. DEATON