

## IMAGE OF THE MONTH

Optical coherence tomography is a technique that has been used to measure the thickness of the retinal nerve fiber layer and macular volume in glaucoma and other retinal diseases. These measurements provide information about the thickness of axons that emanate from the retinal ganglion cell bodies, which coalesce in the optic nerve.

Optical coherence tomography (OCT) uses infrared (IR) light to measure the thickness of the nerves in the back of the retina. The light is bounced off the retina; the way it is reflected back to a recorder at a particular point is used to develop images of the thickness of layers of the tissue at the back of the eye.

This is similar to the way ultrasound works. "It's light-based instead of sound-based," said Dr. Peter Calabresi, director of the Multiple Sclerosis Center at Johns Hopkins University, Baltimore.

The depth of penetrance for the IR light is fairly shallow, which makes it a good technique for looking at structures and tissues right below the surface. With the latest generation of instruments, resolution is down to about 3-4 micrometers, which provides "almost a microscopic picture of the eye," said Dr. Calabresi.

Dr. Calabresi and his colleagues have been using OCT to assess disease status in patients with multiple sclerosis. Because the retinal nerves coalesce into the optic

nerve, "We know with MS that if you injure nerves in one location, that you will see downstream consequences." Neurologists have long looked at the optic nerve head to see if it looks pale in color to determine whether the patient may have had an optic neuritis attack that led to some injury of the nerves at the back of the eye.

The retinal nerve fiber layer (RNFL) has been described as atrophying in focal/segmental patterns after an optic neuritis attack, which suggests that there were small areas of injury rather than a diffuse global process. OCT allows researchers to quantify these focal/segmental patterns of atrophy in the retinal nerve fiber layer. "This just allows us now to quantify it and to have a reproducible and reliable objective measure."

In one study published by Dr. Calabresi and his colleagues, they compared OCT findings of the RNFL between a large cohort of MS patients and a group of healthy controls (Neurology 2007;69:2085-92). In this study, patients with MS had abnormal RNFL findings, even if they didn't have a history of optic neuritis. OCT "could then be used as a diagnostic tool to then pick up subclinical disease," Dr. Calabresi said.

In another study, the researchers were able to show that changes in the RNFL were correlated with global

brain atrophy in MS patients (Neurology 2007;69:1603-9). "By looking at this one part of the nervous system, it may be predictive of what's happening in the rest of the brain," Dr. Calabresi said.

In the third study, they showed that the technique provides intrarater and inter-rater reproducibility (Arch. Neurol. 2008;65:1218-22), which is important because MS patients produce unique challenges for OCT. "Although other people have reported this in the ophthalmology world, we thought it was important to show [that] you could do this in a neurology office with MS patients," he said. "I think it was important to show that in a patient with a more diffuse global disease, that we could get them to hold still enough to do the testing."

There are a few caveats about OCT to consider. "The abnormalities that we look at on OCT are not specific to MS. It's very important to rule out glaucoma and other retinal processes related to hypertension or diabetes," Dr. Calabresi said. Once a neurologist is fairly certain that the retinal abnormalities are related to MS, "it's a very useful way of tracking the disease," said Dr. Calabresi.

OCT has some advantages over MRI—it's an office-based technique that takes about 10 minutes to perform and is much

cheaper and more user-friendly than MRI. Despite this, OCT will not likely take the place of brain imaging. Dr. Calabresi sees OCT as useful in partnership with MRI.

"I imagine using it frequently in the office when the patient is coming in for a visit to directly assess the eyes and to give you some information

about the status of the retinal nerves.

"We know the progressive cases tend to have more [RNFL] damage and we know that it is somewhat predictive of what is happening in the brain."

The technique could be used in the period between brain imaging scans to assess progression.

As yet, there are no longitudinal data on the use of OCT to track progression, said Dr. Calabresi.

"What everyone wants to know is how quickly does this measurement change?" In the studies to date, patients have had their disease for about 8-10 years, and there is only about a 10-micrometer difference in RNFL thickness between MS patients and controls.

If RNFL thickness changes at a steady rate, this translates to about a micrometer per year—which falls within the margin of error. However, longitudinal data may show periods of more rapid progression and periods of relative stability, said Dr. Calabresi.

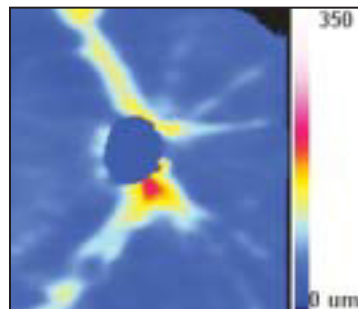
"What we're finding in OCT is that over a 2-year period, 10%-15% of people have stepwise declines of up to 10 micrometers ... It's not that everyone is just losing a little bit. Some people will have subclinical attacks and not necessarily even know that they had an optic neuritis episode."

Dr. Calabresi and his colleagues are currently working on a longitudinal study of about 1,000 patients that they've been tracking. The results are expected in the next year.

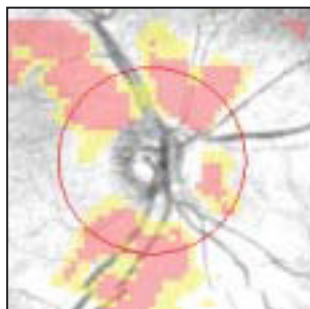
OCT is already showing promise in the clinical trial setting, where it could be used at frequent intervals to track the effectiveness of a drug on halting MS progression. The technique is being used in optic neuritis drug trials, and several companies are interested in using OCT as an assessment tool in MS trials.

Dr. Calabresi reported that he does not have any relevant conflicts of interest.

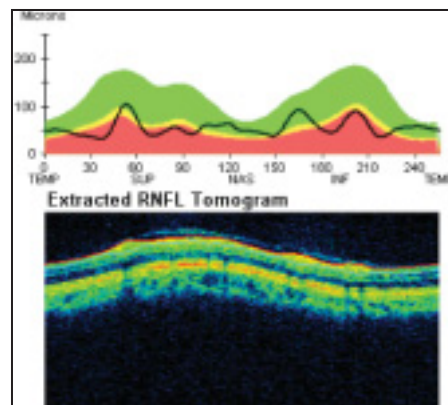
—Kerri Wachter



RNFL thickness map shows the right eye of an MS patient.



Areas of Red and yellow show areas of abnormality.



RNFL thickness (black line) for 0-360 degrees in right eye (top): Bottom image is a tomogram of the right eye's RNFL.

IMAGES COURTESY DR. PETER CALABRESI

## MS Patients Respond Well to Blood Stem Cell Transplant

BY MICHELE G. SULLIVAN  
Mid-Atlantic Bureau

MADRID — High-dose immunosuppressive therapy with autologous hematopoietic stem cell transplant may be a promising new treatment option for multiple sclerosis, based on results that were obtained in a series of 56 Russian patients.

The treatment combination improved or stabilized the condition in 92% of the patients and resulted in long-term, progression-free survival in 83%, lead investigator Dr. Yury Shevchenko reported at the annual congress of the European Federation of Neurological Societies.

He presented full data for 48 patients, all of whom had 6-30 months of follow-up (mean of 19 months).

The patients' mean age was 32 years and their mean disease du-

ration was 7 years. Of the 56 patients, 27 had secondary progressive disease, 10 had primary progressive, 18 had relapsing-remitting disease, and 1 had progressive-relapsing disease. Their mean EDSS (Expanded Disability Status Scale) score was 6.

All patients underwent the BEAM conditioning regimen before surgery. This regimen consisted of high-dose BCNU (carmustine) at 300 mg/m<sup>2</sup> on day 6 before the stem cell transplant; etoposide at 200 mg/m<sup>2</sup>, cytarabine at 200 mg/m<sup>2</sup> from day 5 to day 2 before transplant, and melphalan 140 mg/m<sup>2</sup> on the day before transplant (Exp. Hematol. 2008;36:922-8).

Patients tolerated the conditioning and transplant very well, said Dr. Shevchenko of the Pirogov National Medical Surgical Center, Moscow.

Neutropenic fever occurred in 52%; thrombocytopenia in 50%;

transient increases in liver enzymes in 46%; and enteritis in 18%. There were no transplant-related deaths.

Clinical improvement (defined as a decrease on the EDSS score of at least 0.5 points) occurred in 27 patients, and stabilization occurred in 17 patients, Dr. Shevchenko said. The published study noted that nine patients had "dramatic improvement."

One patient with secondary progressive disease and another patient with relapsing-remitting disease worsened within 6 months of the transplant but then stabilized during follow-up.

MR imaging results were available for 37 patients. Of these, 16 had active lesions at baseline, and all of these became inactive during follow-up. Of the 21 patients without active lesions at baseline, 20 remained inactive and one developed an active lesion.

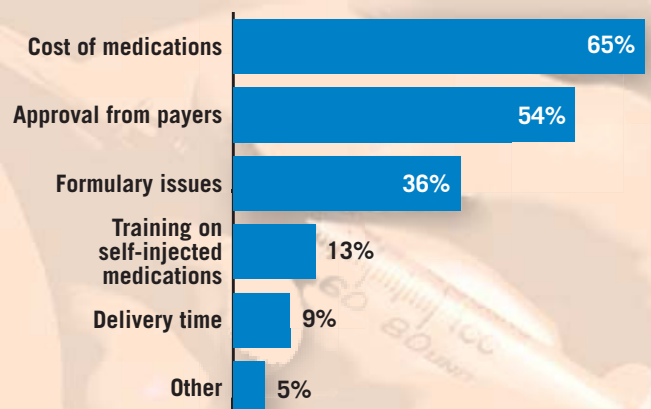
There was one death, the pa-

per noted. This patient, with secondary progressive disease, deteriorated 12 months after transplantation. About 4 years after

the procedure, she developed acute promyelocytic leukemia and died of a cerebral hemorrhage.

### DATA WATCH

#### Most Frequent Complaints About Access to Injectable Drugs for Multiple Sclerosis Patients



Note: Based on a 2006 survey of 101 MS case managers.  
Sources: Teva Neuroscience and National Multiple Sclerosis Society