

## Brief Statement Medtronic ICDs

### Indications

Medtronic implantable cardioverter defibrillators (ICDs) are indicated for ventricular antitachycardia pacing and ventricular defibrillation for automated treatment of life-threatening ventricular arrhythmias.

### Contraindications

Medtronic ICDs are contraindicated in patients whose ventricular tachyarrhythmias may have transient or reversible causes, patients with incessant VT or VF, patients who have a unipolar pacemaker, and patients whose primary disorder is bradyarrhythmia.

### Warnings/Precautions

Changes in a patient's disease and/or medications may alter the efficacy of the device's programmed parameters. Patients should avoid sources of magnetic and electromagnetic radiation to avoid possible underdetection, inappropriate sensing and/or therapy delivery, tissue damage, induction of an arrhythmia, device electrical reset or device damage. Do not place transthoracic defibrillation paddles directly over the device.

### Potential Complications

Potential complications include, but are not limited to, rejection phenomena, erosion through the skin, muscle or nerve stimulation, oversensing, failure to detect and/or terminate tachyarrhythmia episodes, acceleration of ventricular tachycardia, and surgical complications such as hematoma, infection, inflammation, and thrombosis.

See the device manual for detailed information regarding the implant procedure, indications, contraindications, warnings, precautions, and potential complications/adverse events. For further information, please call Medtronic at 1-800-328-2518 and/or consult Medtronic's website at [www.medtronic.com](http://www.medtronic.com).

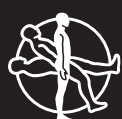**Caution:** Federal law (USA) restricts this device to sale by or on the order of a physician.

### World Headquarters

Medtronic, Inc.  
710 Medtronic Parkway  
Minneapolis, MN 55432-5604  
USA  
Tel: (763) 514-4000  
Fax: (763) 514-4879  
[www.medtronic.com](http://www.medtronic.com)

Medtronic USA, Inc.  
Toll-Free: (800) 328-2518  
(24-hour technical  
support for physicians  
and professionals)

UC200603835 EN  
© Medtronic, Inc. 2007  
All Rights Reserved  
Printed in USA  
January 2007



# Medtronic

# Duplex-Guided Balloon Avoids Dyes, X-Rays

BY BETSY BATES  
Los Angeles Bureau

LAS VEGAS — Duplex-guided balloon angioplasty provides excellent visualization and spares patients exposure to radiation and potential nephrotoxicity from contrast agents, said Dr. Enrico Ascher at the spring meeting of the American College of Surgeons.

Patients with diabetes and those with preexisting renal disease are particularly well served by the duplex approach, said Dr. Ascher, director of the vascular surgery division at Maimonides Medical Center in Brooklyn, N.Y., and professor of surgery at Mt. Sinai Medical Center in New York. However, all patients benefit from the myriad advantages of duplex-guided procedures, including multiplanar imaging and five- to sixfold magnification; the ability to view the entire vessel wall rather than just the lumen; and more precise measurement for, selection of, and placement of stents.

Furthermore, duplex techniques allow two ways of immediately assessing the adequacy of the procedure: visualization of the anatomy and hemodynamic confirmation, he said.

"I'm not here to say x-ray is bad or dye is so bad," Dr. Ascher said. But contrast-induced renal failure occurs in up to 30% of patients with diabetes. Up to 40% of patients with preexisting renal disease have worsening renal failure after balloon angioplasty with dyes, he said.

Protection of physicians and team members also is a consideration when seeking alternatives to x-ray-guided techniques, because radiation injury is cumulative, permanent, somatic, genetic, and gonadal in onset. "When you're ready to retire, you won't be able to see," he said.

Dr. Ascher reported the results of 470 duplex-guided balloon angioplasty procedures that he performed in a 3-year period,

most—360—involving the femoropopliteal segments of the infrainguinal arteries. The rest of the cases involved infrapopliteal arterial occlusion, failing arteriovenous access fistulas and bypass grafts, infrainguinal arterial bypasses, and other indications.

Among the femoropopliteal segment cases, half of patients had diabetes, 37% had chronic renal insufficiency, and 80% had hypertension. Severe claudication was present in 63%; 65% had stenosis, and



**The procedure involves duplex-guided ipsilateral arterial puncture and visualization of the wire tip the whole time.**

DR. ASCHER

35% had occlusion. Most patients met criteria for TransAtlantic Inter-Society Consensus (TASC) class C or D (68% and 10%, respectively), but some were class A and B (5% and 17%, respectively).

Dr. Ascher demonstrated the procedure, which involves duplex-guided ipsilateral arterial puncture and precise visualization of the tip of the wire during the entire procedure, which minimizes bleeding risk. When the wire was not easily manipulable because of multiple branches or during subintimal angioplasty, he was able to confirm, using duplex ultrasound, that it was still inside the true lumen. Stents were placed in any case where residual stenosis was greater than 40%, he said.

Technical success was achieved in 95% of cases, including 229 of 230 patients with stenosis and 104 of 122 with occlusive disease. Clinical improvement was seen in 95% of cases. One patient died of a myocardial infarction.

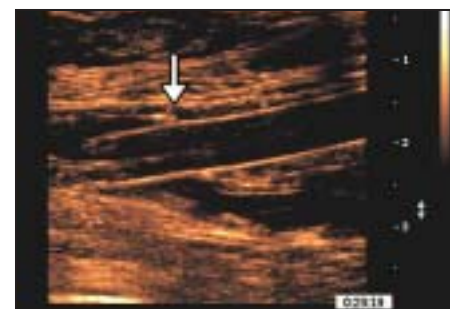
Among 268 patients followed for up to 6 months after angioplasty of lower extremity arteries, 10 thrombosed early (within 30 days).

All of these had TASC lesions rated as class C (6 of 185 such patients) or class D (4 of 26 such patients). A multivariate analysis found that the strongest predictor of early (30-day) and midterm (6-month) arterial thrombosis was popliteal artery volume flow of less than 100 mL/min.

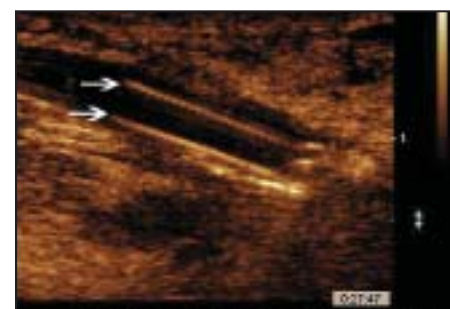Dr. Ascher also described results of 80 duplex-guided balloon angioplasties of the infrapopliteal segment that he performed.

These procedures were usually completed in less than 1 hour. Technical success was achieved in 77 of 80 cases, including 67 of 70 patients with stenosis and 9 of 10 with occlusion.

In another 49 cases, the duplex technique was used to perform infrainguinal bypass for failing grafts. There were 48 technical successes in this group, with 1 perforation by a cutting balloon repaired later by patch angioplasty, and 1 case that could not be completed due to extreme tortuosity. At 6 months, primary patency was achieved in 34 of 49 cases (69%), and all patients' limbs had been salvaged. ■



**B-mode image shows a 6-mm balloon that is fully inflated across the superficial femoral artery origin (arrow).**



**Arrows show a balloon's blades across the severe focal stenosis in the femoral to plantar artery vein bypass graft.**

IMAGES COURTESY DR. ENRICO ASCHER