

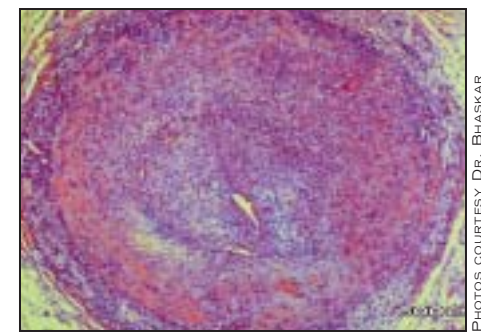
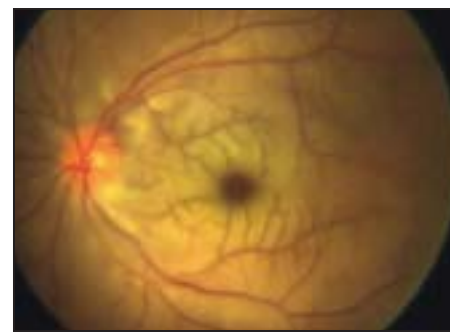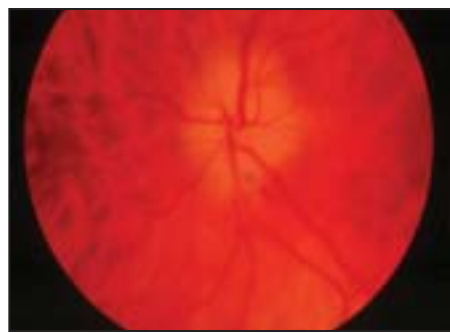
Vision Loss Is Preventable in Giant Cell Arteritis

BY NANCY WALSH
New York Bureau

LIVERPOOL, ENGLAND — Giant cell arteritis is a critical ischemic process and should be considered a preventable stroke in the eye, yet vision loss almost always occurs before treatment is begun, according to Dr. Bhaskar Dasgupta.

Giant cell arteritis (GCA), the most common of the vasculitides, has an incidence of 7-29/100,000 people aged 50 and older in Europe, notably among women. The mean age of onset is 70 years.

GCA predominantly affects the cranial branches of arteries arising from the arch of the aorta, and often coexists with polymyalgia rheumatica (a generalized stiffness and aching of the muscles around the neck and shoulders), said Dr. Dasgupta,



At left: optic neuritis associated with GCA, characterized by a pale disc with diffuse edema, splinter shaped hemorrhages, and optic atrophy. Center: an example of central retinal artery occlusion in GCA. At right: a histology of giant cell arteritis.

who headed a working group of the British Society for Rheumatology that has drafted guidelines for the management of GCA.

While new onset headache and elevated inflammatory markers are typical, GCA does not always present classically—par-

ticularly in patients at highest risk for neuro-ophthalmic complications.

"Pitfalls for the unwary include the fact that GCA does not always present with headache, and we now know that jaw claudication is a cardinal red flag warning of imminent vision loss," Dr. Dasgupta said at the annual meeting of the British Society for Rheumatology.

Immediate institution of high-dose corticosteroids is needed to avoid loss of vision. Biopsy of the temporal artery also should be done, but treatment should not be delayed in the interim.

American College of Rheumatology criteria for GCA include age of onset 50 years or more, new onset headache, temporal artery abnormalities, elevated erythrocyte sedimentation rate, and abnormal artery biopsy. But other features—jaw and tongue claudication, diplopia, and amaurosis fugax—should be considered the "TIAs" of critical ischemia, said Dr. Dasgupta, a consultant rheumatologist at Southend University Hospital, Westcliff (England).

"The concept of symptom-to-thrombolysis time in myocardial infarct and stroke is well established. We believed that 'symptom-to-steroid' time should be adopted as an audit standard in GCA," Dr. Dasgupta said in an interview.

Histologic findings on biopsy of the temporal artery can include mononuclear cell infiltration; granulomatous inflammation, usually with multinucleated giant cells, in-

timial proliferation, and vascular occlusion. The biopsy should preferably be done within a week of starting steroid therapy, but may remain positive for 14-28 days after treatment is initiated. A trial of corticosteroids should not substitute for the biopsy, Dr. Dasgupta said.

The usual starting dose of prednisone 40-60 mg/day should be continued until symptoms and laboratory abnormalities resolve. However, in the setting of evolving vision loss or amaurosis fugax, intravenous methylprednisolone, 500 mg to 1 g daily for 3 days followed by oral prednisone, should be used.

The steroids should not be tapered too quickly—certainly not before 4 weeks, Dr. Dasgupta cautioned. But because GCA tends to follow a chronic relapsing course and long-term corticosteroid therapy in these patients is associated with a high rate of adverse events—in one series nearly half of patients had fractures—various immunosuppressive therapies have been tried. Though methotrexate trials have had conflicting results, the drug was shown in a meta-analysis to have a small effect in preventing relapses, he said. There have also been promising case reports of biologics.

"In my view the timing of treatment is the most important factor. Our approach to GCA today is almost leisurely compared to the modern approach to critical ischemia at other sites such as the myocardium and the brain," Dr. Dasgupta said. ■

Jaw Claudication: An Important Sign

Dr. Dasgupta also presented a poster at the meeting of the case of an 81-year-old woman with a 3-day history of complete vision loss in the right eye and 2 weeks of intermittent blurred vision in the left eye.

She had been seen by her general practitioner 4 weeks earlier with jaw claudication but had no history of headache, scalp tenderness, or polymyalgia rheumatica. She was not referred for exclusion of giant cell arteritis (GCA) or given corticosteroids.

At Southend Hospital, she was unable to perceive light in her right eye and had minimal vision in the left. The right optic disc was swollen and pale and the retinal arteries were attenuated, while there was pallor and blurring of nasal margin of the left optic disc. Both temporal arteries were thickened, wrote Dr. Frances A. Borg, Dr. Dasgupta's colleague. Erythrocyte sedimentation rate was 27 mm/hr and C-reactive

protein (CRP) was 13 mg/L. Temporal artery biopsy confirmed GCA, revealing severe mediointimal proliferation.

She was treated with IV methylprednisolone for 3 days, with vision improvement in the left eye and a fall in CRP to 2 mg/L, but when she was switched to oral prednisone the left-sided vision again deteriorated. Her vision is currently 20/200 in the left eye, and she cannot perceive light in her right.

"This case illustrates the importance of recognizing jaw claudication as a predictor of vision loss in GCA. This patient had none of the other well-recognized features of GCA, and only a modest rise in her inflammatory markers. We suspect that if she had described headache, the diagnosis would have been recognized when she initially presented, and steroid therapy would have been instituted in time to save her vision," Dr. Borg wrote.

Minocycline, Others Cause Spike in Drug-Induced Lupus Cases

BY NANCY WALSH
New York Bureau

NEW YORK — The contemporary use of minocycline for acne and hydralazine for heart failure is expanding the spectrum of drug-induced lupus.

Minocycline-induced lupus was first reported in the early 1990s, and more than 250 cases have now been reported to the World Health Organization. There is a 5:1 female-to-male predominance. Clinical features include fever, morning stiffness, myalgias, polyarthralgias, and symmetric arthritis. It is also characterized by large vessel vasculitis, and in more than 60% of patients, antineutrophil cytoplasmic antibodies are present and antihistone antibodies are not. This is in contrast to "classic" drug-induced lupus, in which antihistone antibodies are prominent.

Other autoantibodies also can be seen in minocycline-induced lupus, including antinuclear antibody (ANA) and anti-double-stranded DNA, said Dr. Andrew G. Franks Jr.

"The likelihood of developing a lupuslike syndrome is elevated 8.5-fold with minocycline, so many clinicians are now moving away from using minocycline for acne and rosacea and switching to doxycycline," said Dr. Franks of

the department of dermatology at New York University Medical Center, New York.

Hydralazine, which had fallen out of favor as an anti-hypertensive, has regained popularity as part of combination therapy for heart failure in African Americans following the benefits seen in the African-American Heart Failure Trial (N. Engl. J. Med. 2004;351:2049-57).

Hydralazine is one of the "big five" causes of classic drug-induced lupus, along with procainamide, isoniazid, quinidine, and phenytoin, but more than 100 drugs have been implicated in the 15,000-20,000 cases reported in the United States annually, he said.

"In my opinion, patients starting hydralazine, or any drug in the big five for that matter, should have a baseline test for ANA, although that is somewhat controversial," Dr. Franks said.

The third main type of drug-induced lupus is subacute cutaneous lupus erythematosus (SCLE), which also is associated with an ever-widening variety of agents, including the thiazide diuretics, antifungals, calcium channel blockers, and ACE inhibitors. There also have been reports involving statins, leflunomide, and tumor necrosis factor inhibitors.

SCLE can be difficult to sort out, with targetoid lesions mixed with papulosquamous or annular lesions. Presentation can also resemble erythema multiforme or toxic epidermal necrolysis, with disadhesion of the epidermal layer and sloughing of the skin. "Patients with this subtype have very high morbidity and mortality," he said.

An audience member asked what happens when the offending drug is withdrawn. "It can sometimes take months for this to remit, and some patients require additional therapy, but 95% of patients ultimately do remit," Dr. Franks said at a rheumatology meeting sponsored by New York University.

Another audience member asked what to do if a patient's baseline ANA is positive, and whether that represents a contraindication to hydralazine therapy, for example. "That is why I said doing a baseline ANA is controversial," Dr. Franks replied. "A number of groups do not suggest doing this, but clearly autoantibodies and a loss of tolerance precede the development of lupus, so one could be prudent and repeat the ANA yearly and see if it turns positive and the titer starts rising," he said.

Dr. Franks reported having no financial relationships to disclose. ■