

# 3-D Ultrasound Reveals 'Tremendous Detail'

BY CARL SHERMAN  
Contributing Writer

NEW YORK — Three-dimensional ultrasound represents an emerging advance in imaging with important applications in obstetrics, Alfred Z. Abuhamad, M.D., said at an obstetrics symposium that was sponsored by Columbia University and New York Presbyterian Hospital.

The ability to rotate images, change planes, and manipulate displays according to signal strength makes it possible to visualize skeletal and vascular structures and fluid spaces, in addition to providing detailed views of fetal appearance, according to Dr. Abuhamad, who is professor and chair of obstetrics and gynecology and the director of the division of maternal-fetal medicine at Eastern Virginia Medical School, Norfolk.

The term "3-D" is something of a misnomer in that the image is displayed on a 2-D monitor.

"[Instead of '3-D'] the term should be volume sonography that gives the appearance of depth," Dr. Abuhamad said.

The volume image is created by the summation of 2-D slices from multiple planes, as the probe is steered from side to side.

The size of the acquired image is determined by the angle across which the probe is moved. Since fetal movement makes the speed of volume acquisition highly important, "we use the smallest angle [needed for evaluation of the structure of interest] in the smallest box," Dr. Abuhamad said.

With a multiplanar display, an image constructed from sagittal, coronal, and transverse planes can be rotated along the x-, y-, and z-axis to visualize the same structure from different angles. To maintain orientation, it is helpful to determine a reference point, and it may be necessary to use 2-D ultrasound to locate key structures.

The surface display shows the external aspects of the

fetus, allowing the same views as in 2-D ultrasound, to review in "tremendous detail" such fetal abnormalities as clefting of the lip and palate, he said during the meeting.

With "maximum mode," which manipulates the signal to enhance light (i.e. echoic) objects and dim dark (anechoic) ones, skeletal structures can be visualized, affording a look at the cranium and its fontanelles and sutures.

It also facilitates assessment of bone quality and detection of fractures and permits close examination of the vertebral column.

"It's like an x-ray of the fetus," Dr. Abuhamad commented.

"Minimum mode" reveals vasculature; while "inversion mode," which dims light structures and highlights dim ones, brings out fluid cavities and makes it possible to visualize such structures as the chambers of the heart and determine the number of gestational sacs, he said.

Other image manipulations permit the clinician to see the back of structures and to remove from the image, as with an "electronic scalpel," structures that may obscure features of interest.

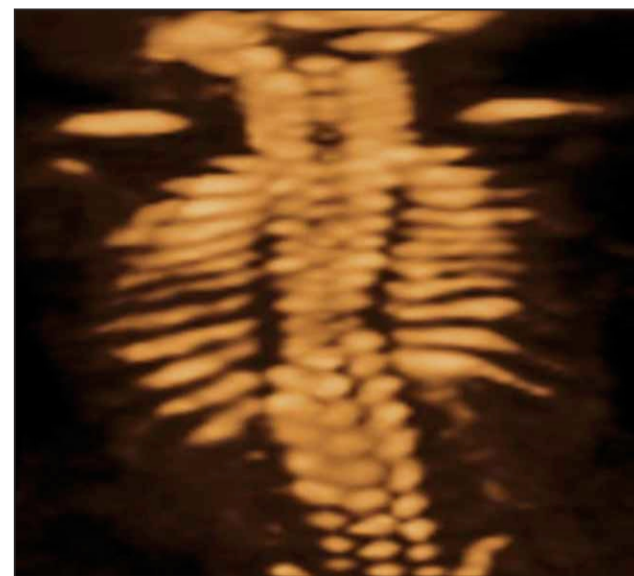
The 3-D procedure does not use more power, increase fetal exposure, or magnify the thermal effect, compared with 2-D ultrasound, he said.

Limitations of the technique include a steep learning curve and the need to dedicate sufficient time for training.

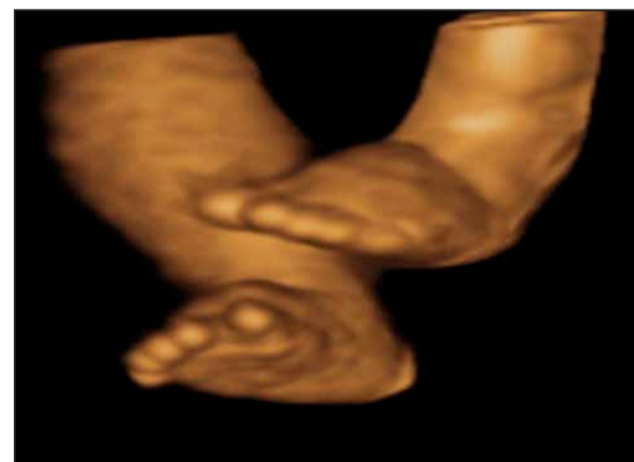The quality of the volume image is limited by 2-D resolution. Artifacts such as motion of the woman or fetus, surface rendering, and shadowing can interfere with interpretation.

The technique is highly operator dependent, and the lack of standardization magnifies the possibility of human error, Dr. Abuhamad said.

An estimated 10% of ultrasound units currently have this technology, he said.



This 3-D image shows an absent T12 rib on one side in a fetus with balanced translocation.



Swelling involving the dorsal aspect of both feet in a fetus with Turner syndrome is shown here on 3D ultrasound.

PHOTOS COURTESY DR. ALFRED Z. ABUHAMAD

## Aggressive Tx Less Cost Effective For Low-Birth-Weight Infants

BY ROBERT FINN  
San Francisco Bureau

RENO, NEV. — From a societal perspective, the most cost-effective course of action for impending preterm delivery at 24 weeks' gestation is an unwillingness on the part of the physician to perform cesarean section, Gianni Cazan-London, M.D., and colleagues reported in a poster presented at the annual meeting of the Society for Maternal-Fetal Medicine.

The researchers, from the University of Michigan Health System in Ann Arbor, conducted a cost-benefit analysis comparing aggressive management (willingness to perform cesarean section) with nonaggressive management (unwillingness to perform cesarean section).

If the overall goal is simply to produce a surviving infant, the choice of management has only a minimal effect on overall costs, with aggressive management costing \$38,434 more than nonaggressive management.

On the other hand, if the goal is to produce a surviving infant who is healthy, aggressive management costs \$690,969 more per healthy survivor than does nonaggressive management.

While aggressive management does slightly improve the chances of producing a healthy

survivor, it also doubles the probability of producing an infant with major and costly morbidity, according to the analysis.

The investigators based their analysis on a comprehensive literature search, which yielded estimates of the probabilities and costs for various options on a decision-tree model.

Costs included neonatal hospitalization, burial for death, and lifetime interventions and/or special education for infants with major disabilities. The investigators expressed the results in 2004 U.S. dollars.

According to the analysis, unwillingness to perform cesarean section would cost \$675,425 per survivor (overall) and \$1,688,562 per healthy survivor.

In contrast, willingness to perform cesarean section would cost \$713,859 per survivor (overall) and \$2,379,531 per healthy survivor.

The investigators noted that emotional and financial costs to parents, health care providers, and society at large are substantial, regardless of the physician's management strategy. They concluded that physicians should strive to provide objective information to the parents whose child is likely to be born with extremely low birth weight. The parents, then, should be allowed to make the ultimate decisions on the aggressiveness of obstetric management. ■

## Children of Preeclamptic Mothers at Risk for Pulmonary Hypertension

SAN DIEGO — Children born to preeclamptic mothers are more likely to have pulmonary hypertension, compared with children born from uncomplicated pregnancies, results from a small study have demonstrated.

The finding provides "the very first evidence that preeclampsia leaves a persistent and potentially fatal imprint in the pulmonary circulation of the offspring, which predisposes them to exaggerated hypoxic pulmonary hypertension in later life," Pierre-Yves Jayet, M.D., reported at a meeting sponsored by the American Physiological Society.

As part of an ongoing collaboration between the University Hospital in Lausanne, Switzerland, the Swiss Cardiovascular Research Institute in Bern, and the Bolivian High Altitude Research Institute in La Paz.

Dr. Jayet and his associates hypothesized that children born to mothers who had preeclampsia are predisposed to pulmonary hypertension at high altitude. To test this hypothesis, the investigators used

echocardiography to measure systolic pulmonary artery pressure in 11 children aged 6-8 years who were born to preeclamptic mothers from La Paz, where the elevation ranges from 12,000 to 13,000 feet above sea level.

For a control group, they evaluated 13 age- and gender-matched children in La Paz born from normal pregnancies, said Dr. Jayet of the department of internal medicine at University Hospital in Lausanne.

The mean systolic pulmonary artery pressure was about 33% higher in children born to preeclamptic mothers, compared with those born from uncomplicated pregnancies (36 mm Hg vs. 27 mm Hg, respectively). Dr. Jayet noted that the hypoxic pulmonary vasoconstriction was not related to more severe hypoxemia or exaggerated polyglobulia.

He said the next step is to study animal models to determine the underlying mechanism of action that causes pulmonary vascular damage in children of preeclamptic mothers.

The Swiss National Science Foundation supported the study.

—Doug Brunk