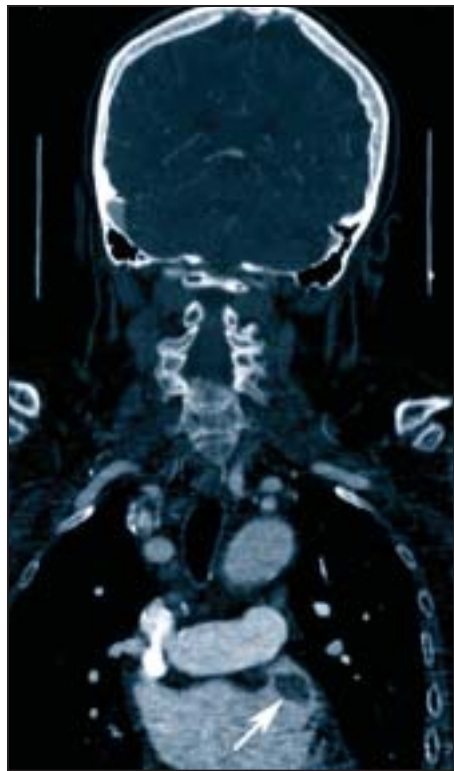


Cardiac CT Imaging Is Key to Stroke Work-Up

BY AMY ROTHMAN SCHONFELD
Contributing Writer

CHICAGO — Up to 20% of strokes begin in the heart, so cardiac imaging should be part of the work-up of many stroke patients, Dr. Gautham Reddy said at the an-



Reconstructed coronal imaging shows a thrombus in the left atrial appendage.

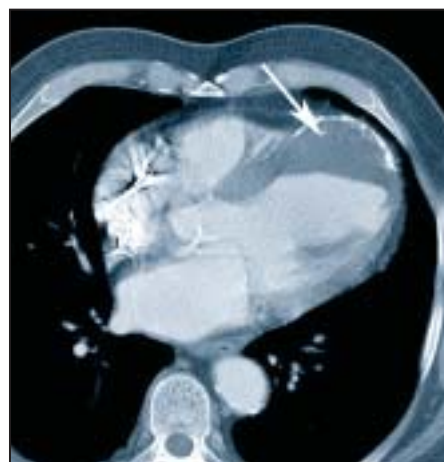
nual meeting of the American Society of Neuroradiology.

Electrocardiographically gated multidetector CT can assess the brain, cerebral vessels, and carotid arteries as well as the heart simultaneously and expedite diagnosis, he said.

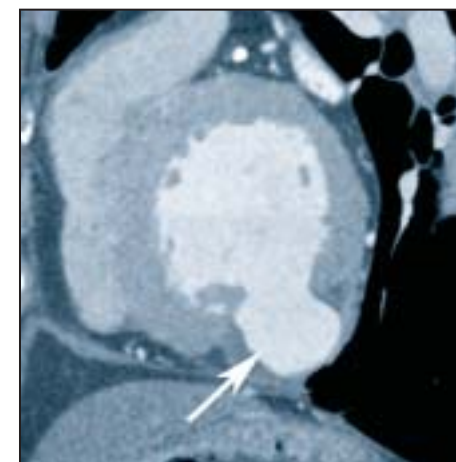
At the University of California, San Francisco, where Dr. Reddy is chief of cardiac and pulmonary imaging, stroke patients are routinely scanned from the head down to the heart. Other modalities such as transthoracic or transesophageal echocardiography or MRI may be superior for evaluating cardiac masses, cardiomyopathy, or ischemic heart disease, but the ability to obtain a comprehensive evaluation from one sitting using CT can be advantageous for both the patient and physician—especially in the emergency setting.

The most common cardiac source of stroke is emboli, Dr. Reddy said. One such patient, diagnosed using multidetector CT, who had a history of atrial fibrillation and had been on anticoagulation, decided to stop taking his medication, then developed a stroke caused by a thrombus originating in the left atrium. Mitral stenosis is another common source of cardiac thrombus from the atrium.

Coagulation disorders and aneurysms may cause cardiac thrombi that originate in the ventricles. Left ventricular aneurysms may follow myocardial infar-



The arrow shows a thrombus in a true aneurysm of the left ventricle.



A false aneurysm in the postero-inferior aspect of the LV is reconstructed on CT.

tion and can be categorized as either true or false aneurysms.

True aneurysms characteristically have an anteroapical location with a wide ostium (greater than 50% of the aneurysm diameter). In contrast, false aneurysms are postdiaphragmatic with narrow ostia. Accurate and rapid diagnosis can have an impact on treatment, because true aneurysms are generally managed medically while false aneurysms require resection.

Cardiac tumors can also embolize to the brain. According to Dr. Reddy, about 98% of cardiac tumors are metastases from another source. Of primary cardiac tumors, myxomas, which are benign, are the most

common and most likely to produce brain emboli. In fact, avoiding brain emboli is one of the major reasons for myxoma resection. Primary malignant tumors of the heart, such as angiosarcomas, also have the potential to embolize and cause stroke, as can secondary tumors such as lymphoma.

Cardiac imaging also can reveal the presence of patent foramen ovale or other septal defects in patients with strokes. These openings allow a clot or tumor to pass from the right side to the left side of the heart, and then enter the arterial circulation as a paradoxical embolism. Repair of even small defects may be recommended to avoid subsequent strokes, Dr. Reddy said. ■

Silent Myocardial Ischemia Reversible in Type 2 Diabetes

BY DOUG BRUNK
San Diego Bureau

SAN DIEGO — Nearly 80% of patients with type 2 diabetes who had silent myocardial ischemia revealed by stress myocardial perfusion imaging had a reversal of exercise-induced myocardial perfusion abnormalities 3 years later.

The unexpected finding suggests that a substantial proportion of patients with type 2 diabetes and silent myocardial ischemia have the potential for improvement of stress myocardial perfusion imaging abnormalities with medical management, Dr. Frans J.Th. Wackers said at the annual meeting of the American Society of Nuclear Cardiology.

“These results are consistent with the INSPIRE study and the COURAGE trial, which found that aggressive and optimal treatment can reverse myocardial perfusion abnormalities,” said Dr. Wackers, director of the cardiovascular nuclear imaging and stress laboratories at Yale University, New Haven.

The study was a follow-up to the Detection of Ischemia in Asymptomatic Diabetics (DIAD)-1 study, which documented a 22% prevalence of silent myocardial ischemia during adenosine stress testing with sestamibi SPECT myocardial perfusion imaging. In the current study, known as DIAD-2, Dr. Wackers and associates performed repeat stress myocardial perfusion imaging in DIAD-1 study participants after 3 years to evaluate for pro-

gression of silent myocardial ischemia. Initial myocardial perfusion imaging was performed in 2003, and repeat myocardial perfusion imaging was performed in 2006.

Of the initial 522 patients, 356 underwent repeat myocardial perfusion imaging, 70 of whom had previously documented silent myocardial ischemia in DIAD-1. The mean age of the 356 patients was 61 years, and 44% were women.

Repeat myocardial perfusion imaging could not be performed in 166 patients because of an intervening cardiovascular event or death, in 29 patients; severe comorbidity, in 10; refusal by 108 patients; loss to follow-up in 17; and uninterpretable study in 2. The initial and repeat DIAD studies were read by the same blinded panel of experts, said Dr. Wackers.

The overall prevalence of silent myocardial ischemia in DIAD-2 was 12%, which is 10% lower than the overall prevalence in DIAD-1.

In addition, of the 286 patients who had normal DIAD-1 studies, 90% remained normal in DIAD-2, whereas 10% developed new myocardial ischemia.

Of the 71 patients who had abnormal DIAD-1 studies, 56 (79%) showed resolution of inducible ischemia, and 15 (21%) remained abnormal.

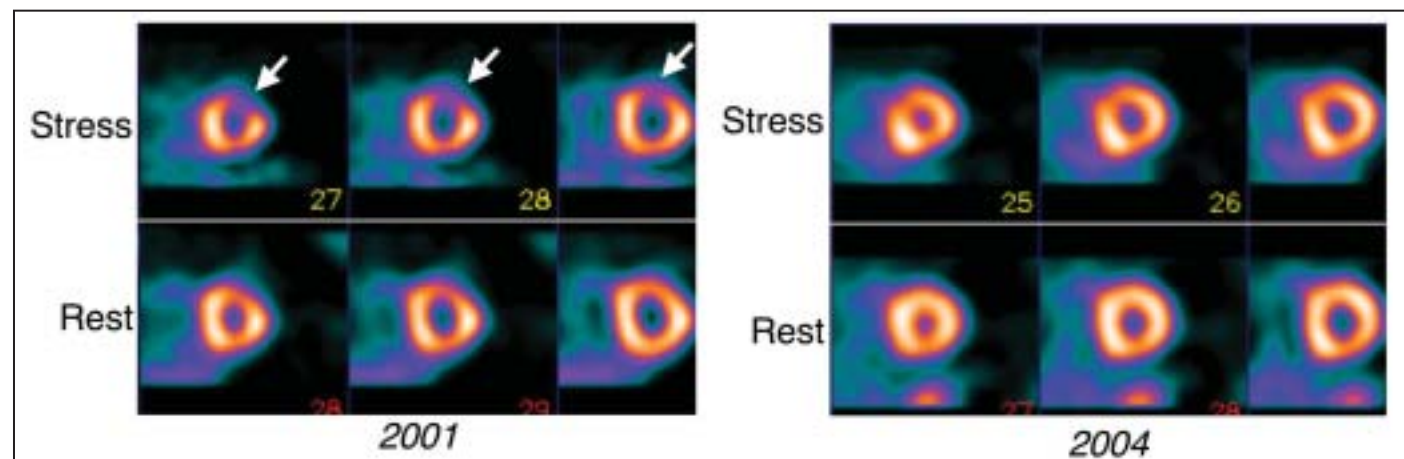
When the researchers compared patients who had resolution of ischemia with those who developed new inducible ischemia, they observed no significant baseline differences in age, gender, BMI, duration of diabetes, family history, blood pressure, hemoglobin A_{1c}, LDL or HDL

cholesterol, or C-reactive protein.

In another part of the analysis, the researchers observed a significant increase among all patients in the use of aspirin, statins, and ACE inhibitors between 2003 and 2006. Specifically, the use of aspirin rose from 42% to 69%, the use of statins rose from 38% to 59%, and the use of ACE inhibitors rose from 34% to 42%.

DIAD-2 patients who had resolution of ischemia were exposed to cardiac medications for a significantly longer period of time, compared with those who developed new ischemia (59 months vs. 45 months).

Dr. Wackers has received research honoraria from Bristol-Myers Squibb, Astellas, and General Electric, and is a scientific adviser for General Electric and King Pharmaceuticals. ■



In 2001 (left), a 59-year-old asymptomatic man had a small defect in the anterior wall (arrows) on sestamibi SPECT imaging. By 2004 (right), the defect had normalized. During the interval, the patient was treated with aspirin, a statin, and an ACE inhibitor.