

Energy Plus Phototherapy Clears Acne in Dark Skin

ARTICLES BY SHARON WORCESTER
Southeast Bureau

KISSIMMEE, FLA. — Combined radiofrequency energy and indocyanine green-mediated pulsed light phototherapy proved highly effective for the treatment of acne in a study of 14 Fitzpatrick skin type IV patients with substantial facial acne.

The patients, who were aged 16-35 years (mean age 25 years), and who had at least 10 inflamed facial acne lesions, were treated with 1 mg/mL indocyanine green (ICG)

cream, which was applied to the face for 30 minutes and then wiped off. This was followed by combination pulsed light at 580-980 nm, and a radiofrequency device, Syneron Medical Ltd.'s Aurora SR, at an optical energy of 18-22 J/cm² and a radiofrequency dose of 20 J/cm³. Dr. Nark-Kyoung Rho reported at the annual meeting of the American Society for Laser Medicine and Surgery.

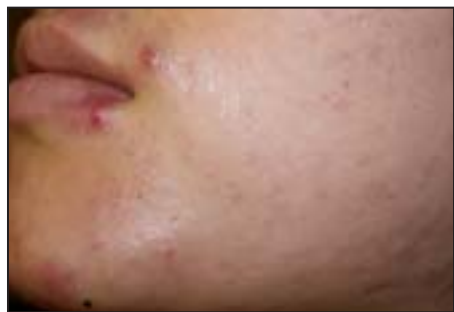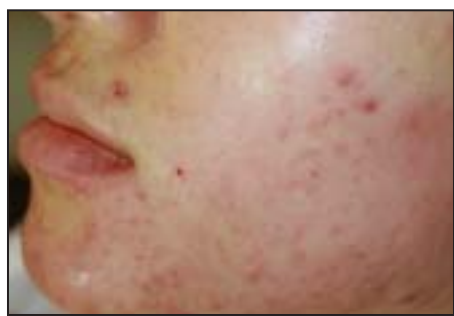The patients, who received no topical or oral acne medications in the 2 months prior to study initiation, received three treatments at 4-week intervals.

Lesion count decreased by 18%, 49%, 68%, and 76%, at 4, 8, 12, and 16 weeks, respec-

tively, after the initial treatment, said Dr. Rho of the Leaders Clinic in Seoul, South Korea.

Follow-up at 1, 4, 7, and 14 days after each treatment showed that side effects were minimal, and included only transient stinging and slight peeling, said Dr. Rho, who reported that he had no financial disclosures associated with his presentation.

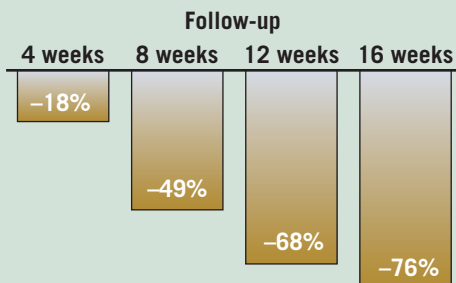
ICG-mediated near-infrared light phototherapy has received a great deal of attention for the treatment of acne because of its sebaceous gland selectivity and high penetration depth. In addition, radiofrequency energy is known to reduce sebum production. Together, these treatments can substantially reduce the number of acne lesions, he said. ■



A 31-year-old female patient is shown before treatment (top). Improvement is seen after one session (bottom).

PHOTOS COURTESY DR. NARK-KYOUNG RHO

Acne Lesion Count Decreased With Indocyanine Green-Mediated Pulsed Light Phototherapy



Note: Based on a study of 14 patients with Fitzpatrick skin type IV and at least 10 inflamed facial acne lesions.

Source: Dr. Rho

Over 75% Had Diminished Scarring After Fraxel Tx

KISSIMMEE, FLA. — A novel fractional CO₂ resurfacing device significantly and safely improved moderate to severe acne scarring in a recent study.

More than 75% of the patients studied sustained moderate to significant improvement in their acne scarring at 3 months following final treatment, Dr. Arisa Ortiz reported at the annual meeting of the American Society of Laser Medicine and Surgery.

The 15 patients, who were aged 21-60 years, had moderate to severe acne scars and had Fitzpatrick skin types I-IV. They underwent up to three treatments with the Fraxel re:pair 10,600-nm fractional CO₂ laser system (Reliant Technologies Inc.), said Dr. Ortiz, who is with the University of California, Irvine.

Treatment parameters ranged from 20 to 70 mJ with 600-1,200 microthermal zones/cm².

Patient evaluations were conducted using digital photographic assessment at 3 days, 1 week, 1 month, and 3 months following treatment. Specifically, skin texture, wrinkles, pigmentation, skin laxity, scarring, and overall appearance were evaluated.

Of the 15 patients, 13 were considered to have shown improvement in the appearance of scarring, with an added benefit of improved overall appearance based on physician assessment, noted Dr. Ortiz, who reported that she received equipment and honoraria from Reliant.

Of 13 who had pigmentation, 11

were improved, and of 8 with rhytids, 6 improved.

Of eight who had only one treatment, one had no improvement, five had minor improvement, and two had moderate improvement. Of two who had two treatments, both had moderate improvement. Of five who had three treatments, one had no improvement, three had moderate improvement, and one had "very significant" improvement, she said.

Smoother skin texture was an example of minor improvement, and substantial improvement in ice pick scarring was an example of moderate improvement, Dr. Ortiz pointed out, explaining that higher fluences appeared to result in greater improvements, compared with lower fluences in patients who had the same number of treatments.

In those with the greatest improvements, three treatments at fluences of 40-70 mJ were used, and those patients had the added benefit of improvements in rhytids as well as in acne scarring, Dr. Ortiz said.

All of the patients experienced transient erythema, which resolved within 3 months.

No serious patient complications occurred, and any serosanguineous oozing resolved within 48 hours of treatment.

When compared with traditional ablative resurfacing, the fractional CO₂ laser treatment resulted in less patient downtime and reduced complication rates, Dr. Ortiz concluded. ■

Acne Scars May Respond to Fixed Array Fractional Erbium Laser

KISSIMMEE, FLA. — Treatment with a fixed array fractional 1540-nm erbium laser was effective for improving acne scars, a review of 181 patients found.

At 3-month follow-up, the patients who underwent three treatments at 4-week intervals with the Lux1540 laser (Palomar Medical Technologies Inc., Burlington, Mass.) had a median improvement of 3 by Canfield blinded photographic evaluation (Canfield Scientific Inc. Omnia system), which translates to a 50%-75% improvement in scar appearance, Dr. Robert A. Weiss reported at the annual meeting of the American Society of Laser Medicine and Surgery.

Treatments were given using the 10-mm, 100-microbeam per pulse handpiece for a minimum of three passes per treatment site at 10-millisecond pulse duration. Fluence was

set at 50-70 mJ/microbeam, said Dr. Weiss of the Maryland Laser, Skin, and Vein Institute, Baltimore.

Self-assessed treatment results indicated that the patients were pleased with the outcomes, with 85% rating their skin as improved. Patient self-assessment indicated that pain was minimal, with a reported average pain score of 2.75 out of 10.

Side effects were minimal and included mild erythema and edema, which resolved in all patients within 24 hours.

The findings suggest that a minimal fluence of 50 mJ/microbeam with three passes is required to achieve improvement in acne scars with this laser, Dr. Weiss noted.

The study was supported by Palomar, which provided Dr. Weiss with equipment, discounts, a research grant, and honoraria. ■

Surgical Scars Found to Improve After Fractional Photothermolysis

KISSIMMEE, FLA. — Fractional photothermolysis is a promising treatment for surgical scars, including those that have failed to fully respond to other treatments, a small study suggests.

In 13 patients with various types and ages of surgical scars, fractional resurfacing using Reliant Technologies Inc.'s 1,550-nm, erbium-doped fiber laser (Fraxel) resulted in greater than 75% improvement in nine patients and at least 51%-75% improvement in an additional two patients.

The remaining two patients achieved between 25% and 50% improvement, Dr. Joy Kunishige reported at the annual meeting of the American Society for Laser Medicine and Surgery.

The patients were treated for scars resulting from Mohs surgery, excision, trauma, or plastic surgery, and most underwent a total of three treatments (range, two to eight). Treatments were administered at energy levels of 6-70 mJ, with final densities of 312-2,500 microthermal zones per square centimeter.

Outcomes were based on physician assessment of photographs that were taken at baseline and at 2 weeks following final treatment.

"All the characteristics that we looked at improved, including atrophy, hypertrophy, hyperpigmentation, and erythema," said Dr. Kunishige of the University of Texas Health Sciences Center, Houston, noting that all outcomes scores were maintained at the 12-month follow-up.

Traditional scar treatment involves use of the pulsed dye laser, but it appears that fractional resurfacing may provide better depth of penetration, she said. "Admittedly, many of the scars were new, and were possibly still undergoing remodeling, but even older scars showed similar improvement."

Scars that had failed to respond fully to prior therapies also responded to the Fraxel laser. It appears that this laser can be used as monotherapy for treating scars, or as an adjunct to other treatments, she said.

Dr. Kunishige reported no financial conflicts related to her presentation. ■