

# Infrared Therapy Could Offer UVB Protection

Use of light-emitting diode device may protect skin from excess UVB as well as sunscreen with SPF 15.

BY MITCHEL L. ZOLER  
Philadelphia Bureau

GRAPEVINE, TEX. — Brief exposure of arm skin to infrared radiation appeared to protect against subsequent ultraviolet B exposure in a pilot study of 13 subjects, Dr. Daniel Barolet said at the annual meeting of the American Society for Laser Medicine and Surgery.

Results from this proof-of-concept study suggest that infrared pretreatment of skin with a light-emitting diode (LED) device may protect against ultraviolet B exposure as well as sunscreen, but in a way that's unaffected by moisture or perspiration, environmental factors, allergy, or compliance. The infrared-treatment protocols appeared to protect skin as well as a sunscreen with SPF 15, said Dr. Barolet, a dermatologist at McGill University in Montreal.

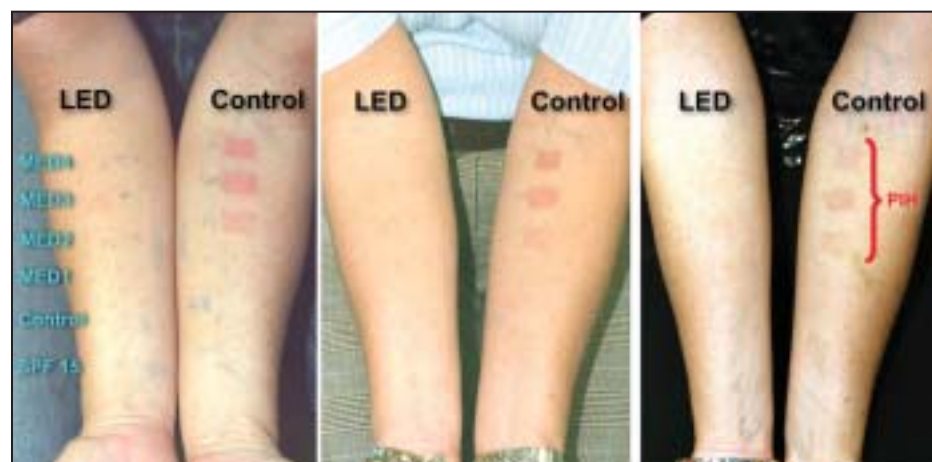The investigators tested an infrared,

LED device that delivered 660-nm radiation at a power density of 50 mW/cm<sup>2</sup> and a fluence of 4.5 J/cm<sup>2</sup>. Each treatment session lasted 3 minutes.

The LumiPhase-R device used in the study to produce infrared protection was made by Opusmed, a company based in Montreal. Dr. Barolet founded the company and is a stockholder.

The study tested several different treatment regimens, ranging from 6 treatment sessions over 3 weeks to 10 sessions during 1 week. Thirteen people (seven women and six men) completed the study. Their age range was 19-50 years, with a mean age of 41.

The subjects received their prespecified infrared regimen on the skin of their right arms, with their left arms remaining untreated and acting as controls. A patch on both arms was also treated with an SPF-15 sunscreen. Following pretreatment, both arms received a series of escalating



The right arms of patients received three doses of infrared light over 6 days prior to indicated dosages of ultraviolet B exposure. Infrared pretreatment reduced both acute erythema and long-term, postinflammatory hyperpigmentation (PIH).

ultraviolet B doses, and patients were followed for at least 1 month. Each arm received ultraviolet radiation on a treated and a control skin patch that corresponded to one minimal erythema dose (MED1), and also to a series of higher MEDs, up to MED4.

All of the treatment regimens studies

showed some ultraviolet B protection, with the most consistent protection coming against the effects of exposure to MED1 and MED2. The level of protection seemed to be dose dependent, with the best protection provided by a regimen of 10 infrared treatments in 1 week, said Dr. Barolet.

## Temporary Fillers Allow Skill Development With Little Risk

BY CAROLYN SACHS  
Contributing Writer

MAUI, HAWAII — “If you do Botox, you can certainly do fillers,” Dr. Howard K. Steinman said at the annual Hawaii Dermatology Seminar sponsored by Skin Disease Education Foundation.

Dr. Steinman stressed the importance of developing skills with injectable fillers, noting their ease of use, minimal risk and downtime, efficacy, and high patient and clinician satisfaction. “They’re rapidly becoming the ‘go to’ treatment for lots of types of facial rejuvenation,” he said.

Honing skills using temporary fillers, he suggested, is a good way to learn. “I would start with temporary fillers, before you [use] semipermanent fillers, and certainly before you go to permanent fillers,” said Dr. Steinman of the University of California, San Diego.

He acknowledged that temporary fillers present a conundrum. For the patient, the problem with temporary fillers is that they’re temporary. “They only last 3-6 or 9 months. My patients don’t like it [because] they have to keep coming back,” Dr. Steinman noted. But for those who are learning to use them, the advantage of temporary fillers is that they’re temporary.

“If you’re thinking of doing lips, I would suggest first learning with a temporary filler before you mess up somebody’s lips permanently,” he cautioned.

More important, if a woman has never had her lips or nasolabial folds face enlarged and she’s not sure that she wants it, do not give her a semipermanent or permanent filler since she may not like the results, he said.

A “cool thing” about the temporary filler hyaluronic acid, Dr. Steinman noted,

is that it is dissolved by hyaluronidase, which is readily available. In one situation in which a lump had appeared when he was using a hyaluronic acid filler, he was able to eliminate the lump by injecting hyaluronidase.

While learning on temporary fillers, treat forgiving areas first. The easiest way to do that is to treat patients after botulinum toxin type A injections. “They already trust you to stick needles in their face,” he explained, “and many of them have wrinkles that won’t completely go away.”

Dr. Steinman recalled a patient whom he had told, “Your glabellar rhytid is not going to completely resolve with the Botox.” As he predicted, she had a good result with Botox but still had a rhytid. “That’s a great place to learn,” he said.

“There’s a synergy between the places I inject Botox and the places where you

can learn to inject hyaluronic acid.” (See box.) For instance, he said, “Nasolabial folds are an excellent location—and glabellar lines.”

Using fillers after Botox is a highly effective, versatile, nonablative, low-risk treatment option that can be useful for resistant resting rhytids.

Use the filler after waiting for maximal botulinum effect. Fillers often last longer when placed after botulinum, said Dr. Steinman, who stated that he had no conflicts of interest.

After learning on more forgiving areas, move on to other areas. He started treating lip patients once he had developed his skills.

“The last place I would suggest you learn is the teardrop of the eyelid,” he said. Above all, he urged, “use common sense.”

SDEF and this news organization are wholly owned subsidiaries of Elsevier. ■

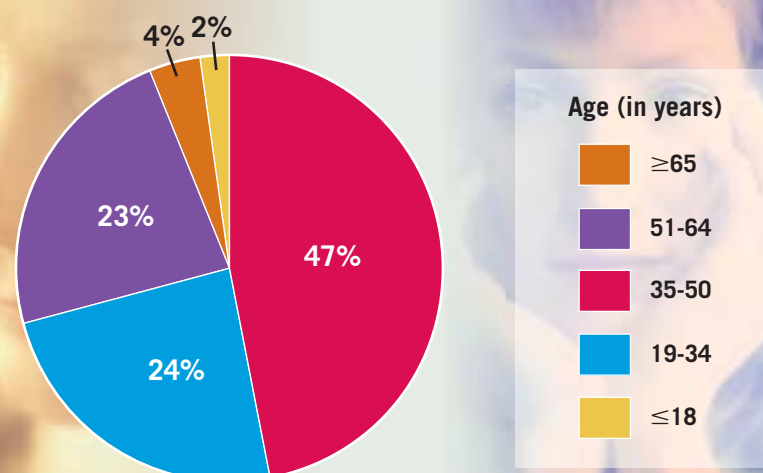
### Fillers After Botox

	Temporary		Semipermanent	
	Collagen	Hyaluronic acid	Calcium hydroxylapatite	Poly-L-lactic acid
Forehead lines		✓	✓	
Brow elevation		✓		
Glabellar and nasal root lines	✓	✓	✓	
Crow's feet rhytids	✓	✓		
Lower lid rhytids	✓	✓		
Lip lines	✓	✓		
Oral commissure ptosis		✓	✓	✓
Marionette lines		✓	✓	✓
Prejowl sulcus		✓	✓	✓
Neck radial (necklace) lines		✓		

Source: Dr. Steinman

### DATA WATCH

#### 35- to 50-Year-Olds Have the Most Cosmetic Procedures



Source: 2005 data, American Society for Aesthetic Plastic Surgery