

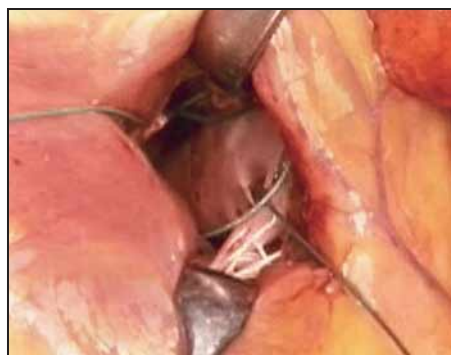# Left Ventricular Volume Reduced With Suturing

BY MITCHEL L. ZOLER  
Philadelphia Bureau

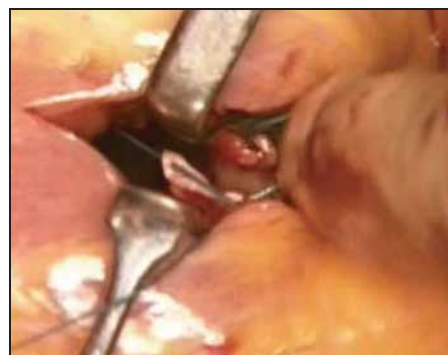MUNICH — A novel surgical method reduces the left ventricular volume of patients with cardiomyopathy without using ventriculectomy.

The surgery realigns the papillary muscles of the left ventricle and reduces left ventricular volume by placing three sutures through the trabeculae around the bases of the anterior and posterior muscles, Diane Barker, M.B., said at the annual congress of the European Society of Cardiology.

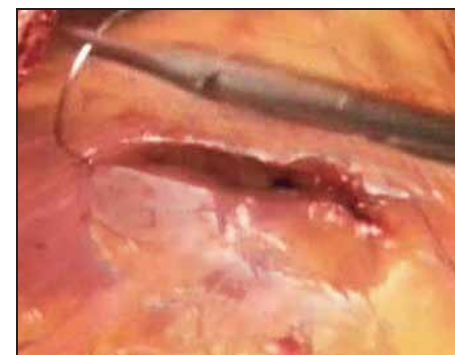The procedure, which involves graded placement of the papillary muscle through a small, apical incision, usually takes about 15-20 minutes, said Dr. Barker, a cardiologist at Leeds (England) Gen-



This image shows the placement of the sutures through the trabeculae.



This image shows the sutures being tied in the novel procedure.



This image shows the surgical incision being repaired.

eral Infirmary. The suturing also reduces functional mitral regurgitation. It is generally combined with coronary bypass grafting.

Unnikrishnan R. Nair, M.B., who developed the new technique, has used it to treat 30 patients in Leeds since 1998. Follow-up has ranged from 12 to 58 months, with an average of 28 months. One patient died within 30 days of the procedure from sepsis. Another patient developed atrial fibrillation following surgery. All of the other patients had improvements in their left ventricular function and in their clinical status, and none developed ventricular arrhythmias, Dr. Barker reported. Three patients died 4-24 months following surgery, but the deaths appeared unrelated to surgery. The average age of the patients was 61 years, and three-quarters were men. All of the patients had ischemic cardiomyopathy. The average left ventricular volume of patients before the surgery was 271 mL; after surgery, 230 mL. Before surgery, the patients had heart failure with

an average New York Heart Association functional classification of 2.8; after surgery, the average was 1.4.

To better assess this surgery, Dr. Barker and Dr. Nair compared 8 patients who underwent suturing of papillary muscle plus bypass surgery with 32 similar patients treated with bypass surgery only. (See box.)

Exercise duration improved among patients who underwent papillary muscle suturing compared with those who had bypass surgery only. Peak oxygen capacity rose among the patients treated with papillary muscle suturing compared with those who had bypass surgery only. Cardiac reserve rose among patients treated compared with the control group.

The next step is to test the surgery's safety and efficacy in a randomized, controlled study, Dr. Barker said. ■

## Improvement in Cardiac Function After Bypass Grafting, With or Without Suturing of Left Ventricular Papillary Muscle

Measure	Average increase after bypass grafting plus suturing (n = 8)	Average increase after bypass grafting only (n = 32)
Cardiac reserve	168%	14%
Peak cardiac power output	83%	11%
Peak cardiac output	35%	6%
Exercise duration	33%	18%
Peak VO <sub>2</sub>	21%	9%

Source: Dr. Barker

# New Surgery in Infants With Hypoplastic Left Heart Syndrome

BY MIRIAM E. TUCKER  
Senior Writer

WASHINGTON — A new minimally invasive surgical technique could considerably improve the prognosis for infants born with hypoplastic left heart syndrome, Emile Bacha, M.D., said at a conference for science reporters sponsored by the American Medical Association.

Hyperplastic left heart syndrome (HLS), one of the most severe congenital heart defects, occurs in approximately 0.016%-0.036% of all live births in the United States, said Dr. Bacha, a pediatric cardiologic surgeon at the University of Chicago.

HLS is most often treated with a set of three extremely invasive, delicate open-heart surgical procedures aimed at providing unobstructed outflow to the heart via a single ventricle system and unobstructed pulmonary venous return, while shunting a portion of the blood away to feed the lungs and provide gas exchange.

Stage I, the Norwood operation, is performed within days of life. Stage II, the Glenn operation, follows at 6 months, while the stage III Fontan operation is done at 24 months.

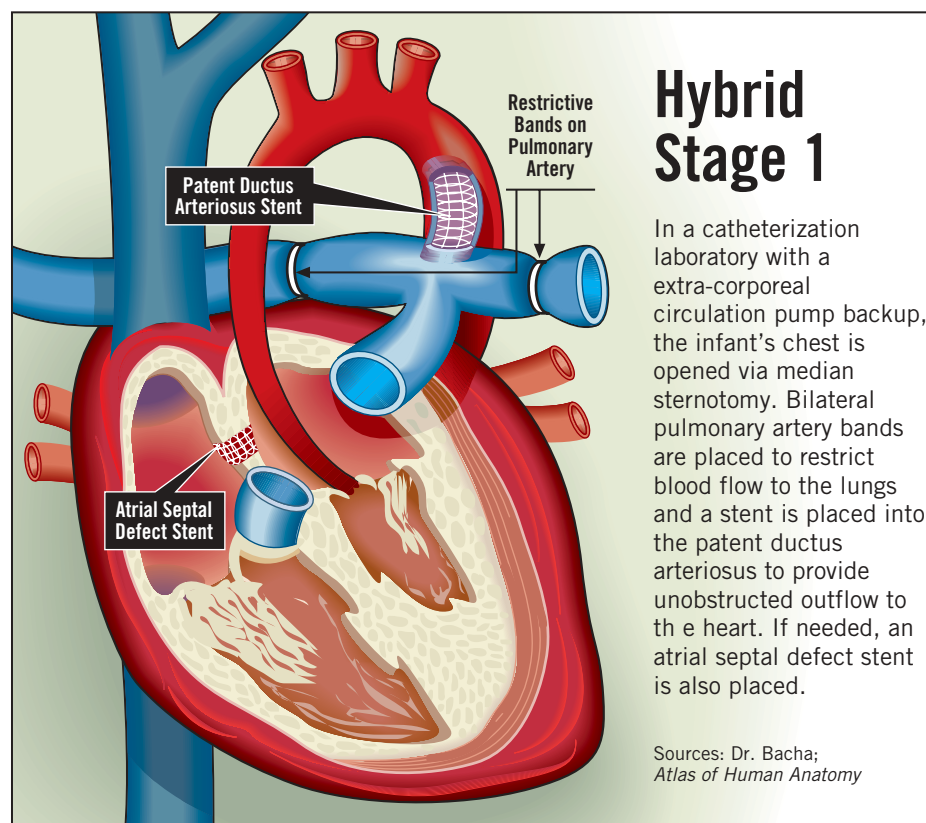
Although 80%-90% of infants survive the Norwood stage I, about 10%-15% die before reaching the second procedure. Many infants who survive the entire series have below average IQ, abnormal neurologic development, and diminished quality of life.

Hybrid therapy, a combination of inter-

ventional cardiology and pediatric cardiac surgery techniques, replaces the traditional open-heart Norwood stage I operation with a palliative beating-heart procedure, he explained. Rather than cooling the body and putting the newborn on heart bypass for a lengthy period, the hybrid stage I is conducted in a specially outfitted catheterization laboratory that includes extra-corporeal circulation membrane oxygenation pump backup. (See illustration.)

Dr. Bacha and his colleague Ziyad M. Hijazi, M.D., have performed the procedure on 10 high-risk newborns (weight 2.2-3.3 kg) with HLS, of whom 6 also had aortic atresia, and 3 each had a major noncardiac anomaly, poor ventricular function, and/or weight less than 2.5 kg. Two were older than 30 days, one presented in shock, and one was born at less than 34 weeks' gestation. One infant died in the hospital following the procedure, resulting in the same hospital survival rate as the traditional Norwood stage I. Another died before reaching the second stage. Seven of the remaining eight have now undergone the Glenn stage II, of whom six have survived.

The Glenn and Fontan procedures are still necessary after hybrid stage I, but Dr. Bacha believes the elimination of one of three traumatic "pump runs" over the first 2 years of life and the postponement of the first beyond the neonatal period may reduce the neurologic complications often associated with bypass procedures.



## Hybrid Stage 1

In a catheterization laboratory with an extra-corporeal circulation pump backup, the infant's chest is opened via median sternotomy. Bilateral pulmonary artery bands are placed to restrict blood flow to the lungs and a stent is placed into the patent ductus arteriosus to provide unobstructed outflow to the heart. If needed, an atrial septal defect stent is also placed.

Sources: Dr. Bacha; *Atlas of Human Anatomy*

The hybrid procedure itself and the length of hospital stay were considerably shorter than with the traditional Norwood procedure. One disadvantage of the hybrid technique is that the Glenn procedure is more complicated, since the aortic arch must be reconstructed while the previously implanted stent is removed.

"You're now doing the open-heart surgery on a 3- to 6-month-old, rather than a 5-day-old. ... That is a huge difference in terms of sensitivity to trauma and brain maturity," Dr. Bacha said. Several newer technologies, including therapeutic ultrasound and absorbable stents, will improve the feasibility of the procedure, he said. ■