

# Study Shows Tacrolimus Better for Atopic Dermatitis

BY BETSY BATES  
Los Angeles Bureau

NEW YORK — Tacrolimus proved to be more efficacious and no more irritating than pimecrolimus in the first large head-to-head comparison of the two topical immunomodulators in patients with atopic dermatitis, Dr. Alan B. Fleischer Jr. said at the American Academy of Dermatology's Academy 2004 meeting.

Previous studies had suggested "that tacrolimus ointment was much more effective than pimecrolimus cream, but the issue of tolerability—burning, stinging, redness—was quite unclear," said Dr. Fleischer, professor and chair of dermatology at Wake Forest University, Winston-Salem, N.C.

As the result of these studies, he added, tacrolimus can be said to be not only more effective, but also equally well tolerated.

Dr. Fleischer directed the 6-week, randomized, investigator-blinded study of 1,056 patients with mild to severe atopic dermatitis (AD). Overall, 43% of patients who received tacrolimus were judged by the Investigator's Global Atopic Dermatitis Assessment to be "clear or almost clear," compared with 31% of patients who received pimecrolimus, for a *P* value of less than .0001.

Only in children aged 2-15 years who had mild AD and were treated with 0.03% tacrolimus did the drug fail to show a statistically significant effect on this outcome variable. (See chart.)

On another measure—the 0- to 72-point

Eczema Area and Severity Index (EASI)—the mean score of patients taking tacrolimus declined by 53 points, compared with a mean decline of 39 points for pimecrolimus patients, for a *P* value of less than .0001.

Itch scores showed a particularly profound decline among pediatric and adult patients with moderate to severe AD. Among such children, for example, the difference in itch scores reached a *P* value of .006 by the first week. Children with mild AD who were treated with the less potent concentration of tacrolimus also itched less than those treated with pimecrolimus, but the difference was not dramatic until day 43, when the *P* value reached .008.

Tolerability scores, which were first collected at the end of week 1 of therapy, never demonstrated a statistical difference between the two agents.

The study was sponsored by Fujisawa Healthcare Inc., which makes tacrolimus ointment.

Dr. Fleischer said a presumed tolerability advantage for pimecrolimus emerged from preapproval studies that did not involve patient groups with equally severe AD and used different criteria to judge side effects.

Some patients will still prefer a cream formulation to the ointment vehicle used for tacrolimus, and Dr. Fleischer said he personally believes there is a role for both medications.

"They're both safer than topical steroids used over the long term," he said. "A young woman may not want to put an ointment on her face in the morning, but now we can give patients a choice." ■

## Clearing on Tacrolimus vs. Pimecrolimus

	Adults With Mild to Severe AD	Children With Moderate to Severe AD	Children With Mild AD
Pimecrolimus 1%	27% (n = 203)	18% (n = 106)	41% (n = 217)
Tacrolimus 0.1%	46% (n = 210)	32% (n = 112)	n/a
Tacrolimus 0.3%	n/a	n/a	47% (n = 208)

Note: Clearing based on the Investigator's Global Atopic Dermatitis Assessment.  
Source: Dr. Fleischer

## High Th2 Cytokine Levels May Contribute To Superinfections in Atopic Dermatitis

VIENNA — Levels of some of the skin's key innate antimicrobial peptides are abnormally low in patients with atopic dermatitis, perhaps accounting for the high rate of bacterial and viral superinfections in this population, Jurgen Harder, M.D., said at the annual meeting of the European Society for Dermatological Research.

The explanation for the low skin levels of antimicrobial peptides may lie in the high levels of Th2 cytokines typically present in atopic skin. These cytokines appear to sharply inhibit secretion of the antimicrobial peptides by keratinocytes, added Dr. Harder of the University of Kiel (Germany).

He presented evidence from in vitro studies

done in Kiel showing that high concentrations of the Th2 cytokines interleukin-4 (IL-4), IL-10, and IL-13 greatly dampen the normally robust induction of an important antimicrobial peptide in normal skin, human  $\alpha$ -defensin-2, by *Pseudomonas aeruginosa*.

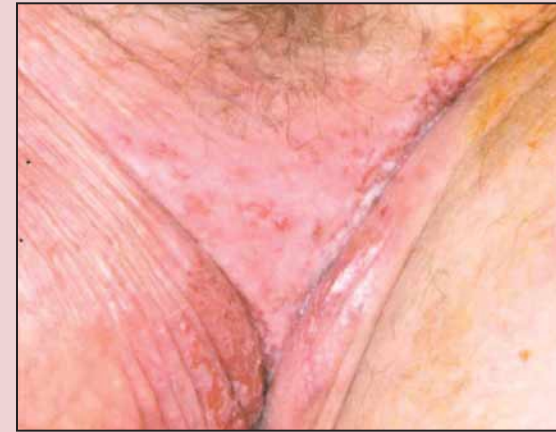These findings are consistent with the hypothesis that bacterially mediated induction of inducible antimicrobial proteins is disrupted in atopic dermatitis patients and that the culprit is high levels of the Th2 cytokines.

Decreasing elevated Th2 cytokine levels may be a novel strategy to prevent cutaneous superinfections in patients with atopic dermatitis, Dr. Harder said.

—Bruce Jancin

## DERM Dx

A 77-year-old man presented with a subcentimeter lesion in his left groin. A punch biopsy was performed, and the initial diagnosis was Merkel cell cancer. Two months later, a follow-up examination revealed a 1-cm-by-1-cm raised nodular mass in his left groin, surrounded by a 10-cm<sup>2</sup> area identified as "candidiasis." Dermatology was consulted. What's your diagnosis?



BOCA RATON, FLA. — A punch biopsy revealed a malignant neoplasm that was diagnosed as Merkel cell carcinoma. The patient was referred to the University of Florida for further evaluation.

The surgeon at the university wanted to do a wide excision of the lesion and sentinel lymph node. A lymph node dissection was planned in the event that the sentinel node came back positive.

The patient's candidiasis had not improved after 10 days of treatment with ketoconazole, so surgeons referred him to dermatology. The dermatologist examined the 1-cm-by-1-cm raised nodular mass in the patient's left groin surrounded by 10 cm<sup>2</sup> of "candidiasis." The dermatologist suspected extramammary Paget's disease.

The patient underwent removal of the lesion and sentinel node. Pathology revealed that the tumor was not Merkel cell, but an infiltrative apocrine adenocarcinoma. The rash was confirmed to be extramammary Paget's disease, and the sentinel node was positive, said Justin Wasserman, a fourth-year med-

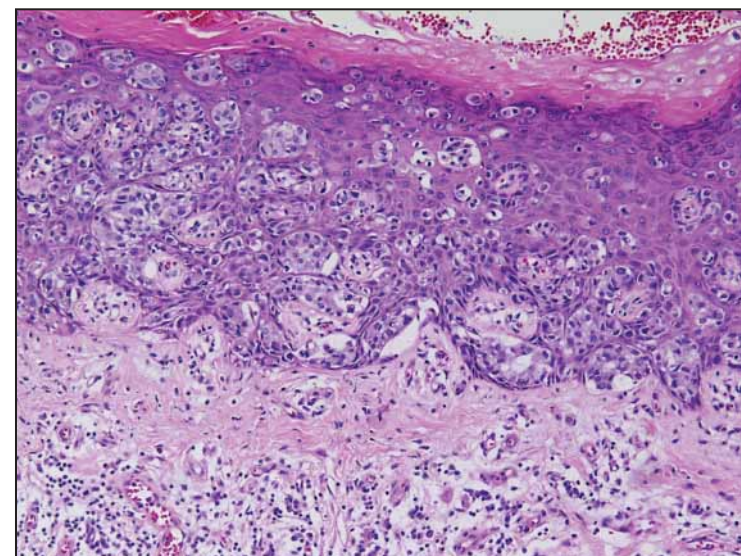
ical student at the university.

"Due to the patient's age and his comorbidity—he had Alzheimer's disease—his family did not want him to have additional surgery," Mr. Wasserman said at the annual meeting of the Florida Society of Dermatologic Surgeons. So the patient did not undergo lymph node dissection. The extramammary Paget's disease was treated topically with imiquimod.

This case illustrates that, "groin rashes that have been adequately treated without improvement should be biopsied," Mr. Wasserman said.

The patient was prescribed a 16-week course of imiquimod to be applied three times a week to the visible areas and about 2 inches beyond. After 8 weeks, there was some irritation to the area, but the rash had cleared almost completely except for a small area on the left lateral edge. The patient was instructed to discontinue imiquimod for 6 weeks. If at that time any rash still remained, he was instructed to restart and use the cream three times a week for an additional 16 weeks.

—Damian McNamara



PHOTOS COURTESY MR. JUSTIN WASSERMAN