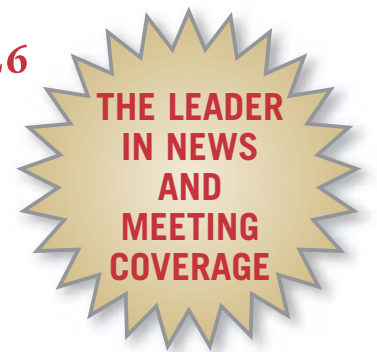



# Skin & Allergy News



www.skinandallergynews.com

VOL. 40, NO. 10

The Leading Independent Newspaper for Medical, Surgical, and Aesthetic Dermatology

OCTOBER 2009

The Seal of Recognition program reflects the academy's efforts "to do everything possible to reduce the incidence of skin cancer," said Dr. James M. Spencer.



COURTESY DR. JAMES M. SPENCER

## AAD Seal Program Off to a Slow Start

BY DOUG BRUNK

Two years after the American Academy of Dermatology's Seal of Recognition program was launched, six products have been recognized for their sun protection benefits.

In an interview, Dr. James M. Spencer, who oversees the program, said that he expected the list of recognized products "to be somewhat larger" by now. He acknowledged that part of the slow start may stem from controversy the program generated at the AAD's annual meeting in 2008, most notably by the late dermatopathologist A. Bernard Ackerman.

"He did not feel that sunlight causes melanoma," recalled Dr. Spencer, who also chairs the AAD's Melanoma/Skin Cancer Committee. "If you have that position, why would you want

to encourage people to wear sun protection products? He also felt that [the Seal of Recognition program] was a conflict of interest financially; that it tainted the AAD. We're all sensitive to that. Potential conflicts of interest come up in practice all the time. Professionalism means putting your duty ahead of your personal benefit."

Dr. Spencer of Mount Sinai School of Medicine, New York, went on to emphasize that while he is sensitive to the arguments against the program, "at the end of the day it's like giving a medication: We weigh the risks versus the benefits. The benefits are, if we can get people to use effective sun protection products more, that's a benefit. The risks are that it may make us appear like we've sold out somehow. We have to weigh those two against each other. To me,

See AAD page 22

### INSIDE

#### FDA News

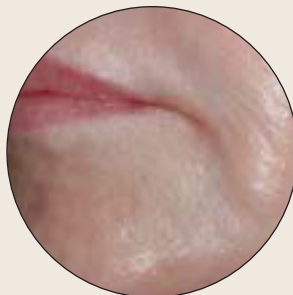Panel backs HPV vaccine for males and supports second vaccine for girls.

PAGES 8 & 9

#### Under My Skin

Exploding squids are just the beginning of Dr. Rockoff's strange tales.

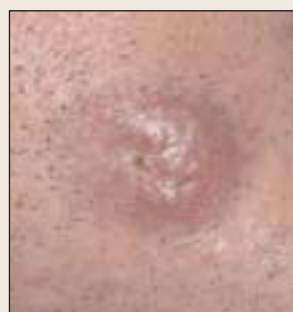PAGE 13



#### Eeny, Meeny, Miny, Moe

With so many fillers to pick from, it takes experience to choose the right one.

PAGE 16



#### AEIOU

Vowel acronym can help make Merkel cell carcinoma diagnosis.

PAGE 21

## Psoriasis Doesn't Up Hospitalization For Heart Disease

New study contradicts recent findings.

BY BRUCE JANCIN

BUDAPEST — The last word on the relationship between psoriasis and cardiovascular disease may not be in, according to the results of a new study.

Contrary to earlier studies, psoriasis was found to not be an independent risk factor for hospitalization for ischemic heart disease in a large Dutch study, Dr. Marlies Wakkee reported at the annual congress of the European Society for Dermatological Research.

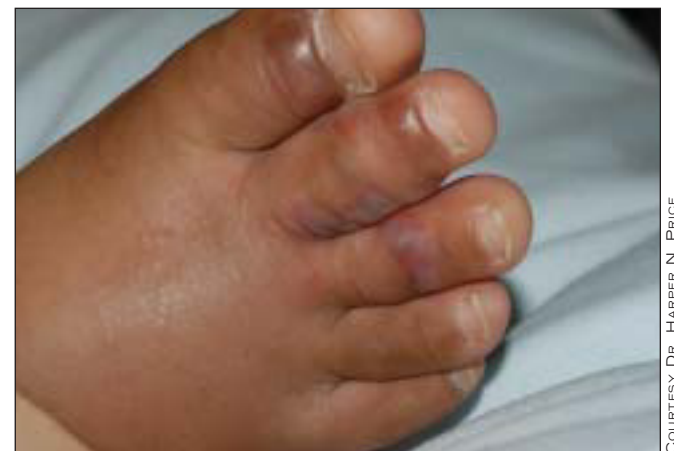Even after subdividing the 15,820 Dutch psoriasis patients in the study into those who used only topical therapy versus pa-

tients with more severe disease—as defined by use of systemic therapies or hospitalization for psoriasis—the more severely affected patients did not have a higher rate of ischemic heart disease (IHD) hospitalization, said Dr. Wakkee of Erasmus University Medical Center, Rotterdam.

The same held true when the analysis was narrowed to hospitalization for acute myocardial infarction (MI). The psoriasis patients, even those with more severe skin disease, did not have a greater rate of MI than controls, she added.

The study relied upon hospitalization data. See Psoriasis page 11

### CASE OF THE MONTH



COURTESY DR. HARPER N. PRICE

A 5-year-old African American child presented with a 2-week history of swollen legs, abdominal pain, fever, fatigue, and blisters on her feet and toes. Her spleen was palpable, and she had an elevated white blood count and a low platelet count. What's your diagnosis? See Case of the Month, page 47.

SKIN DISEASE EDUCATION FOUNDATION'S 34<sup>TH</sup> ANNUAL [www.sdefderm.com](http://www.sdefderm.com)

## Hawaii Dermatology Seminar™


A CONTINUING MEDICAL EDUCATION CONFERENCE

FEBRUARY 14-19, 2010

HILTON WAIKOLOA HOTEL, BIG ISLAND HAWAII

Approved for 35.5 AMA PRA Category 1 Credit(s)™

Jointly sponsored by



## Some Question Motives

AAD from page 1

the benefits to society of driving sun protection products outweigh any potential risks. Life's full of decisions like that, isn't it?"

To have a product considered for the program, the manufacturer must pay a \$5,000 application fee, followed by a \$10,000 annual license fee upon approval of the application.

"This program was never intended to be a fund-raiser," said Dr. Spencer. "If there's any money left over [from the application fees] after program expenses, it goes solely to public education for skin cancer."

Loosely modeled after product endorsement programs established by the American Dental Association and the Skin Cancer Foundation, the AAD's Seal of Recognition program has a twofold purpose, Dr. Spencer said: to let consumers know that the product they're buying has a sun protection benefit, and "to raise awareness about the importance of sun protection. According to recent surveys the use of sunscreen is going down."

Each product undergoes a review every 2 years to ensure that it still meets evidence-based criteria as set forth by the AAD. "It is a fairly high hurdle for a product to have these independent studies, to be reviewed and accepted," Dr. Spencer said.

The Seal of Recognition program reflects the academy's efforts "to do everything possible to reduce the incidence of skin cancer on all fronts. Among those fronts is to encourage the use of effective sun protection products. That's the genesis of this effort," he said.

The ongoing debate about the benefits of vitamin D and the call by some clinicians to seek out unprotected exposure to the sun is not helping the Seal of Recognition program from a public relations standpoint, either. "Dermatologists need to be aware that sun

protection has become a controversial issue, specifically because of vitamin D," he said. "Weighing the evidence overall, our advocacy of regular sun protection is still the way to go, and I would encourage our colleagues to continue their advocacy for sun protection."

By accepting application fees from companies that manufacture sun protection products, the Seal of Recognition program "can be misinterpreted as a conflict of interest by the medical or general public," said Dr. Peter C. Lombardo of the department of dermatology at Columbia University, New York. A recent article about professional medical associations and their relationships with industry calls the propriety of endorsing commercial products "highly suspect" (JAMA 2009;301:1367-72).

"My objection is that money is involved in the granting of the seal, and this is where the misconception of the AAD's motives arises," said Dr. Lombardo. "If this were not the case, I would have no objection to [the program]. I believe the AAD is the premier academic institution of America's dermatologists and as such it should be 'like Caesar's wife': above reproach."

Ron Cummings, founder and owner of Newport Beach, Calif.-based AminoGenesis Skin Care, called the Seal of Recognition program a "long-overdue" development. "What made this good is that it was a third-party verification process, extremely documented and very rigorous," he said. "You had to put together a formula that was great, and we were able to do that. Consumers have responded very well, because when they use a product with this AAD seal, they know that it has some level of credibility behind it. It's a certain level of assurance."

The manufacturer must contract with an independent laboratory to test the product in accordance with stringent, evidence-based criteria, including UVA protection, which is not yet required by the Food and Drug Administration. The independent laboratory test results are reviewed by an independent scientist who holds a PhD degree in photobiology and is based in New York City. (The AAD would not disclose the name of this person to ensure that the review of products being considered for the seal remains independent.) That person provides a recommendation about whether the product meets the program's criteria to the AAD's Melanoma/Skin Cancer Committee, which makes the final call on acceptance.

Dr. Spencer disclosed that he is a consultant for L'Oréal, Neutrogena, and IVAX. ■

# Unexplained Changes to The Nail Warrant Biopsy

BY DIANA MAHONEY

BOSTON — The threshold for biopsying unexplained nail dystrophy or discoloration should be low, according to Dr. Phoebe Rich.

Although the majority of nail unit lesions are benign, "malignancies are not as obvious to spot clinically as you would think," and a missed or delayed diagnosis can be life threatening, Dr. Rich said at the American Academy of Dermatology's Academy 2009 meeting.

Any unexplained solitary, painful, dystrophic nail, particularly in an elderly patient, should be biopsied to rule out squamous cell carcinoma of the nail bed.

Any pigmented band of unknown etiology, especially in white patients, requires a biopsy to rule out melanoma, said Dr. Rich of the department of dermatology at Oregon

Health and Science University in Portland. reduced pigmentation, vitamin deficiency fungal infections, and squamous cell carcinoma in situ, she said.

A high index of suspicion for melanoma should exist with lesions that begin under the nail and extend outward onto healthy skin around the nail (Hutchinson's sign); if there is variability in the pigmentation of the band; if the pigmented band is widening or growing; or if there is bleeding or signs of ulceration, Dr. Rich explained. "In these cases, when you have a pigmented band, you have to open it up, look in there, and get a specimen," she said. "It's critical that you biopsy proximally at the matrix, at the origin of the band, because you need the melanocytes. If you biopsy the nail bed distally in an area where the nail plate is involved, you're not going to get the pigment, and you won't get an accurate diagnosis."

Although pigmentary changes can offer a clue to the presence of melanoma, a certain percentage of nail melanomas are amelanotic, said Dr. Rich. Amelanotic melanomas of the nail bed may resemble chronic paronychia or other benign nail conditions, she said.

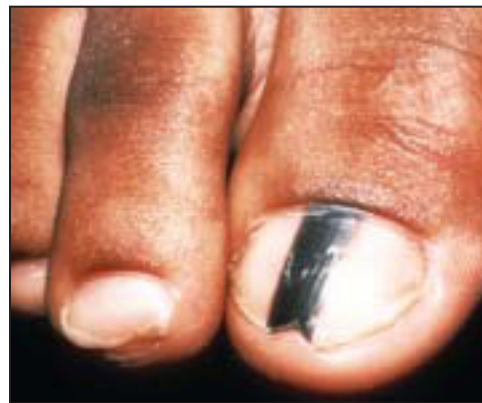For suspected nail melanoma, a nail matrix shave biopsy is sufficient, "unless you suspect advanced melanoma, which is characterized clinically by a dystrophic nail plate in addition to the pigmentation," Dr. Rich said. "In that case, a full thickness biopsy is needed." For large lesions located in the lateral third of the nail, "a longitudinal nail biopsy yields the best information because it samples the nail matrix, nail bed, nail fold, and hyponychium."

Proper preparation of the specimen is also critical to an accurate diagnosis, stressed Dr. Rich, who always orients the specimen on a paper template with a schematic of the nail and fingertip to duplicate its position on the nail unit before dropping it into formalin. "This way, the pathologist knows where the sample comes from," she said.

Because patients are typically apprehensive about nail surgery, the onus is on the clinician to reassure them that it can be done painlessly by using appropriate and effective anesthesia, according to Dr. Rich, who often begins the anesthesia application by having the patient—especially if it is a child—hold a vibrating device. This offers a distraction, she explained, and provides a competing sensation. She then administers an ethyl chloride spray, followed by an injection, via a 30-gauge needle, of lidocaine with epinephrine—which has been proved safe. The addition of bupivacaine or ropivacaine helps to minimize post-operative discomfort.

The anesthesia can be administered using a true digital block, which involves injecting the anesthetic agent into the lateral base of the digit, or through a wing block, whereby the agent is injected into the proximal nail fold. "In my experience, a wing block is quicker, and because it requires a smaller volume of anesthesia, it is safer," said Dr. Rich. "It is also much less painful than a digital block."

Dr. Rich has received advisory board honoraria from Abbott Laboratories and investigator grants from Centocor Inc., Wyeth, and Genentech Inc. ■



Subungual melanoma often presents initially as longitudinal melanonychia.

Health and Science University in Portland.

The presence of certain clinical signs and symptoms can offer clues to the diagnosis of malignant neoplasms. For example, Dr. Rich said, squamous cell carcinoma of the nail may present as longitudinal erythronychia (a pinkish band extending from the nail matrix); as a nodule or tumor with or without nail loss; as a wartlike periungual lesion with nail splitting and skin fissure; or as a draining subungual mass. Because these presentations mimic other clinical entities, "you have to biopsy to get an accurate diagnosis," she said, stressing that nail surgery should not be intimidating. "Any dermatologist who can do a punch biopsy can do a nail biopsy."

For the aforementioned lesions, "you can take a punch or a shave [nail bed] biopsy, and once you have a diagnosis, you can refer the patient for Mohs or, if you feel confident, you can remove it yourself," said Dr. Rich. "We all do skin surgery for squamous cell carcinoma day in and day out. When you remove it, you just have to remember that there is no subcutaneous tissue in the nail, so you are actually removing it at the level just at the periosteum. Check to make sure you have got a nice margin, and you're in good shape."

Subungual melanoma arises from the nail matrix and often presents initially as longitudinal melanonychia, said Dr. Rich. The differential diagnosis for melanonychia is broad, however, and includes benign nevi, lentigo in the nail matrix, genetic and ethnic-type pigmentation, subungual hematoma, drug-in-

### Products Bearing AAD Seal of Recognition

- AminoGenesis Anti-Aging Day Cream with SPF 18
- AminoGenesis Derma Scyne Wrinkle Arrest with SPF 18
- Coolibar Sun Protection Clothing UPF 50+
- Aveeno Continuous Protection Sunblock SPF 55
- Aveeno Baby Continuous Protection Sunblock SPF 55
- Mederma Cream plus SPF 30