

Follow the 'Five Ps' for Smooth Skin Resurfacing

Mnemonic can be used to optimize outcomes and patient satisfaction after skin resurfacing procedures.

BY NANCY MELVILLE
Contributing Writer

ANAHEIM, CALIF. — Ablative laser resurfacing offers perhaps the most effective means for smoothing wrinkles and acne scars, but its success depends on the "five Ps": prepared patients, a good preop evaluation, pain control, a perfectly done procedure, and postop diligence, Suzanne L. Kilmer, M.D., said at a cosmetic dermatology seminar sponsored by the Skin Disease Education Foundation.

Requiring just a single treatment, ablative laser resurfacing removes the epidermis in a first pass, thereby eliminating epidermal lesions and helping to decrease the risk for actinic keratoses and basal cell carcinomas.

To achieve the best possible outcome, however, it's important to pay attention to the details included in the five Ps, said Dr. Kilmer of the department of dermatology at the University of California, Davis.

Prepared Patients

"The consult is critical," Dr. Kilmer said. "Educated patients are going to be much better prepared for what they will be dealing with and will have more realistic expectations."

To help alleviate fear, Dr. Kilmer said she shows patients a video of the procedure (supplied by the manufacturer), along

with typical before-and-after photos—and not just the best cases. "I'll even show my worst," she said. "I'll also show photos to give them an idea of how they can expect to look in a couple of days, a couple of weeks, and as time goes on."

In addition to the informed consent form, patients receive handouts describing the procedure (including preop preparation and postop care) and risk/benefit options.

Preoperative Evaluation

Because hyperpigmentation is one of the most common problems in ablative laser resurfacing, patients' skin type should be checked for that tendency, Dr. Kilmer said.

If patients have acne or other scars, the shallow, dish-shaped scars tend to respond the best, although the treatment significantly improves most acne scars, she said.

Photos of patients should be taken preoperatively and at 1 week, 6 weeks, 3-6 months, and 1 year. Full-face shots as well as close-ups of all anatomical units should be taken with good lighting and consistent settings.

"I can't emphasize enough the need to document with photographs in various stages," Dr. Kilmer said. "It's amazing how often patients won't see much improvement or will say some spot wasn't there and you can look back and show them that it was."

Pain Medications

Dr. Kilmer recommended EMLA with hydration for pain control. Not only does it enhance comfort, she said, but it also enhances safety, with less superficial coagulative thermal damage and less prolonged erythema. Redness has a much shorter duration, and the tendency for hyperpigmentation decreases, she added.

Dr. Kilmer instructs her patients to begin with hot, soapy soaks for 15 minutes at home and then immediately apply the EMLA and cover with a plastic wrap. A second tube is applied when they come to the office.

Patients who have previously had cold sores receive antiviral medications, and they also get antiyeast pills because persistent itching and redness can represent a low-grade yeast infection.

Valium (5-10 mg) and oral nonsteroidals are also given around the clock for the first few days to relieve pain.

Perfectly Done Procedure

Dr. Kilmer said she typically treats in quadrants, with a first pass using slightly higher intensity because the epidermis is so hydrated. Feathering peripherally in the first pass is also important to prevent a stop and start line.

She advises wiping everywhere except the neck, jaw line, and hairline, and giving a lighter treatment to fair or thin-skinned patients, who should never be wiped on the lateral third of the cheek.

Treatment of the neck can have good re-

sults and helps blend the entire treatment area nicely, Dr. Kilmer said, but she emphasized that EMLA should be used for extra protection from thermal damage and the neck should never be wiped.

Postop Diligence

Dr. Kilmer emphasized the need to stay on top of any potential problems, such as contact dermatitis from unexpected sources. "Fabric softening agents and dryer sheets ... tend to have perfume and dyes, which can really be a problem," she said. Use of topical steroids can help in such situations.

If scarring is suspected, treatment should be given right away. A bubbly reaction seen on the skin texture signals a scarring problem, and she advises physicians to consult with others and seek help.

Likewise, treatment of hyperpigmentation cases should be swift, and patients should get zinc oxide right away, with hydroquinones and Retin-A at about a month after treatment.

In the thousands of cases she's done, Dr. Kilmer said she's never seen hyperpigmentation become permanent. EMLA and hydration help provide a greater margin of safety, making ablative laser resurfacing a highly effective tool, she noted.

"There is great efficacy, and you definitely see tightening, so I would say this is the most predictable device we have for resurfacing or regeneration," Dr. Kilmer concluded.

The SDEF and this newspaper are wholly owned subsidiaries of Elsevier. ■

Dermatologic Supplies Abound on Hardware Store Shelves

BY TIMOTHY F. KIRN
Sacramento Bureau

NAPLES, FLA. — The best place to acquire surgical blades and materials for abrading is not necessarily the medical supply house, said Daniel M. Siegel, M.D.

The hardware store has supplies for medical procedures that are usually much cheaper, and often actually work better.

"During medical school, internship, and

residency, I used to think about gadgets I grew up with that could be used in the medical office," explained the dermatologist and son of a hardware store owner.

The old double-edged razor blade is a case in point of the hardware store item being both cheaper and better, Dr. Siegel said. The classic blade is the old Gillette Blue Blade. Those blades are much sharper and much thinner (4/10,000th of an inch) than a scalpel, said Dr. Siegel of

State University of New York Downstate Medical Center, New York.

Their thinness makes them easier to handle, and they can be bent and bowed to curettage (but practice on an orange first). Their sharpness allows the user to cut more cleanly with less collateral damage. This has even been touted in the literature, Dr. Siegel said, citing a paper that said one can perform excision biopsies of melanocytic nevi with less scarring. "Only a diamond knife is sharper."

The thicker, carpet-cutting blades sold in the hardware store are ideal for harvesting split thickness skin grafts because of their stiffness. The razor blades sometimes are covered with anticorrosive oil that is bacteriostatic, but the carpet blades need to be cleaned with Betadine and alcohol, he said.

Sandpaper, sanding sponges, and even drywall screens can be handy for—what else?—abrading, Dr. Siegel said. Sandpaper, which he makes wet with Betadine, can be used on warts, small scars, and even onychomycotic nails. The sponges are handy because they can be used and then washed in a dishwasher or washing machine. Drywall screen can be quite rough but it works well for treating larger areas, hypertrophic scars, or actinic keratoses, because it can be rinsed during use.

Dr. Siegel even suggested that sandpaper could be used for cosmetic dermabrasion, perhaps to advantage.

"It clogs quickly, so you have to use a lot

of it," he said. "But it is difficult to do any real harm because it is a slow-moving, not very aggressive abradant."

For microdermabrasion, he suggested using Lava soap, which contains pumice from volcanic lava. Lava soap can be used before phototherapy or a peel, to remove some of the stratum corneum.

Dr. Siegel said he has made his own silicone gel sheeting using silicone caulking. He spreads it between two sheets of wax paper or into a plastic bag to flatten it out, and then lets it dry overnight.

As with all the hardware items, the cost of this sheeting is much less than the medical-grade sheeting, Dr. Siegel stressed. In fact, the first time he used the caulking was specifically for a patient who needed an economic alternative.

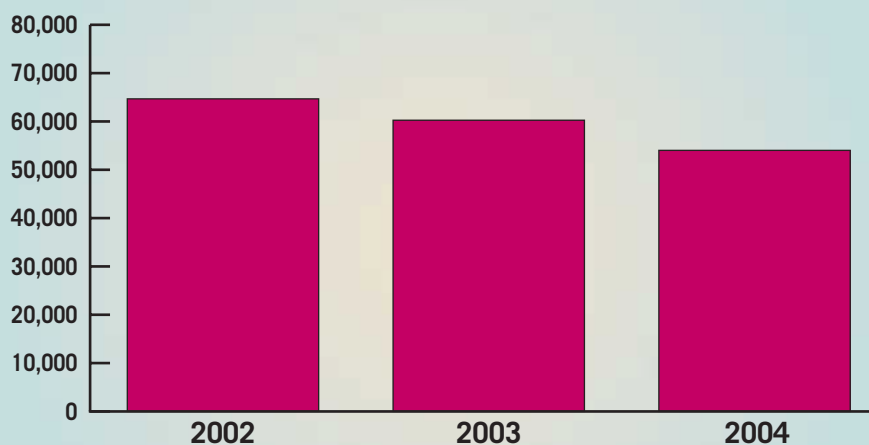
Among the other items available at the hardware store that Dr. Siegel mentioned using were electrical tape (to put over imiquimod), duct tape (on warts), foam tapes (to protect areas during cryotherapy), headlamps (only about \$20), and dimethyl sulfoxide (DMSO).

DMSO can be bought in many hardware stores. He mixes it with 50% water then adds whatever medication he wants to have better penetration, such as fluconazole (Diflucan). He even suggested that someone might want to try adding it to ciclopirox (Penlac) for infected nails.

"You may actually get something that works," he said. ■

DATA WATCH

Dermabrasion Procedures Declining



Note: Based on estimated data.
Source: American Society of Plastic Surgeons