

Rapid Repeat Pregnancy Risk Persists As Teens Fail to Use Prescribed ECPs

BY DIANA MAHONEY
New England Bureau

ATLANTA — Advanced provision of emergency contraceptive pills did not significantly decrease the rapid repeat pregnancy rate in a racially and ethnically diverse group of adolescents enrolled in a Colorado study “because many of the young women failed to use them,” Jeanelle Sheeder reported at the annual meeting of the North American Society for Pediatric and Adolescent Gynecology.

To better understand why emergency contraceptive pills (ECPs) have not had the anticipated impact on teen pregnancy, Ms. Sheeder and colleagues in the department of pediatrics at the University of Colorado Health Sciences Center in Denver assessed the sexual and contraceptive behavior of 382 predominantly primiparous 14- to 21-year-old women in that institution’s adolescent maternity program. At the time of enrollment, all of the young women expressed a desire not to get pregnant again for at least 2 years and understood the necessity of using abstinence or effective contraceptives to do so.

Additionally, each participant received either a prescription for or a packet of ECPs, with no limit on refills, Ms. Sheeder said.

At each clinic visit, conducted at 6- to 8-week intervals through the sixth postpartum month, the study participants completed a questionnaire that asked about their interval sexual and contraceptive behavior, Ms. Sheeder said.

The outcome measures for the study were episodes of unprotected intercourse, ECP use, a composite index for group pregnancy risk computed by summing the products of the method-specific failure rates and the proportion of sexually active teenagers using each method, and unwanted conception, she reported.

Controlling for age, race/ethnicity, education level, reason for not using contraception before conception, future family plans, and postpartum month, the investigators also analyzed the use of ECP in relation to unprotected intercourse, whereby a 1:1 ratio was considered appropriate ECP use. A ratio of less than 1:1 was deemed underuse and a ratio greater than 1:1 was considered augmented use, she said.

During the course of the study, 44% of the young mothers had episodes of unprotected intercourse, said Ms. Sheeder, noting that “of these women, 15% reported one episode of unprotected intercourse, 24% had two to four episodes, and 5% had more than four episodes.”

While more than half (54%) of the women reporting unprotected intercourse used ECPs, only 28% used them appropriately, Ms. Sheeder noted. “They were underutilized by 65% of the women and 7% engaged in augmented use,” she said.

The prevalence of unprotected intercourse and ECP use did not vary significantly in relation to age, race/ethnicity, education level and participation, reason for not using contraception before conception, future family plans, or postpartum month, Ms. Sheeder reported.

The group pregnancy risk did not change during the study period, she said.

A total of 19 pregnancies occurred during the study period. “Teens who experienced unwanted pregnancies did not engage in more unprotected intercourse or ECP underuse than those who did not,” Ms. Sheeder noted.

Of the 19 pregnancies, 9 were in young women who reported using some contraceptive method during the study period but their contraceptive use was inconsistent or incorrect, said Ms. Sheeder. The remaining 10 pregnancies were not attributable to unrecognized contraceptive or ECP failure, she said. ■

Screen the Patient’s Family in Recurrent Vulvovaginal Strep

Management of patients with recurrent Group A β -hemolytic streptococcal infections should include screening the patient’s family and intimate contacts in order to identify and treat bacterial carriers, according to Dr. Jack Sobel and his colleagues.

Dr. Sobel of Wayne State University School of Medicine, Detroit, and his associates described two cases of recurrent vulvovaginal infections in adult women caused by Group A β -hemolytic streptococcus (GAS), a pathogenic organism. GAS vulvovaginitis has rarely been reported in adult women. GAS colonization can occur in the vagina, but is more likely in the nasopharynx, perineum, anus, and skin, the investigators wrote (*Clin. Infect. Dis.* 2007;44:43-5).

Both women reported a history of recurrent episodes of vulvovaginal *Streptococcus pyogenes* infections presenting with pruritus, vaginal discharge, and erythema. The infections resolved after antibacterial therapy but recurred in a short time.

Screening of the patients’ families showed that the husbands were gastrointestinal/perianal carriers of *S. pyogenes*. For each couple, bacterial typing showed the index strain and carrier strain to be identical.

Reinfection was hypothesized to occur through sexual transmission or contamination of the sheets and mattress from perianal shedding of *S. pyogenes*.

Antibacterial treatment was given to the women and their male partners. Following eradication of bacterial carriage in the male partner, vaginitis recurrence was finally resolved.

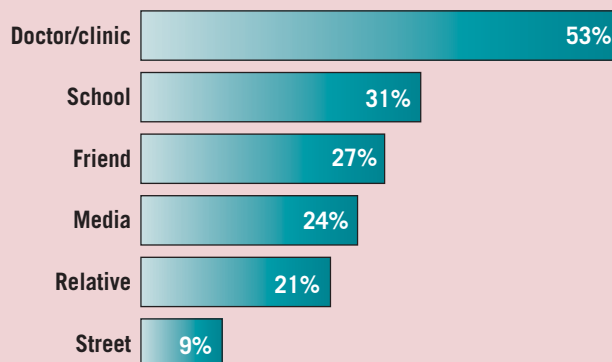
“Carriage or exposure to a carrier is an important pathogenic factor in recurrent GAS infection, although it is often ignored,” wrote the study authors.

They reported no conflicts of interest.

—Barbara Rutledge

DATA WATCH

Where Teenage Girls Are Getting Emergency Contraception Information



Note: Based on a 2005-2006 survey of 91 girls aged 13-19 years.
Source: Dr. Mandy S. Coles

ELSEVIER GLOBAL MEDICAL NEWS

Consider Complex Aphthosis in Young Girls’ Vulvar Ulcers

BY MICHELE G. SULLIVAN
Mid-Atlantic Bureau

HOT SPRINGS, VA. — Complex aphthosis may be the cause of noninfectious vulvar ulcers in young females, Dr. Judith Burgis said at the annual meeting of the South Atlantic Association of Obstetricians and Gynecologists.

“When we see vulvar ulcers in these girls, especially after their sexual debut, we tend to immediately think of an infectious etiology like herpes simplex,” said Dr. Burgis, of the department of ob.gyn. at the University of South Carolina, Columbia.

“But the differential diagnosis for these types of lesions is actually quite diverse,” she said.

Dr. Burgis presented a case series of 12 girls, aged 6-16 years, with vulvar ulcers; 11 of the girls were premenarcheal and sexually

naive. The one postmenarcheal patient was sexually active. All 12 of the patients had been referred by their pediatricians for management of the ulcers, and many had been told that they had a herpes simplex infection. “This is a very



Since we found no common pathogen and no sign of systemic illness, we diagnosed complex aphthosis.

DR. BURGIS

anxiety-provoking diagnosis for both the girl and her parents.”

None of the ulcers was positive for viral, bacterial, or fungal pathogens.

Two girls, both of whom had recurrent oral and genital ulcers, were referred for a rheumatology

evaluation with a presumed diagnosis of Behçet’s disease.

The ulcers in three other patients had identifiable etiology. An 11-year-old with a several-month history of severe itching and a periclitoral ulcer unresponsive to topical yeast medication had lichen simplex. The large ulcer on a 6-year-old was related to chemotherapy for acute lymphocytic leukemia. Another 11-year-old had myelodysplasia and sacral agenesis; her ulcers were related to incontinence

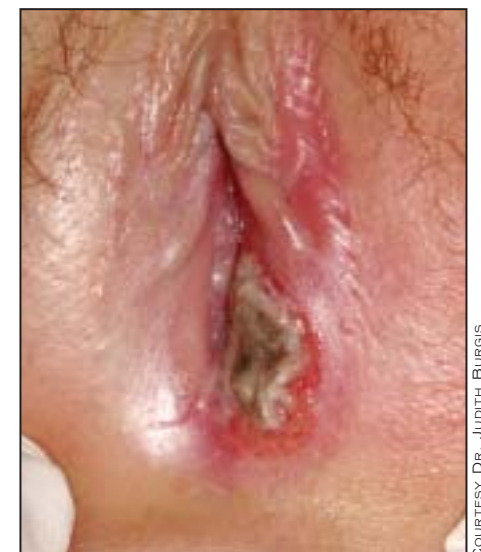and diaper use. But the final seven cases had no readily identifiable cause, Dr. Burgis said. Six of these girls were premenarcheal; one was postmenarcheal. Epstein-Barr serology and testing for infections were negative in all of

them. There were no reasons to suspect trauma or sexual abuse in any patient, and all other laboratory testing was unrevealing. None of the girls had inflammatory bowel disease or Crohn’s disease, both of which can cause vulvar ulcers.

“Since we found no common pathogen and no sign of systemic illness, we concluded the diagnosis was probably complex aphthosis,” Dr. Burgis said. “The etiology is unknown; it may be primary or may be secondary due to a systemic illness, perhaps of viral etiology.”

All these girls had an unremarkable course of recovery over 1-3 weeks, Dr. Burgis said. They were treated with su-

perpotent topical corticosteroids, clobetasol ointment, and 2% topical Xylocaine for pain. Those with an accompanying cellulitis also received antibiotics. ■



None of the ulcers was positive for viral, bacterial, or fungal pathogens.

COURTESY DR. JUDITH BURGIS