

Blood-Lead Threshold for Kids May Be Too High

BY MITCHEL L. ZOLER
Philadelphia Bureau

PHILADELPHIA — Although the Centers for Disease Control and Prevention set a blood lead level of 10 mcg/dL or higher as the threshold for concern in children in 1991 and reaffirmed it in 2005, many experts agree that levels below that also are dangerous.

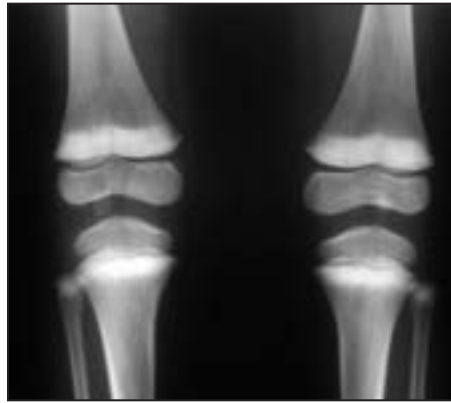
"Kids have adverse effects at levels below 10 mcg/dL, but it's hard to pinpoint a specific level where you can say that adverse effects stop," Dr. Carla Campbell said at a conference sponsored by the Mid-Atlantic Center for Children's Health and the Environment.

"But the lower you get below 10 mcg/dL, the more error you have, [and] the more likely children are to be misclassified," which led to retention of the 10 mcg/dL cutoff, said Dr. Campbell, a specialist in pediatric environmental and public health at Drexel University, Philadelphia, who chaired the CDC's advisory committee that produced the agency's 2005 report.

In November 2007, a new report by the same group, the CDC's Advisory Committee on Childhood Lead Poisoning Pre-

vention, recommended that blood lead testing be done on all children, and that for a child whose level "is approaching 10 mcg/dL, more frequent blood screening (more than annually) might be appropriate, particularly if the child is aged less than 2 years old, was tested at the start of warm weather when blood lead levels tend to increase, or is at high risk for lead exposures" (MMWR 2007;56[RR-8]:1-14).

A review published last May was more



An x-ray of both knees of a child with lead poisoning shows dense metaphyseal bands involving distal femurs, proximal tibias, and proximal fibulas.

explicit: The level of 10 mcg/dL "has no special biological significance and certainly should not be interpreted as safe," wrote David C. Bellinger, Ph.D., a professor of neurology at Harvard University, Boston (PLoS Med. 2008;5:e115).

The growing concern about levels below 10 mcg/dL led to a novel lead-control program in Washington. The nonprofit Lead Safe D.C. program, sponsored by the National Nursing Centers Consortium, launched a program aimed at reaching every child in the District of Columbia with a blood lead level of 5 mcg/dL or higher, Harrison Newton said at the meeting. Young children with high blood lead levels are identified in the District through a municipal mandate that requires all children to get tested for blood lead at least twice before they're 2 years old.

Once affected children are identified, their homes are visited by community outreach workers who encourage families to take steps to reduce the lead hazard. Cleaning kits are distributed to the families, said Mr. Newton, program director for Lead Safe D.C.

Blood lead levels in U.S. children began to plummet starting in 1978 when lead

paint was discontinued. This was followed by the elimination of lead-containing solder in food cans and the phasing out of leaded gasoline. According to the CDC's 2007 report, 1.6% of children aged 1-5 years had blood lead levels of 10 mcg/dL or higher in 1999-2002, and the average level in all children this age was 1.9 mcg/dL. In contrast, during 1976-1980, about 88% of children this age had blood lead levels at or above 10 mcg/dL, and the mean level was 15 mcg/dL.

The major current sources of lead poisoning in children are paint chips and dust in housing that retains old leaded paint, and in water that passes through old pipes, Jianhong Liu, Ph.D. said. These sources mean that substantial disparities in lead exposure exist in the United States, with the highest levels seen in children who live in old housing.

For example, in 2005 the average blood lead level among all U.S. children aged 5 years and under was about 2 mcg/dL, but it was about 6 mcg/dL for children in Chicago and 14 mcg/dL for children in Philadelphia, said Dr. Liu, of the Center for Public Health Initiatives at the University of Pennsylvania, Philadelphia. ■

Follow-Up MRI in Kids With Suspected Osteomyelitis Has Value

BY DIANA MAHONEY
New England Bureau

Residual soft tissue and bone edema associated with diagnostic or surgical intervention for suspected osteomyelitis or septic arthritis do not diminish the value of subsequent magnetic resonance imaging in children with persistent signs of infection, a study has shown.

The issue under investigation was whether iatrogenic injury to soft tissue or marrow before an MRI study interferes with the clinician's ability to exclude infection or diagnose alternative causes for symptoms that remain despite a negative result after intervention.

Dr. J. Herman Kan of Vanderbilt Children's Hospital, Nashville, Tenn., and his colleagues conducted a retrospective case-control study using data from patients who underwent emergent contrast-enhanced MRI examinations that were performed for suspected osteomyelitis or septic arthritis at the hospital from March 2002 through September 2007.

Of the initial 136 MRI examinations, the analysis included only the 34 performed within 10 days after an initial diagnostic or surgical intervention, such as joint, marrow, or soft-tissue aspiration; arthrotomy; or incision and drainage of bone or soft tissue. The study control group consisted of 96 patients who underwent MRI for suspected osteomyelitis or septic arthritis during the same period but who did not have a prior intervention.

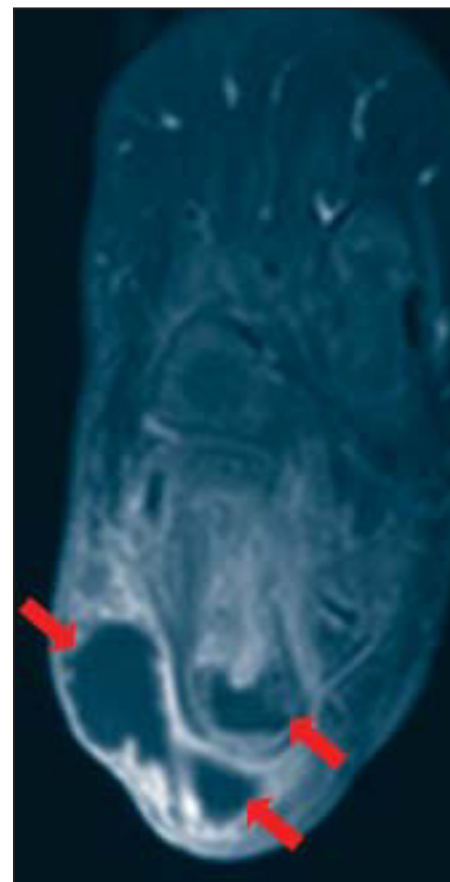Pediatric radiologists with additional training in pediatric musculoskeletal radiology performed consensus reviews of the images to assess whether objective MRI criteria could still be applied to those patients who had undergone recent intervention.

They also evaluated the presence or absence of specific MRI features of osteomyelitis that could neither be attributed to the recent intervention nor were suggestive of a noninfectious alternative diagnosis. Such features included intraosseous abscess, cortical breach, subperiosteal abscess, and soft-tissue or bone edema, the authors wrote in the November 2008 issue of the *American Journal of Roentgenology*.

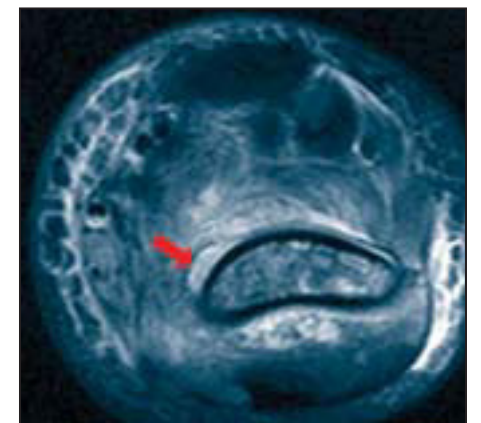
The reviewing radiologists had knowledge of the location of the prior intervention and the final discharge diagnosis, they noted (*Am. J. Roentgenol.* 2008;191:1595-600).

In 10 of the 34 study group patients (29%), the MRI findings led to a need for additional intervention, which was similar to the control group, in which the MRI findings pointed to further intervention for 26 of the 96 control group patients (27%), the authors reported. The groups did not differ significantly in the number of patients with a final diagnosis of osteomyelitis, osteomyelitis or septic arthritis, cellulitis or pyomyositis, and noninfectious conditions, they stated.

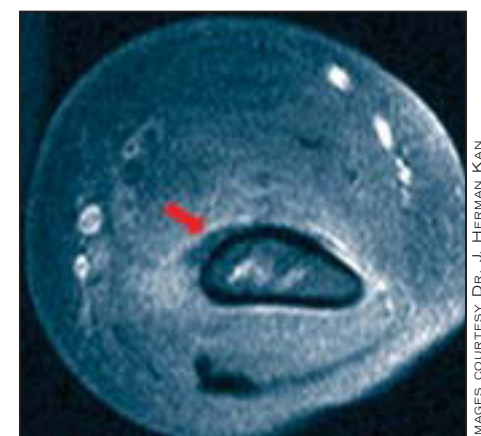A total of nine patients had a final diagnosis of osteomyelitis, and "objective MRI criteria were present in all nine patients," the authors wrote, while none of the remaining 25 patients had characteristic imaging features of osteomyelitis. Among the patients with an osteomyelitis diagnosis, "eight of nine had one or more imaging criteria of osteomyelitis, including intraosseous abscess, cortical breach, or subperiosteal abscess," they said. The ninth subject was diagnosed with acetabular osteomyelitis based on evidence of marrow and soft-tissue edema in the obturator internus muscle, away from the intervention site.



Right foot after IV administration of gadolinium shows large soft-tissue abscess (arrows) and intraosseous calcaneal abscess (arrowhead).



T2-weighted humerus, intramedullary, and subperiosteal abscess (arrows).



Corresponding T1-weighted image of the distal humerus, shown above.

The findings suggest that musculoskeletal MRI "plays an important role in the management of these patients because of its ability to evaluate underlying osteomyelitis despite recent intervention," according to the authors. With correct clinical and surgical history, they wrote, "patterns of soft-tissue and marrow edema can be explained."

Though intervention-related iatrogenic changes do not affect MRI's diagnostic efficacy in suspected osteomyelitis or septic arthritis, "MRI before intervention adds efficacy to patient management, guides the surgical procedure, and prevents additional surgery in children with suspected pelvic or appendicular osteomyelitis or septic arthritis," the authors concluded. ■