

IMRT Fails to Aid Survival in Cervical Ca Patients

BY JANE SALODOF MACNEIL
Senior Editor

GÖTEBORG, SWEDEN — Eliminating nodal disease in cervical cancer patients with positive pelvic and para-aortic positive lymph nodes failed to improve survival in a prospective 24-patient phase II study.

The results were presented at the annual meeting of the European Society for Therapeutic Radiology and Oncology.

Investigators at the Mallinckrodt Institute of Radiology in St. Louis used positron-emission tomography (PET) to guide 60 Gy of intensity-modulated radiation therapy (IMRT) to pelvic and para-aortic lymph nodes where metastases had been detected by PET with fluorodeoxyglucose (FDG).

Three months after radiotherapy, 21 patients were screened again by FDG-PET, a timetable the lead investigator, Dr. Perry W. Grigsby, had previously reported to be predictive of survival (JAMA 2007; 298:2289-95). Nineteen patients (90%) had negative lymph nodes at this point, suggesting radiotherapy had been successful.

Six of the 19 patients—nearly a third—already had new metastases in other locations, however. By 40 months, nearly all had progressed. Cause-specific survival at that point was about 50%, said Dr. Grigsby, professor of radiation oncology, nuclear medicine, and gynecologic oncology

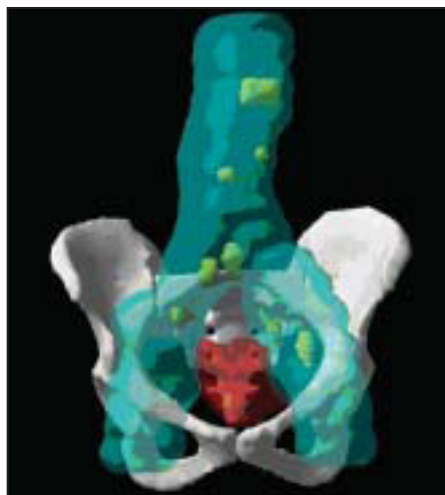at Washington University, St. Louis.

“Some of these patients have been treated for their recurrences, and will live a few months longer,” he observed.

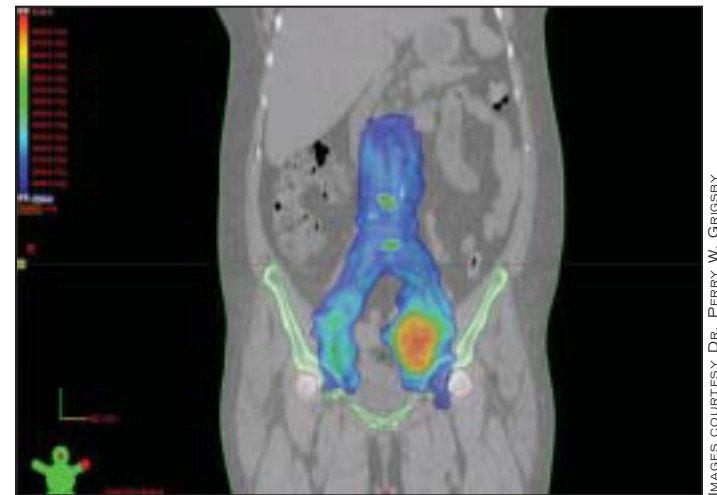
The 5-year survival rate for cervical cancer with positive lymph nodes is only about 30%, according to Dr. Grigsby. Efforts to deliver more radiotherapy to positive lymph nodes have so far resulted in high toxicity with no improvement in survival.

For the current study, patients had to have positive nodes with no other sites of metastases when enrolled. Half of the 24 patients had stage IIIb disease; nine had stage IIb disease, and three cases were stage Ib2. The majority, 20 patients, had squamous cell histology; 2 patients had adenocarcinoma, and 1 each were classified with clear cell or small cell cervical cancer.

The protocol delivered a clinical target volume-nodal of 50 Gy over 30 fractions to the pelvis and para-aortic lymph node regions, along with a molecular target



Positive lymph nodes are shown in green on the FDG-PET scan.



In one dose-distribution plan, the blue areas receive 50 Gy of radiation and the positive lymph nodes (orange) receive 60 Gy.

volume-nodal of 60 Gy directed at the FDG-PET-positive lymph nodes in these areas. In addition, the women were treated with six cycles of brachytherapy (6.5-Gy high dose rate) and weekly cisplatin (40 mg/m²).

The median treatment time was reported as 53 days, with a median follow-up of 22 months.

Acute toxicity was high, with 58% of patients having grade 3 adverse events, 33% with grade 4, and one patient dying of a chemotherapy-related adverse event. Late toxicity occurred in 13% of patients: two with small bowel obstructions and one with proctitis.

The results show that delivering 60 Gy of PET-guided IMRT to pelvic and para-aortic lymph nodes along with concurrent chemotherapy is feasible and eliminates nodal disease in most patients, Dr. Grigsby said.

Nonetheless, he found survival remains poor due to development of distant metastases.

“These patients are at exceptionally high risk of dying from metastatic disease, and we need to search out improved systemic agents in order to cure this patient population,” he concluded.

Dr. Grigsby stated that he had no conflicts of interest to disclose. ■

Avoid Empiric Steroid Treatment for Vulvar Skin Disorders

BY NANCY WALSH
New York Bureau

LAKE BUENA VISTA, FLA. — Empiric treatment with corticosteroids should be avoided in patients who present with vulvar symptoms such as burning, itching, pain, and dyspareunia, according to one researcher who specializes in the subject area.

These patients should have a careful examination of the vulva using a colposcope, and if a lesion is present, a 4-mm punch biopsy is warranted.

When the biopsy specimen is sent to the dermatopathologist, it's important to provide clinical correlates and a differential diagnosis or the result is likely to be simply descriptive—acanthosis, hyperkeratosis, chronic inflammation—rather than diagnostic, Dr. Andrew T. Goldstein said at the annual meeting of the International Pelvic Pain Society.

And be sure patients understand that all lichens are not created equal, and they need to know the full name of their disorder, whether lichen sclerosus, lichen simplex chronicus, or erosive lichen planus.

Lichen Sclerosus

Lichen sclerosus typically presents with itching, burning, dyspareunia, and skin texture changes often described as “cigarette paper” skin, with crinkling and fissures around the vulva and anus. Hypopigmentation also is characteristic, with scarring and architectural changes including phimosis of the clitoris, resorption of the labia minora, and narrowing of the introitus causing recurrent tearing.

This condition probably is autoimmune, he said, with a proliferation of monoclonal T cells in the dermis and high levels of circulating autoantibodies. Patients with lichen sclerosus also have a high incidence of other autoimmune diseases, especially thyroid disease.

Lichen sclerosus can develop at any age, including

childhood, and is more common than generally appreciated, with a prevalence of 1 in 70 women. “As a busy gynecologist you may be seeing lichen sclerosus once or twice a week, but only diagnosing it once or twice a year,” he said. “You have to look for it. The vulva is not just something to separate with a speculum when you do a Pap smear. It has been termed the forgotten pelvic organ.”

Punch biopsy performed before initiating treatment may show hyperkeratosis of the epidermis, epidermal atrophy with loss of rete ridges, homogenization of the collagen in the upper dermis, and a lichenoid inflammatory infiltrate in the dermis. Identifying this condition is critical, as patients with lichen sclerosus have a relative risk of 300 for developing squamous cell carcinoma of the vulva, said Dr. Goldstein of George Washington University Hospital, Washington.

Treatment of lichen sclerosus is clobetasol 0.05% ointment once daily after soaking. “I believe the Temovate brand is much better than the generic, probably because of the vehicle,” he said. The corticosteroid should be continued until active disease has resolved, not just for the 2 weeks specified in the package insert, and then the frequency and potency can be reduced.

Testosterone propionate should not be used. “If a patient with lichen sclerosus develops squamous cell carcinoma and was treated with testosterone, I’ll be more than happy to testify for the plaintiff because 17 years ago it was shown to be no better than placebo,” he said.

Lichen Simplex Chronicus

A second vulvar condition, lichen simplex chronicus, is characterized by thick, lichenified skin of the labia majora and interlabial sulcus, accompanied by erosions, fissuring, and tears in the skin that result from the patient’s scratching in her sleep, said Dr. Goldstein.

This condition represents the end stage of mast-cell and histamine-mediated itch-scratch-itch cycle in predisposed

patients that can be initiated by irritants, allergens, or infections.

All irritants such as soaps, detergents, and douches must be stopped, and underwear must be washed by hand in plain hot water. Daily warm-water sitz baths should be followed by application of a high-potency topical corticosteroid, which must be rubbed into the skin for 3-4 minutes.

Breaking the nocturnal itch-scratch cycle can be accomplished by bedtime amitriptyline, 10-50 mg, and the application of a bag of frozen peas to the vulvar area during the night.

An investigational alternative to topical corticosteroids is topical pimecrolimus, which is not associated with dermal atrophy. This agent showed promise in an open-label preliminary trial that included 12 women aged 25-53 years, according to Dr. Goldstein, who was the lead investigator and who disclosed that he has received grants and research support from Novartis, the manufacturer of pimecrolimus.

In this study, patients applied pimecrolimus cream 1% twice daily. Median pruritus scores decreased at weeks 4, 8, and 12, and seven patients reported complete resolution of pruritus by week 4 (Gynecol. Obstet. Invest. 2007;64:180-6).

Erosive Lichen Planus

A third vulvar disorder to watch for is erosive lichen planus, which is associated with burning and severe dyspareunia and is characterized by red plaques with white “lacy” edges (Wickham’s striae). Vulvar and vaginal lesions also can be accompanied by lesions of the oral mucosa.

This condition can be somewhat more difficult to treat, starting with topical corticosteroids or macrolide immunosuppressants, but oral agents such as steroids, retinoids, and other immunosuppressants also are often required. Vaginal dilators also are essential, to prevent scarring that can occur within a matter of weeks, he said. ■