

# Imaging Breakthroughs Reveal Early AD Changes

BY KERRI WACHTER  
Senior Writer

WASHINGTON — Imaging techniques designed to enable identification of preclinical Alzheimer's disease were showcased in numerous presentations at an international conference sponsored by the Alzheimer's Association.

## Preclinical Biochemical Changes

Using magnetic resonance spectroscopy (MRS), researchers in the United Kingdom identified biochemical changes in the posterior cingulate in a group of symptom-free subjects genetically destined to develop Alzheimer's disease (AD).

The researchers imaged seven volunteers with familial AD, who carry presenilin 1 and amyloid precursor protein gene mutations and have an almost 100% chance of developing AD, according to Alison Godbolt, M.B., of the Dementia Research Centre at University College, London.

At the time of the study, these individuals had normal memory. Six healthy volunteers without familial AD were also recruited to serve as controls.

MRS provides information about select chemicals in a specific area of the brain that are involved in metabolism. MRS is performed using the same scanners as magnetic resonance imaging (MRI) and takes about 45 minutes.

The researchers looked at a single voxel along the midline of the posterior cingulate, a region that is known to be involved in AD. They measured the ratio of n-acetylaspartate to creatine and the ratio of *myo*-inositol to creatine.

Subjects with the genetic mutation had n-acetylaspartate/creatinine ratios that were 10% lower and *myo*-inositol/creatinine ratios that were 20% greater than those of the control group. The difference in the *myo*-inositol/creatinine ratios between the two groups did not reach statistical significance. "Interestingly, other researchers have found the same changes in people who already have the disease," Dr. Godbolt said.

Reduced levels of n-acetylaspartate are thought to be due to nerve cell dysfunction and loss; increased *myo*-inositol levels are thought to be due to increased inflammation. In addition, the volunteers with the gene mutation who were closest to their predicted age of onset had the most abnormal levels of these two chem-

icals, "suggesting a gradual buildup of changes over the several years before symptoms begin," she said.

## Screening via Hippocampal Size

Reduced hippocampal volume on MRI, combined with the results of the Mini Mental State Examination (MMSE), appears to do a better job of identifying patients with mild cognitive impairment (MCI) and AD than MMSE alone, according to a poster presented by Claire K. Sandstrom, who is a medical student at Duke University in Durham, N.C., and her colleagues.

Several recent studies have shown that individuals with MCI have smaller hippocampal volumes on MRI, compared with healthy controls. This is especially true for those subgroups of individuals with MCI, who later convert to AD.

The researchers evaluated 18 volunteers (11 men) with MCI and 17 volunteers (8 men) with normal cognition with the MMSE and MRI. Those with MCI were age 74 years on average and had a mean MMSE score of 27, while the control group was age 70 years on average and had a mean score of 28, Ms. Sandstrom told this newspaper.

Hippocampal atrophy was greater in the volunteers with MCI than in the controls. Left hippocampal volume was significantly smaller than on the right only in people with MCI.

The researchers developed receiver operating characteristic curves to evaluate the ability of left hippocampal volume, right hippocampal volume, MMSE score, and the combination of left hippocampal volume and MMSE score to accurately identify patients with AD and MCI. After analyzing these curves, the researchers concluded that left hippocampal volume was superior to MMSE alone in identifying patients with AD and MCI. "Left hippocampal volume added significantly to the discriminatory capacity of the MMSE scores for differentiating between cognitively normal individuals and those with MCI," the authors wrote.

## DTI Reveals Brain Changes in MCI

Researchers have identified changes in the left and right anterior hippocampus and amygdala in patients with MCI and in those with mild cognitive complaints but not in cognitively normal subjects, using diffusion-tensor imaging (DTI).

The researchers imaged 27 individuals

with MCI (mean age 74 years), 25 individuals with cognitive complaints (mean age 73 years), and 33 healthy controls (mean age 72 years), according to a poster presented by John D. West of the Brain Imaging Lab at Dartmouth College in Hanover, N.H., and his colleagues.

The participants were drawn from the ongoing Dartmouth Memory and Aging Study. The groups were balanced for age, education, and sex. They also were assessed using the California Verbal Learning Test.

DTI reveals disruptions of the white matter tracts that are not visible on MRI. Within white matter, water moves parallel to tracts. Conventional MRI can distinguish white from gray matter but can provide very little detail about the white matter; MRI cannot observe or quantify specific fiber tract directions.

DTI relies on the principle that water diffusion is affected by the properties of the medium in which it occurs. Diffusion within biologic tissues reflects tissue structure and architecture at the microscopic level.

In particular, the researchers looked at the ability of water to diffuse in different regions of the brain. The greater the diffusion, also known as trace diffusivity, the less white matter structure there is to limit movement—an indication of white matter degeneration.

An area of increased trace diffusivity—relative to the control group—was found in the right posterior cingulate of both the MCI group and the group with lesser cognitive complaints. The participants with MCI also showed increased trace diffusivity in medial temporal regions relative to the control group.

Relative to controls, patients with MCI were more likely to have increased trace diffusivity in the left and right anterior hippocampus and amygdala. Cerebral water diffusion in the group with lesser cognitive complaints was less than in those with MCI and greater than cognitively normal controls.

Dr. West and his associates correlated trace diffusivity with performance. They found that decreasing verbal scores on the California Verbal Learning Test correlated with increasing trace diffusivity in the left and right anterior hippocampus and amygdala.

The findings suggest that DTI could be sensitive to preclinical changes in regions of the brain associated with AD.

## AD vs. Lewy Body Dementia on PET

PET imaging shows that patients with dementia with Lewy bodies (DLB) have slightly more  $\beta$ -amyloid in the occipital and sensorimotor cortex than do patients with AD, a finding that may help physicians distinguish the two conditions with similar symptoms, according to a poster that was presented by Victor L. Villemagne, M.D., of Austin Hospital in Melbourne, Australia.

The researchers took advantage of a relatively new PET tracer—the Pittsburgh Compound-B (PIB)—to image  $\beta$ -amyloid in the brain. PIB is a derivative of thiamine that is labeled with radioactive carbon and attaches to  $\beta$ -amyloid deposits in the brain that show up on PET imaging.

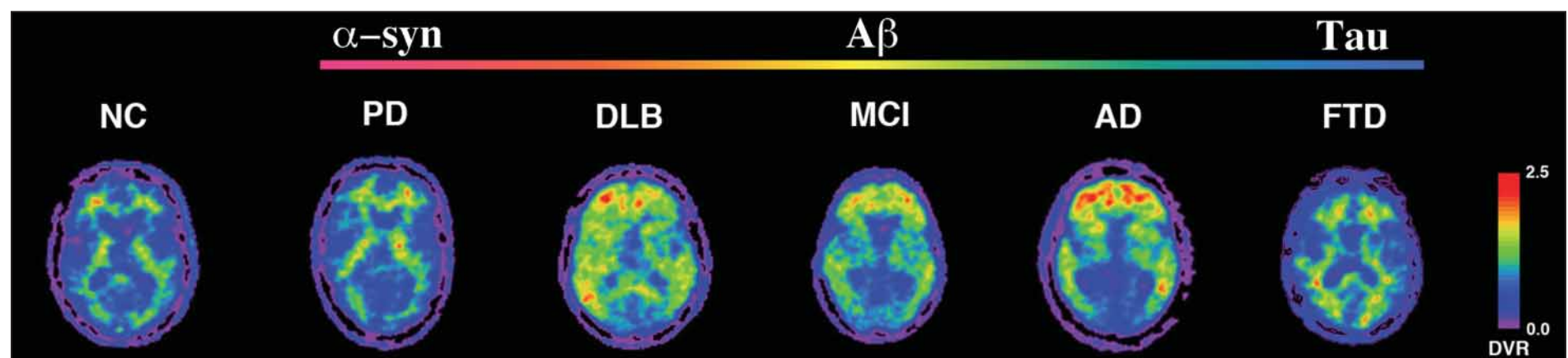
The researchers imaged eight patients with AD, seven patients with DLB, and seven age-matched healthy controls using PIB PET and  $^{18}$ fluorodeoxyglucose (FDG) PET. Patients with AD had MMSE scores ranging from 15 to 28. Patients with DLB had MMSE scores ranging from 10 to 25, persistent visual hallucinations, parkinsonism, and cognitive fluctuations. The control group had MMSE scores greater than 27.

PIB PET images of the patients with AD showed marked binding in the frontal, parietal, and lateral temporal cortices, as well as the caudate nuclei, suggesting that there were significant  $\beta$ -amyloid deposits there. There was relative sparing of the occipital and sensorimotor cortex and very low uptake in the cerebellar cortex. Patients with DLB appeared similar to those with AD but slightly higher uptake was noted in the occipital and sensorimotor cortex.

The normal control group showed little or no PIB retention in any cortical and subcortical gray matter areas. Areas of PIB binding were inversely correlated with areas of FDG uptake—a measure of brain activity.

The use of PIB binding patterns can distinguish DLB from AD, said Dr. Villemagne, also of the department of pathology at the University of Melbourne, in an interview.

DLB is the second most common cause of dementia after AD, and it is difficult to distinguish the two disorders. Postmortem studies of DLB have shown that the majority of patients have cortical  $\beta$ -amyloid deposits similar to those found in patients with AD. ■



PET shows PIB retention in white matter in normal control, Parkinson's disease, and frontotemporal dementia (FTD), in a clearly different pattern from Lewy body dementia (DLB), mild cognitive impairment, or Alzheimer's disease, with PIB retention in the frontal and temporal cortices. PIB retention in the occipital cortex was high in DLB.