

Subclinical Brain Lesions in Migraine Mimic MS

BY DEBBIE LERMAN
Contributing Writer

PHILADELPHIA — Migraine patients have an increased risk for subclinical brain lesions that sometimes resemble lesions found in patients with multiple sclerosis or cerebral autosomal dominant arteriopathy with subcortical infarcts and leukoencephalopathy, according to a population-based MRI study conducted in the Netherlands.

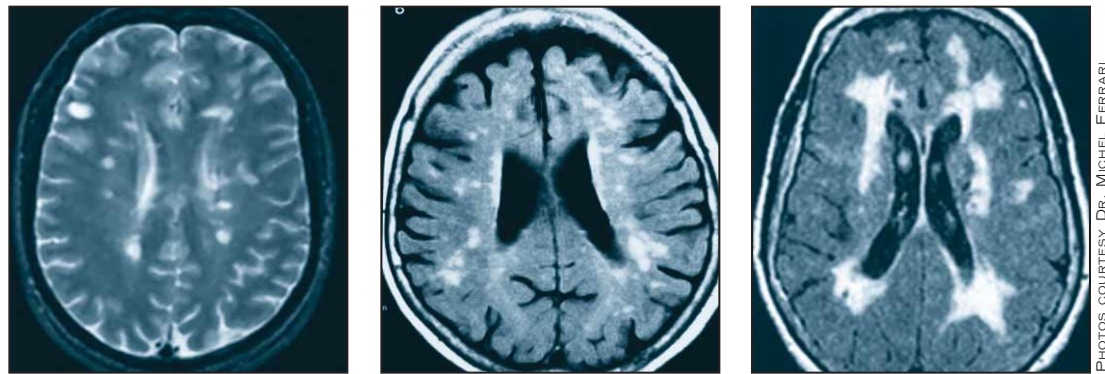
The presence of these lesions in migraine patients also raises controversial issues regarding the development of chronic migraine and potential prophylactic treatment, said Michel Ferrari, M.D., who discussed these issues in a presentation at the annual meeting of the American Headache Society.

In the CAMERA study, Dr. Ferrari, a neurologist at Leiden University Medical

Center (LUMC) in the Netherlands, and his colleagues there and at the National Institutes of Health used MRI to identify brain infarcts and white matter lesions in 435 Dutch adults aged 34-63. The investigators compared the MRI images in three groups: 161 patients who had migraine with aura, 134 patients who had migraine without aura, and 140 controls without migraine.

They found a significant increase in subclinical deep white matter lesions in patients with migraine, compared with controls—most significantly, in women who had migraine with aura.

Questions raised by this study, according to Dr. Ferrari, include: Do the lesions



MRIs show (left to right) coexisting MS and migraine; migraine alone; and coexisting cerebral autosomal dominant arteriopathy with subcortical infarcts and leukoencephalopathy and migraine.

PHOTOS COURTESY DR. MICHEL FERRARI

Migraines: No Link to Lesions, Infarcts

There was no difference in the number and volume of white matter lesions or the number, location, and size of cerebral infarcts in stroke patients with a history of migraine compared to stroke patients without migraine, in an MRI study of 83 patients.

These results were reported by Hans Katzberg, M.D., of the University of Toronto, at the AHS meeting.

“We wanted to look at whether brain lesions in patients with migraine

and stroke might be different, indicating a possible link between brain changes associated with migraine and an increased risk for stroke,” Dr. Katzberg said in an interview.

The results of the study did not indicate a general association. Still, he said, “our cohort did include a subgroup of migraine patients with stroke with no other obvious etiology, and these patients will be important to study further.”

cause any functional changes in migraineurs’ brains? Are the lesions related to severity or chronification of migraines? How might this affect migraine treatment (if it is assumed there are progressive changes in the brain)? Can earlier, more aggressive migraine treatment lower the risk for lesions, thus lowering risk of the migraines becoming chronic?

As for the causes of the lesions, Dr. Ferrari mentioned multiple possibilities, including ischemia, cortical spreading depression, genetic factors, apoptosis, and, although unlikely, patent foramen ovale. Any of these could be contributing factors in causing lesions, he said, and they could also be comorbid conditions with migraines.

There is not enough evidence yet to indicate whether the migraines are causally related to the lesions or not.

Dr. Ferrari emphasized that a great deal of additional research is needed to address these issues and that no clinical recom-

mendations can be made based on the results of the CAMERA MRI study. These need confirmation first.

“We worried that publishing this study would lead physicians to make a shortcut from lesions to treatment,” Dr. Ferrari said in an interview with this newspaper. “We should not treat a picture; we should treat a patient,” he cautioned.

Still, he said, clinicians should be aware of the issues and especially of the frequent confusion, on the part of physicians who are viewing MRIs, between migraine and other conditions—mainly multiple sclerosis.

If lesions are found, clinicians need to take a very careful history to figure out the cause of the lesions before making a diagnosis, he said.

In a related study, no difference in white matter lesions and infarcts was found between stroke patients with a history of migraines and those without migraine. (See sidebar.)

New Treatment for Endometriosis Pain Has Bone-Loss Warning

BY MICHELE G. SULLIVAN
Mid-Atlantic Bureau

Subcutaneous medroxyprogesterone acetate has been approved for the treatment of endometriosis-related pelvic pain. It is the first new treatment to be approved for this indication in 15 years.

Depo subQ provera 104 (DMPA-SC), which contains 104 mg medroxyprogesterone acetate, treats endometriosis pain as effectively as leuprolide acetate, but is associated with significantly less bone loss and fewer vasomotor symptoms, according to data provided by Pfizer Inc., which manufactures the agent.

The Food and Drug Administration granted approval for the endometriosis pain indication in March. Depo subQ provera 104 received FDA approval for use as a contraceptive in December 2004.

Depo subQ provera 104 is a new formulation of medroxyprogesterone acetate, which is the active ingredient in Depo-Provera Contraceptive Injection (medroxyprogesterone acetate injectable suspension), but with 30% less hormone.

Depo subQ provera 104 is available in prefilled syringes each containing 0.65 mL (104 mg) of medroxyprogesterone acetate sterile aqueous suspension.

Administered by subcutaneous injection four times a year (every 12-14 weeks),

DMPA-SC halts menstruation, which results in thinner, more compact endometrial tissue, the company said. This in turn halts the growth of endometrial implants, relieving endometriosis-associated pain.

The package insert contains a black box warning concerning possible bone loss: Women who use DMPA-SC may lose significant bone mineral density. Bone loss is greater with increasing duration of use and may not be completely reversible.

It is unknown if use of depo subQ provera 104 during adolescence or early adulthood, a critical period of bone accretion, will reduce peak bone mass and increase the risk of osteoporotic fracture in later life. Depo subQ provera 104 should be used as a long-term birth control method (that is, longer than 2 years) only if other birth control methods are inadequate.

Pfizer’s phase III randomized controlled trial showed that DMPA-SC is associated with significantly less bone loss than leuprolide acetate for depot suspension, the only other drug approved for treatment of endometriosis-related pain.

The 18-month study included 274 women aged 18-49 years who had diagnoses of endometriosis-associated pelvic pain. They were randomized to 6 months of treatment with either DMPA-SC (104 mg every 3 months) or leuprolide (11.25

mg IM every 3 months), and 12 months of follow-up.

There were no significant differences in pain symptom reduction. Women in both groups showed some bone mineral density declines at the end of treatment, but the mean losses were significantly less for women taking DMPA-SC in both the femur (0.3% vs. 1.65%) and the spine (1.1% vs. 3.95%).

In women who had been taking DMPA-SC, bone mineral density return to pretreatment levels 12 months after discontinuing treatment. Those who had been taking leuprolide showed continued bone mineral density losses of 1.3% in the femur and 1.7% in the spine.

DMPA-SC was also associated with significantly fewer vasomotor symptoms, especially hot flashes.

It’s important to remember that the only cure for endometriosis is aggressive surgical excision, David Redwine, M.D., Endometriosis Association adviser, said in an interview. Surgery has been repeatedly shown to have a cure rate of about 60% in even resistant cases.

“Excision is the only treatment which has documentation of cure, although this information is typically withheld from patients as they consider their treatment options. The result is that patients undergo repeated rounds of medical therapies

without eradication of their disease,” Dr. Redwine said. “Depo subQ 104 adds another form of medical therapy for endometriosis to be used by physicians who cannot treat the disease effectively by surgery.”

The bone loss associated with any hormonal therapy for symptoms is worrisome, he said, especially in women who are still actively laying down bone. “I am concerned about young women being exposed to medicines that do not treat a disease and that can produce systemic side effects, the permanency of which are not fully known,” said Dr. Redwine, medical director of the endometriosis treatment program at St. Charles Medical Center in Bend, Ore.

Daniel Watts, a Pfizer spokesman, said depo subQ provera 104 will offer a much-needed alternative to women who don’t elect surgery.

“Not all patients are appropriate candidates for surgery,” Watts said in an interview. “There are also associated risks with surgery, thus making it a less attractive option for some women. Depo provera subQ is a valuable option, because it has significantly less decline in bone mineral density and lower incidence and severity of menopausal symptoms, such as hot flashes, compared with leuprolide acetate, the commonly used treatment.”